

Class \_\_\_\_\_

Book \_\_\_\_\_


COPYRIGHT DEPOSIT
















# ATLAS AND EPITOME

OF

# GYNECOLOGY

BY

DR. OSKAR SCHAEFFER

Privatdocent of Obstetrics and Gynecology in the University  
of Heidelberg

AUTHORIZED TRANSLATION FROM THE SECOND  
REVISED AND ENLARGED GERMAN EDITION

EDITED BY

RICHARD C. NORRIS, A.M., M.D.

Surgeon-in-charge, Preston Retreat, Philadelphia; Gynecologist to the Methodist  
Episcopal Hospital and to the Philadelphia Hospital; Consulting Gynecologist  
to the Southeastern Dispensary and Hospital for Women and  
Children; Lecturer on Clinical and Operative Obstetrics,  
Medical Department, University of Pennsylvania.

WITH 207 COLORED ILLUSTRATIONS ON 90 PLATES,  
AND 62 ILLUSTRATIONS IN THE TEXT

PHILADELPHIA

W. B. SAUNDERS & COMPANY

1900

18524

RG 101

53

Library of Congress  
TWO COPIES RECEIVED  
JUL 12 1900  
Copyright entry  
*June 14, 1900*  
No. *A. 14779*  
SECOND COPY.  
Delivered to  
ORDER DIVISION,  
JUL 13 1900

COPYRIGHT, 1900, BY W. B. SAUNDERS & COMPANY.

71043



## EDITOR'S PREFACE.

---

THE value of this Atlas to the medical student and to the general practitioner will be found not only in the concise explanatory text, but especially in the illustrations. It occupies a position midway between the quiz compend and the more pretentious works on gynecology. The large number of illustrations and colored plates, reproducing the appearance of fresh specimens, will give the student an accurate mental picture and a knowledge of the pathologic changes induced by disease of the pelvic organs that can not be obtained from mere description. Next to the study of specimens, which for evident reasons are not available outside of large clinics, well-chosen illustrations must be utilized. The Atlas serves that purpose so well that its translation and publication for the English-speaking profession seemed very desirable.

The translator, Dr. W. Hersey Thomas, has carefully followed the author's text, which, while concise, covers the subject systematically, and with sufficient detail to give the reader a comprehensive knowledge of gynecologic disorders. The paragraphs devoted to the treatment of the various diseases are very conservative, in some instances perhaps too much so for the aggressive surgeon. The author's conservatism will be appreciated, however, by the student and the practitioner, who necessarily wish to be informed on nonoperative gynecology.

Editorial comments have occasionally been inserted, in order to harmonize or point out the difference between the author's teaching and that generally approved in America.

## PREFACE TO THE SECOND EDITION.

---

EVERY one concerned in the production of the second edition of this volume has helped to make it represent all the advances in our technical knowledge. A statement of the latest scientific acquisitions has been incorporated into the original text. The greatest stress has been laid upon the accumulation of new illustrative material from autopsies and operations as well as from the living. The delineations of the artist, Mr. A. Schmitson, are meritorious and true to nature. The new material has been obtained partly from the Heidelberg Pathologic Institute, partly from our surgical and gynecologic clinics, and partly from my private practice. I take this opportunity to express my heartiest thanks to the Directors of the Institute, to Professors Arnold, Czerny, Kehrer, and their assistants, and especially to Professors Ernst and Jordan for the use of their instructive fresh specimens.

The publisher has spared neither trouble nor expense in the reproduction of the water-colors, which are abundant and as true to nature as possible.

O. SCHAEFFER.

## PREFACE TO THE FIRST EDITION.

---

IN spite of the existence of excellent shorter works and compends, as well as of good comprehensive atlases, the author feels that there is need of a book that will give the student and the practitioner an opportunity to elucidate and to complete his necessarily limited personal observations and examinations in the clinic and dispensary. If the entire work were carried out upon a purely diagrammatic basis, it would probably be more readily grasped by the majority of readers ; not every one, however, possesses the gift of translating such pictured relations into living clinical entities. On the other hand, the strict reproduction of anatomic preparations renders difficult that clear representation which is necessary to sift the essential from the nonessential facts.

I have consequently decided, in many cases, to combine both methods of illustration—that is, to reproduce accurate anatomic specimens, and then to emphasize more sharply the changes under consideration. I have further endeavored to show every subject from as many stand-points as possible (that is, regarding their etiology, development, secondary influence, progress, and termination), and consequently have further elucidated the pictures of specimens by diagrammatic and semidiagrammatic drawings.

Thanks to my former assistantship at the Munich Frauenklinik, and in no slight degree to the indulgent permission and stimulating counsel of Professor v. Winckel, I have been able to employ, almost without exception, original anatomic and clinical material. I wish to take this opportunity to express my thanks to this

gentleman, and also to Professor Kehrer, who most amiably allowed me to use his clinical material.

The text has been divided into two parts. The continuous text is, without exception, written from a practical standpoint; the text of the plates, on the contrary, contains the purely theoretic, scientific, anatomic, microscopic, and chemic notes, and facts of general significance (concerning sounds, pessaries, etc.), so that in referring to the work the one text will not have a disturbing influence upon the other.

To avoid needless repetition, frequent references have been made to my "Atlas of Obstetric Diagnosis and Treatment." The necessity for this will be readily understood when we consider the identity of the anatomic data and the intimate mutual relations existing between the child-bearing process and the majority of gynecologic affections.

The material has been classified from an etiologic standpoint as far as possible; to carry this out rigidly, however, would have led to diffuseness. The chapters upon sepsis, gonorrhea, genital tuberculosis, and venereal diseases are based upon this classification. Cystitis, which comes within the domain of the gynecologist so frequently, has received special attention.

Particular effort has been directed to the clear presentation of the subject of differential diagnosis. The methods which I have chosen are the comparative and the tabular. The subject receives full attention in the chapters on Myomata, Cystomata, Carcinoma, Tumors of the Ante-uterine and Retro-uterine Spaces, and others.

At the conclusion of the work I have placed a Therapeutic Table of the ordinary remedies used in gynecology, and have indicated the appropriate methods of prescribing them—chiefly as intra-uterine pencils, vaginal and rectal suppositories, baths, and injections.

O. SCHAEFFER.

HEIDELBERG, November, 1895.

# CONTENTS.

---

## Group I.—Anomalies of Formation and Arrested Development.

### CHAPTER I.

|   | PAGE |
|---|------|
| FETAL ANOMALIES OF FORMATION. . . . .                                     | 17   |
| § 1. Aplasia and Hypoplasia of the Fetal Rudiments . . .                  | 17   |
| § 2. Hyperplastic Anomalies of Formation of the Fetal Rudiments . . . . . | 29   |

### CHAPTER II.

|  |    |
|--|----|
| ARRESTED DEVELOPMENT AND ANOMALIES OF INFANCY AND PUBERTY. . . . . | 35 |
| § 3. Infantile Anomalies of Formation . . . . .                    | 35 |
| § 4. Anomalies of Menstruation . . . . .                           | 38 |
| § 5. Sterility . . . . .   | 46 |

## Group II.—Changes of Shape and Position.

### CHAPTER I.

|   |    |
|---|----|
| HERNIA . . . . .  | 48 |
| § 6. Hernia and Other Changes of Shape of the Vulva . . | 48 |

### CHAPTER II.

|  |    |
|--|----|
| INVERSION AND PROLAPSUS . . . . .                        | 50 |
| § 7. Inversions of the Vagina and Uterus . . . . .       | 50 |
| § 8. Prolapse of the Vagina and Uterus.—Elevatio Uteri . | 57 |
| The Normal Situation and Position of the Uterus . .      | 57 |

### CHAPTER III.

|   |    |
|---|----|
| PATHOLOGIC POSITIONS, VERSIONS, AND FLEXIONS OF THE UTERUS. . . . . | 73 |
| § 9. Pathologic Positions of the Uterus and Its Adnexa . .          | 73 |
| § 10. Anteversions and Anteflexions of the Uterus . . . .           | 76 |
| § 11. Retroversions and Retroflexions of the Uterus . . . .         | 79 |
| Directions for the Application of Pessaries . . . . .               | 84 |

**Group III.—Inflammatory and Nutritional Disturbances.**

## CHAPTER I.

PAGE

|  |     |
|--|-----|
| INFLAMMATION AND ITS CONSEQUENCES : ACQUIRED STENOSSES<br>AND ATRESIAS, CONTRACTION OF ORGANS, EXUDATIONS, AND<br>ADHESIONS . . . . .          | 92  |
| § 12. Gonorrhea . . . . .  | 93  |
| § 13. Chronic Endometritis. Erosion and Ectropion of the<br>External Os . . . . .  | 100 |
| Catarrh of the Cervix and Chronic Cervicitis and Their<br>Consequences : Erosion and Ectropion . . . . .                                       | 101 |
| Endometritis Corporis Uteri . . . . .  | 107 |
| § 14. Chronic Metritis . . . . .   | 111 |
| § 15. Sepsis (Acute Vulvitis, Vaginitis, Endometritis, Myo-<br>metritis, Salpingitis, Parametritis and Perimetritis,<br>Peritonitis) . . . . . | 117 |
| § 16. Chronic Salpingitis . . . . .  | 124 |
| § 17. Chronic Oophoritis . . . . .   | 126 |
| § 18. Chronic Perimetritis, Oophoritis, and Salpingitis.<br>Chronic Pelvic Peritonitis . . . . .   | 131 |
| § 19. Chronic Parametritis and Paracolpitis . . . . .  | 134 |
| § 20. Genital Tuberculosis . . . . .   | 136 |
| § 21. Venereal Diseases . . . . .  | 139 |
| § 22. Catarrh of the Bladder and Cystitis . . . . .  | 140 |

## CHAPTER II.

|   |     |
|---|-----|
| § 23. Disturbances of Nutrition and Circulation. Neuroses | 149 |
|---|-----|

**Group IV.—Injuries and Their Consequences.**

## CHAPTER I.

|  |     |
|--|-----|
| DEFECTS WITH CICATRICIAL CHANGES . . . . .   | 155 |
| § 24. Injuries of the Vulva (Including Fissures) and Perineal<br>Defects, Incontinentia Vulvae . . . . . | 155 |
| § 25. Lacerations of the Vagina and Cervix . . . . .   | 160 |
| § 26. Traumatic Stenoses and Atresias of the Vulva, of the<br>Vagina, and of the Uterus . . . . .        | 162 |

## CHAPTER II.

|   |     |
|---|-----|
| FISTULAS . . . . .                          | 165 |
| § 27. Classification of Fistulas . . . . .  | 165 |
| A. Fistulas of the Urinary Organs . . . . . | 165 |
| B. Intestinal Fistulas . . . . .            | 168 |

## CHAPTER III.

|   |     |
|---|-----|
| TRAUMATIC EFFUSIONS OF BLOOD . . . . .                      | 175 |
| § 28. Hematoma : (a) Vulvar ; (b) Extraperitoneal . . . . . | 175 |
| § 29. Intraperitoneal Retro-uterine Hematocele . . . . .    | 176 |



## CHAPTER IV.

PAGE

|   |     |
|---|-----|
| FOREIGN BODIES IN THE GENITAL CANAL AND IN THE<br>BLADDER . . . . . | 180 |
| § 30. Foreign Bodies (Including Vesical Calculi) . . . . .          | 180 |

## Group V.—New Growths.

## CHAPTER I.

|   |     |
|---|-----|
| BENIGN TUMORS . . . . .   | 186 |
| § 31. Benign Tumors of the Mucous Membranes Covered<br>with Squamous Epithelium . . . . . | 186 |
| § 32. Benign Tumors of the Uterus. . . . .  | 189 |
| § 33. Benign Tumors of the Uterine Adnexa . . . . .                                       | 199 |

## CHAPTER II.

|  |     |
|--|-----|
| TUMORS OF BENIGN STRUCTURE THAT MAY BECOME DAN-<br>GEROUS UNDER CERTAIN CONDITIONS . . . . . | 202 |
| § 34. Fibromyomata . . . . .   | 202 |
| § 35. Ovarian Cystomata . . . . .  | 211 |

## CHAPTER III.

|  |     |
|--|-----|
| MALIGNANT TUMORS . . . . .   | 234 |
| § 36. Malignant Tumors of the Vulva, Bladder, and Vagina . . . . .           | 234 |
| § 37. Malignant Tumors of the Uterus . . . . .                               | 237 |
| § 38. Malignant Tumors of the Adnexa, Especially of the<br>Ovaries . . . . . | 245 |
| I. Carcinoma . . . . .   | 245 |
| II. Sarcoma . . . . .  | 247 |
| THERAPEUTIC TABLE . . . . .  | 249 |
| INDEX . . . . .  | 263 |





## LIST OF PLATES.

---

|   | PAGE. |
|---|-------|
| Plate 1.—The Vulva of a Nonpregnant Multipara. Anomaly of the Hymen . . . . .   | 32    |
| Plate 2.—Fig. 1.—Intravaginal Cervix of an "Infantile" Uterus . . . . .   | 32    |
| Fig. 2.—Duplication of Cervix in a Case of Uterus Bicornis Septus with a Single Vagina.   |       |
| Plate 3.—Fig. 1.—Impressio Fundi Uteri . . . . .  | 54    |
| Fig. 2.—Partial Inversion of the Uterus.  |       |
| Fig. 3.—Complete Inversion of the Uterus.   |       |
| Fig. 4.—Complete Inversion and Prolapse of the Uterus.  |       |
| Fig. 5.—Complete Prolapse of the Retroflexed Uterus and of the Vagina, with Laceration of the Perineum ; Cystocele.                             |       |
| Plate 4.—Fig. 1.—Incomplete Prolapse of a Retroverted Uterus; Marked Rectocele ; Vaginal Inversion . .  | 58    |
| Fig. 2.—Incomplete Prolapse of the Uterus, Due to Hypertrophy of the Intermediate Portion of the Neck ; Inversion of the Vagina with Cystocele. |       |
| Fig. 3.—Total Prolapse of Anteflexed Uterus and of the Anterior Vaginal Wall, with Cystocele ; Characteristic Flexion of the Urethra.           |       |
| Fig. 4.—Complete Prolapse of Retroflexed Uterus (First Degree) and of Vagina.   |       |
| Plate 5.—Fig. 1.—Prolapse of Posterior Vaginal Wall ; Rectocele ; Descent of Retroflexed Uterus (Second Degree) . . . . .                       | 58    |
| Fig. 2.—Prolapse of Anterior Vaginal Wall ; Extreme Grade of Cystocele ; Anteflexion of the Uterus (First Degree) ; Descent of the Uterus.      |       |
| Fig. 3.—Reposition of Prolapsed Uterus by a Martin Stem-pessary.  |       |
| Fig. 4.—Hypertrophy of the Anterior Lip of the Uterus, Producing Inversion of the Anterior Vaginal Wall and Cystocele.                          |       |
| Plate 6.—Inversion of the Posterior Vaginal Wall. Leukorrhea.   | 62    |

|   | PAGE. |
|---|-------|
| Plate 7.—Fig. 1.—Inversion of the Vagina from a Perineal Tear of the Third Degree . . . . .   | 64    |
| Fig. 2.—View of the Cervix in a Case of Elevation of the Uterus.  |       |
| Plate 8.—Complete Prolapse of an Anteфлекed Uterus ; Cystocele . . . . .  | 68    |
| Plate 9.—Extreme Inversion of the Vagina, with Cystocele and Incomplete Prolapse of the Retroverted Uterus . .  | 70    |
| Plate 10.—Incomplete Prolapse of the Uterus ; Simple Erosion ; “Circular” Thickening of Cervix ; Rectocele . . .  | 70    |
| Plate 11.—Anteflexion of the Uterus in a Child . . . . .  | 72    |
| Plate 12.—Incomplete Prolapse of the Uterus ; Elongation of the Intermediate Portion of the Neck, with “Circular” Hypertrophy of the Vaginal Portion ; Inversion of the Anterior Vaginal Wall ; Cystocele . . . . . | 74    |
| Plate 13.—Artificial Prolapse for Operative Purposes, with the Arising Inversion of the Vagina and with Cystocele   | 74    |
| Plate 14.—Fig. 1.—Normal Anteversion of the Uterus . . . .  | 78    |
| Fig. 2.—Pathologic Anteversion of the Uterus.   |       |
| Fig. 3.—Myoma of the Anterior Uterine Wall, Simulating an Anteфлекion of the Second or Third Degree.  |       |
| Fig. 4.—Anteversion of a Fixed Uterus (at the Same Time Retroposition from a Full Bladder).   |       |
| Plate 15.—Fig. 1.—Anteflexion of the Uterus of the Second Degree from Posterior Perimetritic Adhesions. . . . .   | 80    |
| Fig. 2.—Anteflexion of the Uterus of the First Degree with the Neck Lying Horizontally.   |       |
| Fig. 3.—Anteflexion of the Infantile Uterus with Stenosis of the Cervix and Internal Os ; Dysmenorrhea.   |       |
| Fig. 4.—Anteflexion of the Uterus of the Third Degree from a Submucous Uterine Polyp.   |       |
| Plate 16.—Fig. 1.—Retroversion of a Fixed Uterus . . . . .  | 80    |
| Fig. 2.—Retroflexion of a Fixed Uterus (First Degree).  |       |
| Fig. 3.—Slight Retroflexion and Descent of the Puerperal Uterus from Relaxation of the Genitalia.   |       |
| Fig. 4.—Retroversion of the Uterus (Third Degree) from Pressure of an Ovarian Cyst.   |       |
| Plate 17.—Fig. 1.—Encapsulated Peritoneal Exudate in Douglas’ Pouch. Descent and Anterior Position of a Fixed Uterus . . . . .  | 82    |
| Fig. 2.—Retroposition of the Uterus by a Full Bladder.  |       |
| Fig. 3.—Descent and Retroflexion of the Uterus of the First Degree, Brought About by Relaxation of the Folds of Douglas.  |       |

|  | PAGE. |
|--|-------|
| Plate 17.—Fig. 4.—Retroflexion of the Uterus of the First Degree . . . . .   | 82    |
| Plate 18.—Fig. 1.—Retroversion of the Uterus from Two Intramural Myomata . . . . .   | 86    |
| Fig. 2.—Transition from Retroversion to Retroflexion of the Uterus from an Intramural Myoma of the Anterior Wall.                |       |
| Fig. 3.—Retroflexion of the Uterus of the Third Degree.  |       |
| Fig. 4.—Inveterate Retroflexion of the Uterus of the Third Degree.   |       |
| Plate 19.—Fig. 1.—Retroversion of the Uterus ; Vaginal Ovariocele . . . . .  | 86    |
| Fig. 2.—Bimanual Examination from the Rectum of a Case of Cord-like Total Atresia of the Vagina with a Rudimentary Solid Uterus. |       |
| Plate 20.—Fig. 1.—Reposition of a Retroverted Uterus by Means of Küstner's Bullet-forceps . . . . .                              | 88    |
| Fig. 2.—Reposition of a Retroverted Uterus by Means of the Sound.  |       |
| Fig. 3.—Introduction of the Elastic Ring of Mayer by Means of Fritsch's Forceps.   |       |
| Fig. 4.—Introduction of Hodge's Pessary.   |       |
| Plates 21 and 22.—Manual Reposition of a Retroflexed Uterus . . . . .  | 90    |
| Plate 23.—Massage (Thure Brandt) . . . . .   | 90    |
| Plate 24.—Fig. 1.—Gonorrheal Papilloma of the Cervix (Mracek) . . . . .  | 94    |
| Fig. 2.—Gonorrheal Cervicitis.   |       |
| Fig. 3.—Gonococci and Pus-corpuscles.  |       |
| Plate 25.—Bartholinitis Dextra Gonorrhœica. Perforation of the Abscess ; Urethritis . . . . .                                    | 96    |
| Plate 26.—Bartholinitis Sinistra Gonorrhœica. Abscess Formation (Mracek) . . . . .   | 96    |
| Plate 27.—Gonorrheal Vulvitis and Vaginitis . . . . .  | 98    |
| Plate 28.—Fig. 1.—The Microscopic Structure of the Parts of the Vulva . . . . .  | 98    |
| Fig. 2.—Longitudinal Section Through the Cervix in a Case of Old Prolapse of the Uterus.   |       |
| Fig. 3.—Simple, Papillary, and Follicular Erosion of the Cervix.   |       |
| Plate 29.—Fig. 1.—Elephantiasis Vulvæ . . . . .  | 100   |
| Fig. 2.—Condyloma Acuminatum.  |       |
| Fig. 3.—Vaginal Secretion.   |       |
| Fig. 4.—Cross-section of an Ovule of Naboth.   |       |
| Plate 30.—Fig. 1.—Normal Uterine Mucosa . . . . .  | 102   |
| Fig. 2.—Hyperplastic Glandular Endometritis.   |       |
| Fig. 3.—Malignant Adenoma (Glandular Cancer).  |       |
| Fig. 4.—Hypertrophic Glandular and Interstitial Endometritis.  |       |
| Plate 31.—Fig. 1.—Acute Interstitial Endometritis . . . . .  | 104   |

|  | PAGE. |
|--|-------|
| Plate 31.—Fig. 2.—Chronic Interstitial Endometritis . . . . .  | 104   |
| Fig. 3.—Postabortive Endometritis.   |       |
| Plate 32.—Fig. 1.—Marked Congestion and Beginning Simple Erosion of the Posterior Lip of the Os, as a Sign of Uterine Inflammation; Endometritis and Metritis . . . . .                  | 106   |
| Fig. 2.—Slight Congestion of the Cervix of a Multipara with a Characteristic, Broad, Fissured External Orifice.  |       |
| Plate 33.—Fig. 1.—Congenital Simple Erosion of the Cervix of a Virgin . . . . .  | 106   |
| Fig. 2.—Leukorrhea and Simple Erosion.   |       |
| Plate 34.—Ectropion, with Extreme Relaxation of the Cervical Wall and Intact Commissures of the External Os . . . . .  | 108   |
| Plate 35.—Mucous Polyp and Ectropion of the Anterior Lip of the Uterus . . . . .   | 108   |
| Plate 36.—Fig. 1.—Different Molds of the Uterocervical Canal as Shown by Swollen Laminaria . . . . .   | 110   |
| Fig. 2.—Curetment in Fungous Endometritis.   |       |
| Plate 37.—Fig. 1.—Chronic Metritis with Ovula Nabothi . . . . .  | 112   |
| Fig. 2.—Gonorrheal Endometritis with Simple Erosion and Ovules of Naboth ; Inflammatory Hyperemia.   |       |
| Plate 38.—Retroversion of the Fixed Uterus (First Degree) and Agglutination of the Cervix (Acquired) . . . . .   | 112   |
| Plate 39.—Acute Purulent Pelvic Peritonitis (Peritonitis of Perforation) . . . . .   | 114   |
| Plate 40.—Fig. 1.—Acute Catarrhal Parenchymatous Salpingitis (Due to Gonococci and Streptococci) . . . . .   | 118   |
| Fig. 2.—Hematosalpinx.   |       |
| Fig. 3.—Pyosalpinx.  |       |
| Plate 41.—Fig. 1.—Acute Purulent Parenchymatous and Interstitial Salpingitis . . . . .   | 122   |
| Fig. 2.—Parametritis Acuta of the Broad Ligament.  |       |
| Fig. 3.—Chronic Oophoritis with Oligocystic Degeneration.  |       |
| Plate 42.—Double Pyohydrosalpinx, Chronic Adhesive Perimetritis and Oophoritis . . . . .   | 124   |
| Plate 43.—Chronic Adhesive Perimetritis and Salpingitis with Uterine Myomata . . . . .   | 126   |
| Plate 44.—Pelvic Peritonitis, Peri-oophoritis, Perisalpingitis, and Right-sided Pyosalpinx . . . . .   | 128   |
| Plate 45.—Fig. 1.—Pelvic Peritonitis . . . . .   | 130   |
| Fig. 2.—Left-sided Dermoid Cyst Perforating into the Rectum.   |       |
| Plate 46.—Genital Tuberculosis of Both Tubes, of Both Ovaries, and of the Pouch of Douglas . . . . .   | 132   |
| Plate 47.—Cystitis; Ureteritis (Pyonephrosis) as a Result of Lithiasis; Metritis with Endometritis Fungosa; Cervicitis with Marked Dilatation of the Cervical Canal; Vaginitis . . . . . | 134   |

|  | PAGE. |
|--|-------|
| Plate 48.—Chronic Cystitis with Acute Exacerbations . . . . .  | 136   |
| Plate 49.—Fig. 1.—Syphilitic Ulcer of the Vaginal Cervix.<br>(Mraček.) . . . . .   | 138   |
| Fig. 2.—Syphilitic Ulcers of the Vaginal Mucosa.<br>(Mraček.) . . . . .  |       |
| Plate 50.—Papular Gummata of the Vulva, of the Anus, and of<br>the Inner Side of the Thigh. (Mraček.) . . . . .  | 140   |
| Plate 51.—Fig. 1.—Elephantiasis Vulvæ Originating in the La-<br>bium Majus Dextrum and Polypoid Ex-<br>crescences of the Mucous Membrane at the<br>Urethral Orifice . . . . .        | 152   |
| Fig. 2.—Phlebectasia of the Labia Majora, of the Cli-<br>toris, and of the Nymphæ; the Right<br>Labium Majus Contains a Hematoma<br>(Thrombus Vulvæ); and Hemorrhoids.               |       |
| Plate 52.—Edema of the Nymphæ from a Moribund Patient with<br>a Cardiac Lesion . . . . .   | 154   |
| Plate 53.—Phlebectasia with Phleboliths of the Ligmenta Lata<br>Corresponding to the Ovarian Vessels and the Pam-<br>piniform Plexus . . . . .                                       | 156   |
| Plate 54.—Fig. 1.—The Normal Perineum . . . . .  | 158   |
| Fig. 2.—Perineal Laceration of the Third Degree<br>(into the Rectum).  |       |
| Fig. 3.—Perineal Laceration of the Second Degree.  |       |
| Fig. 4.—Perineal Laceration of the Third Degree.   |       |
| Plate 55.—Fig. 1.—Torsion of the Cervix Produced by Scar Tis-<br>sue . . . . .   | 162   |
| Fig. 2.—Star-shaped Laceration of the External Os.   |       |
| Plate 56.—Fig. 1.—Laceration of the Left Commissure of the Os<br>Uteri, with Marked Ectropion and Ovules<br>of Naboth on the Projecting Hyper-<br>trophied Cervical Mucosa . . . . . | 162   |
| Fig. 2.—Old Ectropion and Congestion of the Cervix.  |       |
| Plate 57.—Recto-uterine Hematocele in Combination with an<br>Extra-uterine Gestation Sac . . . . .   | 174   |
| Plate 58.—Fig. 1.—Free Ascites in the Upright Position . . . . .   | 178   |
| Fig. 2.—Intraperitoneal Retro-uterine Hematocele.  |       |
| Fig. 3.—Extraperitoneal Retro-uterine Hematoma.  |       |
| Fig. 4.—Large Subserous Posterior Myoma of the<br>Uterus Simulating a Retroflexion.  |       |
| Plate 59.—Fig. 1.—Left-sided and Posterior Parametritis . . . . .  | 182   |
| Fig. 2.—Intraligamentous and Retroperitoneal Mul-<br>tilocular Glandular Mucoid Cyst of the<br>Left Ovary.   |       |
| Fig. 3.—Left-sided Pyosalpinx.   |       |
| Fig. 4.—Carcinomatous Cystadenoma of the Ovary.<br>(Diagrammatic.)   |       |
| Plate 60.—Fig. 1.—Polyps of the Uterine Mucous Membrane . . . . .  | 188   |
| Fig. 2.—Simple Erosion with Ovules of Naboth.  |       |
| Plate 61.—Fig. 1.—Subserous Polypoid Fibromyoma of the<br>Uterus . . . . .   | 188   |



|   | PAGE. |
|---|-------|
| Plate 61.—Fig. 2.—Myomatosis Uteri . . . . .  | 188   |
| Plate 62.—Several Polypoid Myomata of the Fundus, which Produced Uncontrollable Hemorrhage at the Time of the Menopause . . . . .                       | 190   |
| Plate 63.—Intraperitoneal Surface of an Amputated Myomatous Uterus (Submucous Myoma) . . . . .  | 192   |
| Plate 64.—Several Bleeding Myomatous Polyps of the Fundus . . . . .   | 194   |
| Plate 65.—Completely Extirpated Myomatous Uterus . . . . .  | 194   |
| Plate 66.—Inner Surface of a Uterus with an Incised Intramural Submucous Hemorrhagic Myoma of the Posterior Wall . . . . .                              | 196   |
| Plate 67.—Polypoid Subserous Fibromyoma; Polyps of the Mucous Membrane in the Dilated Cervical Canal . . . . .  | 204   |
| Plate 68.—Fig. 1.—Unilocular Ovarian Cysts . . . . .  | 210   |
| Fig. 2.—Thin-walled Multilocular Glandular Mucoid Cyst.   |       |
| Plate 69.—Multilocular Glandular Mucoid Cyst . . . . .  | 212   |
| Plate 70.—Multilocular Glandular Mucoid Cyst . . . . .  | 214   |
| Plate 71.—Fig. 1.—Histologic Structure of a Uterine Mucous Polyp . . . . .  | 214   |
| Fig. 2.—Microscopic Section through the Transition Zone of a Minute Myoma that is Becoming Encapsulated into the Surrounding Normal Uterine Muscularis. |       |
| Fig. 3.—Vaginitis (Colpitis).   |       |
| Plate 72.—Fig. 1.—Primary Formation of Cysts from a Multilocular Glandular Mucoid Cyst of the Ovary . . . . .   | 220   |
| Fig. 2.—Papillary Proliferating Cyst of the Ovary.  |       |
| Fig. 3.—Necrotic Cyst-wall.   |       |
| Fig. 4.—Sediment from the Fluid of an Ovarian Cyst.   |       |
| Plate 73.—Fig. 1.—Myxosarcoma of the Uterus . . . . .   | 222   |
| Fig. 2.—Spindle-cell Sarcoma of the Uterus.   |       |
| Fig. 3.—Malignant Adenoma Growing through a Cyst-wall. (Semi-diagrammatic.)   |       |
| Fig. 4.—Angioma of the Urethra.   |       |
| Plate 74.—Figs. 1 and 2.—Bimanual Examination of a Pyosalpinx with a Full and with an Empty Rectum . . . . .  | 226   |
| Fig. 3.—Bimanual Examination, with Assistance, of the Pedicle of an Ovarian Cyst.   |       |
| Plate 75.—Figs. 1 and 2.—Two Different Cut Surfaces of a Sarcoma of the Ovary . . . . .   | 228   |
| Plate 76.—Fig. 1.—Sarcoma of the Ovary . . . . .  | 228   |
| Fig. 2.—A Case of Commencing Sarcomatous Degeneration of the Ovary.   |       |
| Plates 77 and 78.—Multiple Extraperitoneal Extravasations of Blood, Especially in the Great Omentum . . . . .   | 230   |
| Plate 79. Fig. 1.—Epithelioma of the Vulva . . . . .  | 232   |

|   | PAGE. |
|---|-------|
| Plate 79.—Fig. 2.—Part of an Epitheliomatous Papilloma of the Vaginal Cervix . . . . .                                      | 232   |
| Fig. 3.—Epitheliomatous " Pearls " from an Ulcer of the Cervix.   |       |
| Fig. 4.—Dermoid Cyst.   |       |
| Plate 80.—Fig. 1.—Ulcerated Epithelioma of the Left Labium Majus . . . . .  | 236   |
| Fig. 2.—Flat Ulcerating Epithelioma of the Posterior Lip of the Os Uteri and of the Posterior Vaginal Vault.                |       |
| Plate 81.—Fig. 1.—Nodular Epithelioma of the Vaginal Cervix.  |       |
| Fig. 2.—Epitheliomatous Papilloma of the Anterior Lip of the Os Uteri . . . . .   | 236   |
| Plate 82.—A View of an Epitheliomatous Ulceration of the Mucous Membrane of the Cervical Canal . . . . .                    | 238   |
| Plate 83.—Figs. 1 and 2.—Epitheliomatous Ulcer of the Cervix.   | 240   |
| Plate 84.—Fig. 1.—Epitheliomatous Papilloma of the Anterior Lip of the Os Uteri and of the Anterior Vaginal Vault . . . . . | 240   |
| Fig. 2.—Beginning Epithelioma of the Cervix.  |       |
| Plate 85.—Fig. 1.—Epitheliomatous Papilloma of Both Lips of the Os . . . . .  | 242   |
| Fig. 2.—Epitheliomatous Ulcer of the Cervix.  |       |
| Plate 86.—Fig. 1.—Epithelioma of the Cervix that has Perforated into the Bladder . . . . .                                  | 242   |
| Fig. 2.—Perforation of an Epithelioma of the Cervix into the Bladder and Rectum.  |       |
| Plate 87.—Fig. 1.—Carcinoma of the Uterine Body . . . . .   | 244   |
| Fig. 2.—Sarcoma of the Uterus.  |       |
| Plate 88.—Fig. 1.—Flat Cervical Epithelioma of Both Lips of the Os Uteri Involving Both Vaginal Vaults . . . . .            | 244   |
| Fig. 2.—Epitheliomatous Papilloma of Both Lips of the Os Uteri.   |       |
| Fig. 3.—Polypoid Epitheliomatous Papilloma of the Anterior Lip of the Os Uteri.   |       |
| Fig. 4.—Epitheliomatous Papilloma of the Posterior Lip of the Os Uteri Filling the Entire Posterior Vaginal Vault.          |       |
| Fig. 5.—Villous Cancer of the Bladder in Its Most Frequent Position.  |       |
| Fig. 6.—Rectal Carcinoma (Glandular Cancer) Infiltrating the Rectovaginal Septum.   |       |
| Plate 89.—Fig. 1.—Cancer Nodules in the Cervix, Which Has Not Yet Ulcerated . . . . .                                       | 246   |
| Fig. 2.—Epitheliomatous Ulcer of the Cervix.  |       |
| Fig. 3.—Epitheliomatous Ulcer of the Cervix Which Has Invaded the Uterine Body.   |       |
| Fig. 4.—Carcinoma of the Body of the Uterus Which Has Perforated into the Bladder   |       |

|  | PAGE. |
|--|-------|
| Plate 89.—Fig. 5.—Epitheliomatous Ulcer of the Cervix Which<br>Has Perforated into the Bladder . . . . | 246   |
| Fig. 6.—Epitheliomatous Ulcer of the Cervix Per-<br>forating into Both Bladder and Rectum.             |       |
| Plate 90.—Fig. 1.—Fungous Endometritis and Ectropion . .   | 246   |
| Fig. 2.—Epitheliomatous Papilloma of Both Lips of<br>the Os.   |       |
| Fig. 3.—Ovules of Naboth in a Mucous Polyp Visible<br>at the Os Uteri.                                 |       |
| Fig. 4 —Fibroid Polyp Separating the Lips of the Os<br>Uteri.  |       |







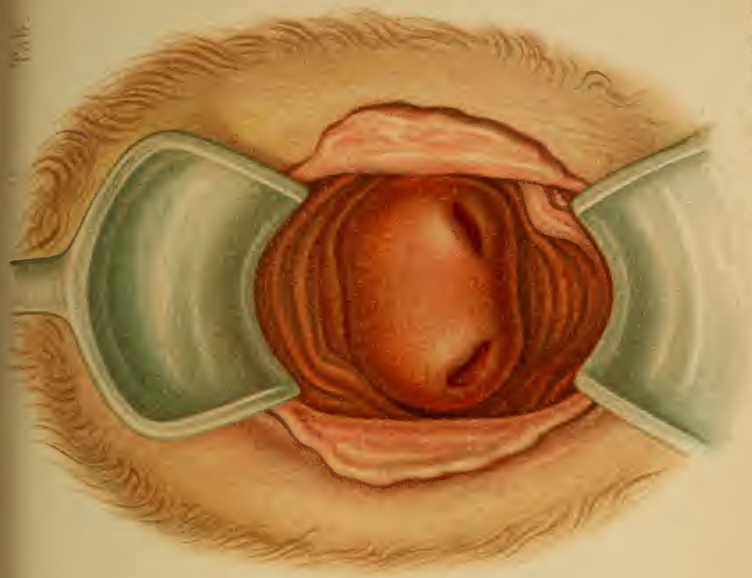


Fig. 2. *18th. Anst. F. Reinhardt, München.*

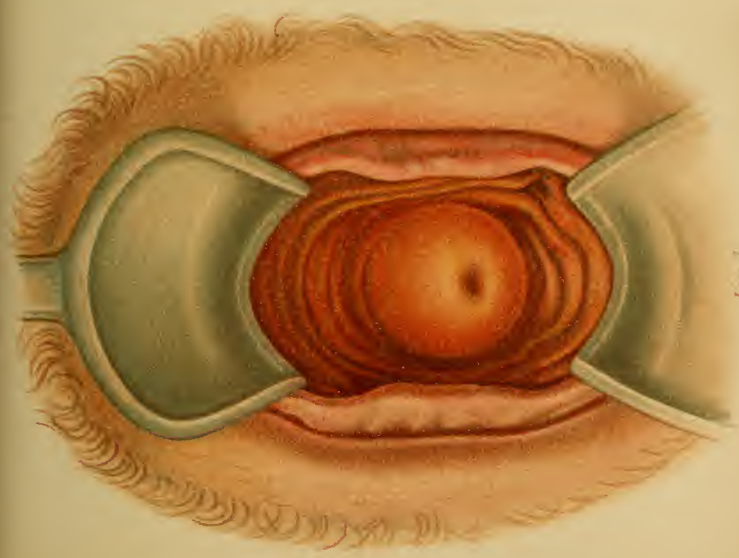



Fig. 1.



explains the association of all degrees of the bicornate uterus with septa of varying extent in the uterus or vagina. We may thus have a uterus bicornis septus or bicornis, and subseptus or unicollis, or, again, both may be combined with vagina septa or subsepta. (Plate 2, Fig. 2, and Figs. 20 and 21.) One duct may be occluded, as has been already mentioned, producing a unilateral atresia. A hymen septus or bifenestratus may be present, and, by

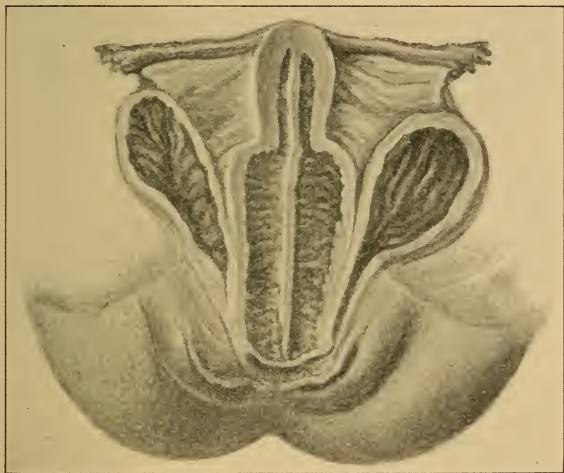

Fig. 21.—Uterus et vagina septa (Munich Frauenklinik).

reason of its resisting power, may play quite an important rôle in the pathology of the sexual life. (Fig. 2.)

**Symptomatology.**—The influence of these malformations upon labor has been described in my “Atlas of Obstetric Diagnosis and Treatment.”

Conception frequently does not occur in consequence of the feeble development of the entire genitalia. These individuals are usually weaklings with amenorrhea, and should be advised not to marry.

**Treatment.**—Ligation or division (Paquelin) of the septa. It is to be remembered that after castration or total extirpation of the uterus for myomata the presence of a third ovary may nullify the result, or may explain a subsequent abdominal pregnancy.

## CHAPTER II.

### ARRESTED DEVELOPMENT AND ANOMALIES OF INFANCY AND PUBERTY.

1. Uterus foetalis (often planifundalis).
2. Uterus infantilis and uterus membranaceus.
3. Ante flexio uteri infantilis.
4. Stenosis cervicis et orificii externi.
5. Stenosis vulvovaginalis or hymenalis.
6. Evolutio præcox.
7. Oligomenorrhea and amenorrhea.
8. Dysmenorrhea.
9. Menorrhagia.
10. Sterility.

#### § 3. INFANTILE ANOMALIES OF FORMATION.

1 and 2. Those formative arrests designated as **uterus foetalis** or **infantilis** are combined with functional disturbances (symptoms)—to be described under the headings from 3 to 10—and with a generally weakened constitution, idiocy, etc. In the fetal form the body of the uterus fails to grow, and the neck is relatively larger; the vaginal cervix is very small, and is provided with a minute opening. The latter is also true of the infantile uterus (Plate 2, Fig. 1), but here the body has grown until its muscular coat is as well developed as is that of the neck. The body, instead of being pear-shaped and forming the largest part of the uterus, is simply a cylindric continuation of the cervix.

The **uterus membranaceus** is due to a simple primary atrophy of the organ. (Fig. 22.) All three forms are characterized by their diminutiveness.



The **diagnosis** is made by bimanual exploration (through the rectum, if necessary) and by the cautious introduction of the uterine sound.<sup>1</sup>

**Treatment.**—Treat the anemia or tuberculosis with roborants. Increase the local blood supply by massage, warm sitz-baths, stimulating vaginal douches, the stem-pessary, frequent scarifications, and mustard plasters on the thighs during the menstrual molimina. Faradization is also employed, one pole being introduced into the uterus and the other being placed upon the mons veneris.

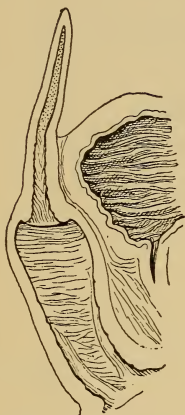


Fig. 22.—Uterus membranaceous.

**3 and 4. Infantile ante flexion** (Plate 15, Fig. 3) of a small organ is often associated with stenosis of the cervical canal or its external orifice. "Puerile ante flexion" consists in a sharp bending forward of a normal, large, flexible organ, with a shortened anterior vaginal wall, in the elongated axis of which the hypertrophic supra-vaginal cervix is found.

**Symptoms.**—Dysmenorrhea (8) and sterility. Both may be purely mechanical, from the narrowed lumen, or the angle of flexion, especially when the latter has become rigid from long duration and secondary inflammatory changes. The more frequent cause of both, however, is the passive hyperemia and the resulting congestive endometritis, while the sterility is still further accounted for by the frequent hypoplasia.

**Diagnosis.**—After emptying the bladder the ante flexion is recognized bimanually, the form and direction of the vagina being noted. (Plate 22.) The sound demonstrates the direction of the cervix and the size of its

<sup>1</sup> The normal length of the uterus, as measured by the sound, is six centimeters.



lumen,<sup>1</sup> whether it is narrowed throughout or at one of its orifices only, and whether secondary dilatation of the uterine cavity or cervical canal has taken place. (Plate 15, Fig. 3.)

**Treatment.**—If no other cause for the symptoms exists (an endometritis, for example), the stenosis should be removed by dilatation with metal sounds, laminaria tents, or iodoform-gauze tampons every few weeks. A more permanent result is obtained by making, immediately after the period, bilateral transverse incisions, about one centimeter deep, in the cervical commissures by means of Cooper's scissors. The mucous membrane of the cervical canal is then brought into apposition with that of the intravaginal cervix in such a manner that the two rows of stitches pass from the anterior to the posterior cervical lip and the uterine orifice gapes. The fresh surfaces are so liable to form adhesions after this operation of Sims' that it is better to make four radiating incisions (Kehrer), or to transplant a flap, with a pedicle, from the cervix to the incision. This is followed by a tamponade of ferripyrin cotton, which is nonirritating. In stenosis of the entire cervical canal faradization should be employed, with the negative pole in the cervix (fifty milliamperes for five minutes, twice a week for two months).

The anteflexion is treated by the introduction of a stem-pessary made of silver. The stem should be from 2 to 3 mm. thick, the length from 1 to  $1\frac{1}{2}$  cm. shorter than the uterine cavity, and the plate from 2 to  $2\frac{1}{2}$  cm. in diameter (v. Winckel). If the direct introduction of the stem is impossible, it may be introduced alongside of a sound. It is to be held in position for a few days by a tampon, and the patient kept quiet. If an inflammatory reaction occurs, the tampon is to be removed. This stem seems not only to remove the flexion, but also to act favorably on the dysmenorrhea and sterility (v. Winckel). It

<sup>1</sup> The normal cervical canal will accommodate a sound four millimeters in diameter.

stimulates and invigorates the organ. The vagina should be washed out daily, and the stem should be changed every few months. [The dangers involving the use of intra-uterine stem-pessaries have caused them to be abandoned by most practitioners. Forcible dilatation and overstretching of the cervical canal by means of graduated bougies or branched dilators are now usually employed. The endometritis resulting from the stenosis and aggravating the symptoms renders a thorough curetment a necessary part of the operation of dilating the cervical canal for stenosis causing dysmenorrhea and sterility.—ED.]

**5. Stenosis Vulvovaginalis or Hymenalis.**—Incision is necessary only in a marked degree of vagina infantilis, and then a flap should be transplanted. Should the hymen be too resistant and interfere with coitus, it should be incised and appropriately sutured, since forced immissio penis or the descending head has caused lateral lacerations from which considerable hemorrhage has occurred. The more insignificant stenoses are to be dilated, either quickly or slowly, with iodoform gauze. In neuro-pathic individuals simultaneous spasms of the constrictors often occur. (See *Vaginismus*.)

#### § 4. ANOMALIES OF MENSTRUATION.

**Physiologic menstruation** commonly appears first at puberty (from the age of fourteen to sixteen years in our climate; earlier in warmer countries; in large cities earlier than in the country), and is a sign of sexual maturity. It occurs as a hemorrhage, dependent upon a regular monthly determination of blood to the genitalia, in consequence of which the uterine mucous membrane becomes more vascular, spongy, and better fitted for the reception and development of an impregnated ovum. Ovulation occurs at the same time, and is due to the escape of a mature ovum from a ruptured Graafian follicle. The entire process (ovulation and menstruation) is regu-

lated by a nervous center, and goes hand in hand with periodic variations in the body-metabolism, which is least active at the time of the menstrual flow. The hemorrhage has its source in the mucous membrane of the uterine cavity, and recurs periodically unless pregnancy supervenes. (See "Atlas of Obstetric Diagnosis and Treatment," second edition, § 1.)

Various disturbances may precede or accompany menstruation, and are to be looked upon as expressions of fluctuations in the body-metabolism. These are: Exanthemata (herpes labialis, acne), skin irritations, chilliness, neuralgia, malaise, dizziness, borborygmus, diarrhea with suddenly appearing constipation, a preceding leukorrhea for several days, a more frequent desire to urinate, and a urine loaded with urates.

**6. Evolutio Præcox.**—In these cases menstruation may occur during childhood, and the individual may present all the appearances of sexual maturity.<sup>1</sup> Should she become pregnant, delivery will usually take place without special difficulty.

**7. Oligomenorrhea and Amenorrhea.—Etiology.**—In §§ 1–3 we have already found a series of causes for amenorrhea in the anomalies of development of the genitalia. These can be divided into:

(a) Permanent organic causes: defects of the uterus, ovaries, or Graafian follicles (either congenital or resulting from an infantile oophoritis), with otherwise completely developed genitalia.

(b) Functional disturbances, which persist in some cases: infantile genitalia (hypoplasia, antelexion, stenosis, insufficient development of the uterine mucosa), anemia, especially in neuropathic individuals (lack of determination of blood to the uterus).

(c) Mechanical obstructions: atresias.

(d) Affections that cause a symptomatic amenorrhea:

<sup>1</sup> The not infrequent hemorrhages from the genitalia of the newborn should be excluded from this classification.

morphinism ; obesity ; severe acute diseases ; excessive disturbances of the circulation from catching cold or from emotional excitement (fright, fear of pregnancy) ; diseases of the genitalia, such as metritis (contraction of the mucous membrane), perimetritis (ovaries and tubal ostia embedded in exudate), and oophoritis ; ovarian tumors ; puerperal hyperinvolution (atrophy of the genitalia) ; and pregnancy. The latter causes a physiologic amenorrhea, but nevertheless it should be noted that ovulation and conception may occur.

**Treatment.**—It should first be determined whether the case is one of true amenorrhea or whether it is caused by mechanical hindrances (congenital or acquired) to the exit of blood. The treatment of the latter conditions (*groups a and c*), both curative and symptomatic, has been fully described in § 1. (See Plate 38.)

**Group b** (see § 3) requires a tedious yet often a fruitful line of treatment. The careful regulation of the manner of living is of the utmost importance. Every injurious influence should be removed, the more pernicious being : overexertion, especially that of a mental nature (hard study ; constant application to school-exercises, embroidery, or sewing ; frequent visits to theaters, balls, etc.) ; too much or too little sleep ; exhausting diarrhea or leukorrhea ; masturbation ; and the ingestion of improper food. The diet should at first be bland, nutritious, and of such a nature that constipation and tympanites are avoided ; meat diet later. The household duties are to be regularly arranged ; if possible, daily walks of one or two hours in the country are to be recommended, taking care to avoid fatigue ; the bowels must be regulated (fruit, abdominal massage, injections of lukewarm water with or without soap or oil, laxatives). Certain drugs stimulate the appetite and are of value. Especially useful are blood tonics, such as Hommel's hematogen (hemoglobinum liq.), Dahmen's hemalbumin powder, nutrol, wine with peptonate of iron, or Blaud's pills with tincture of cinchona.



The circulation should be encouraged by warm foot-baths ( $95^{\circ}$  to  $100^{\circ}$  F., with a few teaspoonfuls of salt or mustard, once or twice daily), warm sitz-baths or full baths, and the application of sinapisms to the thighs when congestion of the pelvic viscera and a mucous vaginal discharge point to a menstrual epoch. Cold baths should be forbidden. The patient should be warmly clothed. Sea air is beneficial, from its stimulating effect upon the appetite. Nervous, chlorotic girls are benefited by the rest-cure (Weir Mitchell-Playfair). For the local treatment see § 3. The importance of massage should not be forgotten.

**Group d** calls for treatment of the primary affection. It is in this class of cases alone that stimulating drugs are to be used: potassium permanganate, sodium salicylate, santonin, and aloes. Their use is by no means productive of uniform success. Hyperinvolution is treated by massage and electricity. (See § 3, Stenosis.)

Dependent upon the amenorrhea, the following secondary conditions are observed:

*a.* Marked disturbances of metabolism, which lead to dyspepsia of a severe type, tympanites, and secondary anemia.

*β.* Vicarious hemorrhages from other mucous membranes (renal, vesical, gastric, intestinal, nasal), and from the skin, ears, or anterior chamber of the eye. It is difficult to say whether these are results or causes of the amenorrhea, as they do not appear at strictly periodic intervals.

*γ.* Periodic exanthemata: erythematous, impetiginous (especially at the edge of the lip), and pustular (acne).

*δ.* Periodic neuroses: neuralgia, palpitation, cerebral congestion, dyspnea (asthma uterinum), cough (tussis uterina), gastric colic, digestive disturbances, etc.

**Treatment.**—For the vicarious hemorrhages: hot irrigations, scarification of the vaginal cervix; for the acne: Lassar's paste,<sup>1</sup> sulphur ointment, pills of ichthyol ( $1\frac{1}{2}$

<sup>1</sup> See "Therapeutic Table."

gr. in lozenges); for the urticaria and erythema: laxatives, salicylated alcohol, five per cent. menthol spirit, atropin, sodium salicylate ( $1\frac{1}{2}$ –2 drams daily); for the impetiginous eczema (pustules with honey-yellow crusts): diachylon ointment<sup>1</sup> or bismuth salve; for the herpes: zinc oxid ointment; for the neuralgia and asthma: caffeine, antipyrin, inhalations of chloroform, infus. digitalis, and ice-bag over cardiac region. General nerve tonics and hydrotherapy are indicated.

**8. Dysmenorrhea** is characterized by violent pains (causing reflex hemicrania, nausea, vomiting, dizziness, and hysteric symptoms), which emanate from the uterine and paracervical ganglia, and are to be looked upon as symptoms from the lumbar cord. Other diseased organs (liver, heart, lung, stomach) participate in the disturbances.

From an etiologic standpoint seven forms may be differentiated:

(a) Reflex, from diseased ovaries, tubes, perimetrium, etc.

(b) In the initial stage of intramural myomata.

(c) So-called neuralgia uteri, with spasmodic flexion of the uterus (author) from fright, interrupted coitus, masturbation, thermic and mechanical insults, acute colds.

(d) Congestive, with flexions of the uterus and all conditions that occasion a hyperemia of the organ and its ligaments. The pain precedes the flow and ceases with its onset, when the blood-vessels are relieved.

(e) Inflammatory, with endometritis, metritis, parametritis, and perimetritis. The pain is most severe at the beginning of the period and gradually abates; the uterus is very sensitive, sometimes spasmodically contracted. When the congestive (d) and inflammatory (e) dysmenorrheas have reached their height, shreds of mucous membrane, sometimes the entire mucosa, may be cast off (decidua menstrualis). This condition is designated as dysmenorrhœa membranacea with endometritis exfoliativa.

(f) Obstructive, often a result of c and d (see also §§ 3

and 4, amenorrhea), or arising from too rapid or too profuse a secretion of blood, stenosis or flexion of the cervix, or swelling of the endometrium. The pains follow the onset of the menses, and resemble those of labor. Large clots or shreds of mucous membrane are sometimes discharged.

(g) *Exfoliatio mucosæ menstrualis* or dysmenorrhœa membranacea *without* endometritis.

**Diagnosis and Treatment.**—Indicated under the corresponding letter.

(a) In every case of dysmenorrhea the constitution of the patient should be considered, and the exact condition of the entire genital apparatus should be determined by bimanual palpation and, if necessary, by exploration with the sound.

(b) It is impossible to diagnose small intramural myomata before they cause a projection of the uterine wall or a change in its consistence. The characteristic symptoms are violent, fixed, boring pains, without fever. These are controlled by suppositories, vaginal or rectal injections, or pills of chloral, or by use of extract of belladonna or hyoscyamin, tincture of opium, or antipyrin. Rubefacients (sinapisms, menthol, or spirits of camphor on compresses), ergotin, and salt baths are useful in the treatment of this condition. The patient should rest in bed during the attack.

(c) Potassium bromid, caffein, sodium benzoate, phenacetin, antipyrin (also as a wash), fluid extract of viburnum prunifolium, potassium permanganate (to be taken one week before the period), and the pills and rubefacients previously mentioned. Diaphoresis should be encouraged.

(d) Rest in bed, warm clothing, especially over the abdomen, hot sand-baths, rubefacients (see b). Laxatives and ipecac to prevent overfilling of the stomach, antimonials and diaphoretics for the catarrh. Local depletion of the blood-vessels by scarifications, two leeches to the cervix, copious hot vaginal injections, or glycerin and

astringent tampons. Any existing cause should be appropriately treated: flexions, by pessaries, massage, etc.; stenosis, by dilatation.

(e) Removal of the inflammation. Treatment of attack as in *d*; above all, blood-letting (two leeches) and laxatives, scarifications of the cervical mucosa, wedge-shaped excisions (see Metritis), atmocausis (vaporization, see Endometritis).

(f) See treatment of stenosis and amenorrheas in §§ 3 and 4.

(g) According to v. Winckel, the application of two leeches to the cervix at repeated intervals prevents the casting off of the decidua menstrualis and allows conception and recovery to take place. Curetment and application of zinc chlorid (chlorid of iron after the operation), atmocausis, or zestocausis (see Endometritis). Symptomatic, as under *b* and *d*.

*Diagnosis of Exfoliatio Mucosæ Menstrualis.*—The prodromes are sensations of heat and cold, nausea, vomiting, dizziness, headache, and unconsciousness, with or without hysteric convulsions. Circumscribed pain in the lower abdomen. The discharged blood may be small in amount.

The membrane is passed with or without pain. If complete, it has a triangular shape, showing the position of the three uterine orifices (ostia tubarum, os internum). The outer surface is rough and tattered, having been torn from the uterine wall; the inner surface is smooth, offering for inspection furrows and minute glandular orifices.

*Microscopic Structure.*—The connective tissue is increased, and its interstices are filled with exudate and small round cells, which push apart the utricular glands. The latter are seen in cross-section, with their cylindric epithelium and blood-vessels. Larger cells rarely appear, and then are quite isolated. The picture is practically that of interstitial endometritis. Löhlein points out that pieces of mucous membrane obtained by curetment between two periods show none of the foregoing changes.

Membranes are sometimes cast off from the vagina in *colpitis exfoliativa*, consisting of polygonal squamous epithelial cells with relatively large vesicular nuclei. Similar membranes may be exfoliated from a changed epithelial layer of the lower portion of the cervix. (See Plates 28 to 31.)

*Microscopic Differential Diagnosis.*—The *decidua vera graviditatis* consists of a layer of large, irregular, roundish (decidual) cells possessing large nuclei (often multiple). These completely conceal the scanty connective-tissue framework.



**9. Menorrhagia.**—By this term we designate those uterine hemorrhages that are so profuse in proportion to the general constitution of the individual that symptoms of anemia appear, or, if already present, become exaggerated. Its manifestations are dizziness, unconsciousness, ringing in the ears, flickering of objects before the eyes, nausea, vomiting, constipation, a striking pallor of the mucous membranes, lassitude, pain in the back, shortness of breath, palpitation, etc. The menorrhagia may be habitual or temporary.

**Etiology.**—(a) Diseases of the genitalia: tumors, displacements and inflammations, swellings of the endometrium; (b) diseases of other organs that cause circulatory disturbances (heart, lungs, kidneys, spleen, liver); (c) associated with intestinal diseases (dysentery, constipation); (d) nervous hyperemia (emotion, hot drinks); (e) associated with constitutional diseases (Werlhof's disease, excessive development of the panniculus adiposus).

**Treatment.**—Symptomatic—rest in the horizontal position, a bland diet, soothing drinks (acids, effervescing powders), hot fomentations of alcohol, sinapisms.

*Group a:* See treatment of endometritis (especially the fungous and hemorrhagic forms), chronic metritis in the stage of engorgement, parametritis and perimetritis, fibroid and mucous polyps of the uterus, sarcoma and carcinoma, ovarian tumors, flexion and prolapse of the uterus.

If radical treatment is not adopted, the hemorrhage is to be controlled by ergotin, cornutin, secale cornutum, or *hydrastis canadensis* (hydrastin), stypticin, hot vaginal irrigations (113° to 125° F.) at intervals of from three to six hours, very firm tamponade of the vagina (iodoform gauze or salicylated cotton), or even tamponade of the cavity of the uterus with iodoform gauze or laminaria. The solution of ferric chlorid may be applied upon cotton, as a direct local hemostatic, or the medicated sound (aluminum or wood)

may be introduced into the cervix and allowed to remain there for from two to three hours. Ferripyryn has proved itself to be of value, controlling the hemorrhage and producing no irritation. It is used as a powder or, better, as sterilized "nondraining ferripyryn-nosophen gauze."<sup>1</sup> Injections of gelatin solution and atmocausis (see treatment of endometritis hæmorrhagica) are to be recommended.<sup>2</sup>

*Group b:* Digitalis, expectorants, and the waters of Karlsbad, Franzensbad, Kissingen, Wildungen, Neuenahr, and Vichy have a specific action.

*Group c:* Laxatives (enemata of infusum sennæ, strong infusions of rhubarb, 10 : 100, oleum ricini).

*Group d:* Arrest hemorrhage as in group *a*; ergotin; reduction of obesity by the methods of Banting, Mendelsohn, Epstein, or Oertel; sojourn at Marienbad; and vegetable diet. In hemophilia and scurvy, hydrotherapy and subcutaneous injections of gelatin. Calcium hypophosphite by the mouth or rectum.

## § 5. STERILITY.

The **causes** of sterility may be found in the physical or psychic nature of the husband or wife, or in the habitual disease of the product. They may be divided into four groups :

1. Impotentia coëundi from organic defects or from nervous or psychic influences.

| HUSBAND.  | WIFE.  |
|---|--|
| Epispadias and hypospadias; paresis and paralysis of the nervi erigentes from psychic influence or nervous weakness (affections of the brain and spinal cord, age, perverted habits, etc.); aspermatism from cicatricial stenosis; prostatic hypertrophy. | Atresia or stenosis of the hymen or vagina; vaginismus; obstructing tumors or inflammations; absence of sexual desire. |

<sup>1</sup> Prepared under the author's direction by Evens and Pistor, of Cassel.

<sup>2</sup> A complete report of the indications for these new methods of hemostasis and results of their application is to be found in the author's article in the June number of "Deutschen Praxis," 1899.

## 2. Azoospermism or arrested formation of the genital cell.

HUSBAND.

Atrophy of the testicles (from gonorrhea, orchitis, trauma, and like causes); atresia of the ejaculatory duct.

WIFE.

The Graafian vesicles fail to rupture, either from congenital or inflammatory causes; ovarian tumors.

## 3. The spermatic filament is deposited in the female genitalia but is unable to come in contact with the ovum.

Atresia or stenosis of the uterus or tubes (flexions of both), cervical plugs of tough mucus (endometritis); uterine or tubal tumors; perioophoritic pseudomembranes.

## 4. The ovum fails to lodge in the uterine mucosa.

Endometritis; uterine tumors; weakness; diseases of the ovum.

**Examination.**

HUSBAND.

Since gonorrhea is a frequent cause of azoospermism and cicatricial stenosis, the previous history is to be carefully considered and the number of well-formed spermatic filaments in the semen is to be determined.

WIFE. (See §§ 1 to 4.)

Character of the menses; presence of fluor albus (gonococci); uterus, by speculum and sound; uterus and adnexa, bimanual.

The **treatment** depends upon the cause demonstrated. If no reason can be found, advise the patient to hold the semen in the vagina as long as possible (with the knees together), as Marion Sims proved that the posterior vaginal vault acts as a seminal receptacle, the intravaginal cervix (in the normal position of the uterus) being here bathed in the spermatic fluid. In some cases coitus must be practised with the pelvis of the female elevated, or a *posterioribus*.

## GROUP II.

### CHANGES OF SHAPE AND POSITION.

---

#### CHAPTER I.

##### HERNIA.

The abdominal organs may be invaginated into natural, preformed canals,—being covered by the enveloping soft parts,—and may present themselves in the abdominal wall, in the gluteal region, in the course of the femoral vessels, in the vagina, or in the labia. For vaginal hernia see also Inversion of the Vagina, § 7.

#### § 6. HERNIA AND OTHER CHANGES OF SHAPE OF THE VULVA.

The hernial contents may consist of the uterus—especially one horn of a uterus bicornis—and its adnexa (ovary, see § 1, Pseudohermaphroditism), with or without the intestine and its appendages, or of the intestine alone.

The more frequent path is through the inguinal canal (Fig. 23); less often in front of the broad ligament and along the levator ani. In the first case we speak of a hernia inguinalis labialis (anterior); in the latter, of a hernia vaginalis labialis (posterior). The hernia may attain the size of a melon.

**Diagnosis.**—Varying changes of size of the tumor, reduction of contained intestine (usually filled with gas and fluids) with a “gurgle,” the characteristic form and

sensitiveness of the ovary, impulse on coughing, etc., all establish the nature of the swelling.

**Treatment.**—Just as in other hernias—taxis and retention by a truss (Scarpa) or by a large, hollow, vaginal ring (hard-rubber). If reduction is impossible, open the sac and replace, or an abdominal section may be performed, the hernia reduced, held by fixation sutures, and the orifice closed.

**Other changes** of shape are seen in the duplication and enlargement of individual parts—the nymphæ and clitoris—which may give rise to irritation, excoriation, edema, etc.

**Treatment.**—Frequent washings, using astringents if necessary, and applications of oak-bark decoctions or lead water, constitute the preventive treatment. Boric ointment or bryolin, sitz-baths with bran, dermatol, bismuth-talc, nosophen-starch, or applications of solutions of cocain are to be used for their curative action.

## CHAPTER II.

### INVERSION AND PROLAPSUS.

These conditions hold a certain mutual relation, inasmuch as the former is a weighty predisposing cause of the latter. The inverted vagina easily drags the uterus to the vulva, while in other cases the *inversio vaginæ* and the prolapsus may be traced to a common cause. On the other hand, the uterine prolapse, or apparent prolapse, due to hypertrophy of the cervix, may lead to protrusions of the vaginal mucous membrane.

#### § 7. THE INVERSIONS OF THE VAGINA AND UTERUS.

Inversions of the lower half of the vagina mostly lead to the formation of hernias; the most frequent are those of the posterior wall of the bladder (*Cystocele*, Plate 5, Fig. 1) and of the anterior wall of the rectum (*Rectocele*, Plate 5, Fig. 2). The upper half of the vagina is far less often the seat of inversion, the other organs carrying the rectovesical or vesico-uterine folds of peritoneum ahead of them. In the "Atlas of Obstetric Diagnosis and Treatment" (Figs. 102 to 105) cases of incarcerated retroflexed gravid uteri and of extra-uterine pregnancy are illustrated in which the gestation sac causes a protuberance of the vaginal wall.

Among the rarer cases brought to our notice are ovario-colpocele, enterocolpocele (Plate 19, Fig. 1), hydrocolpocele, pyocolpocele (Plate 58, Fig. 1, and Plate 59, Fig. 3), and those bulgings of the vaginal wall that are brought about by tumors of Douglas' pouch (Plates 58 and 59), or



of the rectovaginal or vaginovesical septa. (Plate 58, Fig. 3 ; Plate 88, Figs. 5 and 6.)

If the ovary, intestine, or omentum becomes fixed in the pouch of Douglas, it may cause the vaginal wall to bulge, so that in extreme cases it presents itself at the vul-

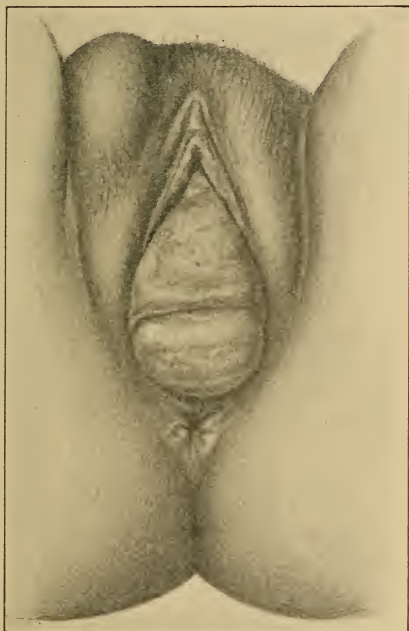


Fig. 23.—Inversion of both vaginal walls and inguinal hernia of the right labium in a case of lacerated perineum (photograph of an original water-color). The two conditions are not infrequently associated, as they have a common cause—relaxation of the supporting tissues.

var opening. This is particularly true in cases of retroflexion or prolapse of the uterus. The simultaneous inversion of the anterior and posterior vaginal walls is rare, because it could be caused only by an influence exerted at



the same time on both recto-uterine and vesico-uterine cul-de-sacs. It is rarely caused by ascites (with a retroflexed or vertical uterus), more frequently by pus or an encapsulated peritoneal exudate (pyocolpocoele).

**Diagnosis.**—See scheme and differential diagnosis of tumors of the recto-uterine pouch, § 35.

In ovariocele bimanual exploration reveals a characteristic form, sensitiveness, and relation to the tube and uterus. If the ovary is enlarged or embedded in exudate, other differential points must be considered (exploration per rectum).

Enterocoele is recognized by the signs common to all intestinal hernias, palpable and audible gurgling and changes in the tension of the tumor, with variations of intra-abdominal pressure (impulse on coughing).

Hydrocolpocoele and pyocolpocoele are to be suspected if the symptoms of ascites and peritonitis are present. (See Peritonitis.) Carefully examine the previous history.

**Prognosis and Treatment.**—An enterocoele can become troublesome only during delivery. Reduction from the rectum if necessary; colporrhaphy, in some cases during pregnancy.

A displaced ovary should be repositied, the patient being in the lateral or knee-chest posture (narcosis if necessary, finger in rectum). The difficulties encountered are dependent entirely upon the number of adhesions. The reposition of ovarian tumors during pregnancy or labor may lead to serious consequences. If it fails, the tumor must be tapped from the vagina.

The prognosis and treatment of hydrocolpocoele and pyocolpocoele are the same as those of the causative disease. Puncture from the vagina if condition is analogous to cases just mentioned.

**Inversion of the posterior vaginal wall** may lead to rectocoele. As the two organs are connected only by loose connective tissue, this displacement does not always

occur ; indeed, the rectum generally induces it. As usual causes may be mentioned relaxed vaginal walls, gaping of the vulvar cleft, with or without perineal laceration, and prolapse of the uterus. It presents itself to the examining finger as a pocket, which causes constipation and tenesmus. (Plate 4, Fig. 1 ; Plate 5, Fig. 1 ; Fig. 27.)

The **treatment** consists in the repair of the perineum and pelvic floor and in the shortening and narrowing of the vagina. (See operations described under Prolapse of the Uterus.) When the muscular coat of the vagina is relaxed from colpitis : astringents, either as injections (solutions of aluminum acetate, 10 to 20 %) or upon tampons (glycerite of tannin). A pessary should be looked upon as a temporary makeshift.

**Inversion of the anterior vaginal wall** is more frequently by far associated with cystocele, because the two organs are firmly connected, and the intra-abdominal tension causes the bladder to follow the vaginal wall. The bladder is divided into two pouches, one lying behind the pubic symphysis, the other in the cystocele. The latter draws the urethra down with it, causing it to assume an S-shape. The greater concavity looks downward and leads into the cystocele. (Plate 4, Figs. 2 and 3 ; Plate 3, Fig. 5 ; Plate 5, Figs. 2 and 4 ; Plates 8 and 9, Catheterization ; Plate 12 ; Plate 13, Condition in Artificial Prolapse.) The disturbances of the circulation in the inverted parts sometimes cause dysuria, and, together with the inability completely to empty the bladder, may lead to cystitis and to the formation of vesical calculi.

**Treatment.**—Plastic operations to narrow the anterior vaginal wall and to retain the bladder and the vaginal wall in their proper places.

### INVERSION OF THE UTERUS.

This is an affection, severe in its nature, arising under quite similar circumstances. The chief etiologic factor is

## PLATE 3.

FIG. 1.—**Impressio fundi uteri** as an initial stage of inversion of the uterus arises when the organ is relaxed, and Credé's method is too forcibly exercised, or traction is made upon the cord.

FIG. 2.—**Partial Inversion of the Uterus.** A portion of the cervix has not yet become invaginated. The inverted uterus already forms a considerable peritoneal pocket; this "funnel" is filled by the tube and ovary.

FIG. 3.—The uterus has become invaginated as far as the external os; the latter, however, has not descended.

FIG. 4.—The completely inverted uterus protrudes from the vulva; the upper portion of the vagina has also become invaginated as far as the constrictor cunni and levator ani.

FIG. 5.—**Complete Prolapse of the Retroflexed Uterus and of the Vagina with Laceration of the Perineum; Cystocele.** (See Fig. 28 and Plates 8-10.) The apex of the bladder approaches the fundus; the vesical diverticulum reaches to the internal os; the pouch of Douglas lies in the prolapse, containing, however, no intestinal loops (enterocele), as sometimes occurs in rare cases; the intestines are held back by the retroflexed corpus uteri. The external os is everted; the cervix is swollen.

This illustration represents one of the extreme possibilities of prolapse, and at the same time the most frequent manner of its development.

---

a relaxation and dilatation of both the uterine and cervical walls. The direct cause is most frequently an acute one, occurring in the puerperium (precipitate birth, forced Credé's method, traction on the cord); or one chronic in its nature, such as traction upon the fundus uteri from the expulsion of a fibroid polyp. If the tumor is submucous, the mucous membrane alone is drawn down; if it is intramural, the muscular coat, or even the serous covering, may be invaginated, so that a peritoneal "funnel" is formed in which the adnexa or intestinal coils (only in puerperal inversions) may lie (Kehrer). The latter may contract

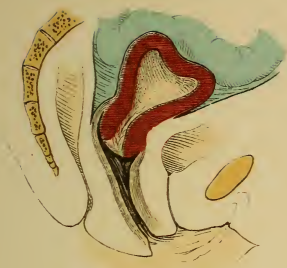

Fig. 1.

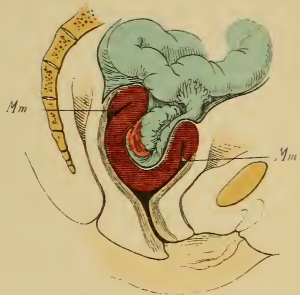


Fig. 2.

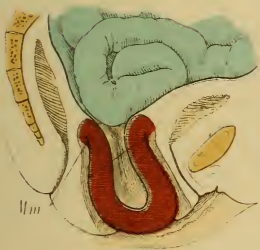

Fig. 3.

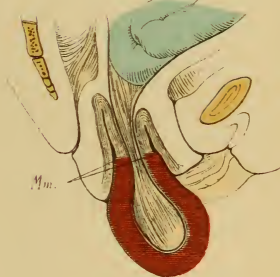


Fig. 4.

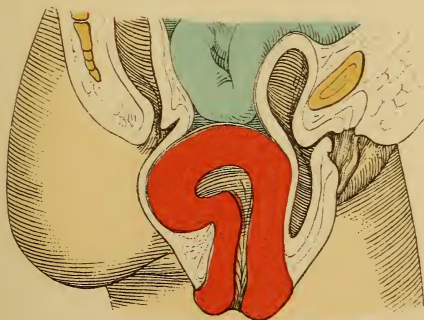


Fig. 5.





inflammatory adhesions in cases of long standing. (Plate 3, Fig. 2; Fig. 24.)

Different degrees of inversion may be differentiated: complete, including the entire cervix; complete, with inversion of the vagina (*inversio uteri cum prolapsu*); incomplete, as far as the internal os. The slightest degree is the *impressio fundi uteri*. (Plate 3.) The acute puerperal inversion may become chronic.

**Symptoms.**—The mucosa swells and proliferates from the constriction. It bleeds easily, and ulcers arise from friction. The ulcerated surfaces may grow fast to the vaginal mucosa, or gangrene may appear. The acute puerperal form occurs with violent symptoms resembling shock.

The chief symptoms are pain and hemorrhage, dependent upon the nature of the tumor. They render the patient anemic and force her to stay in bed.

**Diagnosis.**—An exact portrayal of the existing conditions is demanded, as an inverted uterus has been repeatedly confounded with a polyp, and cut off.

In complete inversion with prolapse we find a red, solid-elastic tumor, which bleeds easily and is sensitive to pressure. The uterine orifices of the Fallopian tubes may probably be recognized.

In incomplete inversion the sound may be passed into the cervix, beside the tumor (*corpus uteri*), for quite a distance—further in front than behind (from 3 to 4 cm.). Bimanual palpation is of importance; it demonstrates the absence of the uterus from its usual position and the presence of the peritoneal “funnel.”

**Treatment.**—If due to a tumor, enucleation of the same, whereupon the uterus usually reinverts itself spontaneously. If irreducible from proliferative thickening of the uterine wall, amputation of the organ close to the external os, carefully closing the peritoneal funnel with sutures. In acute puerperal inversion, manual reposition (as in phimosis), trying to push back the portion in con-

tact with the external os first, and making counterpressure from the abdomen to prevent elongation and possible laceration of the vagina.

The earlier the attempt is made, the more likely is it to be crowned with success. If manual reposition fails, the parts are to be carefully disinfected and pushed back by

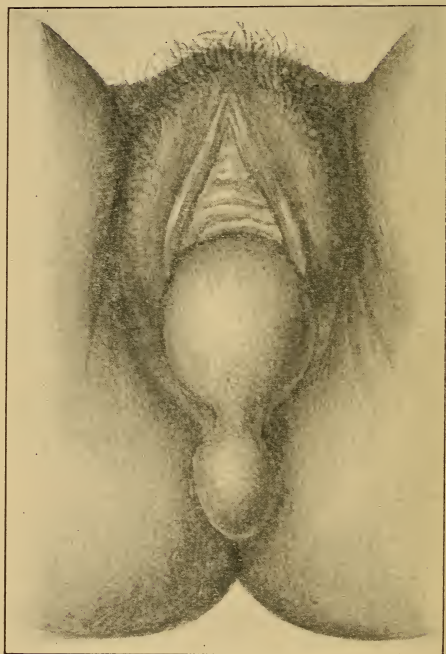


Fig. 24.—Complete inversion of the uterus from a myoma of the fundus. (See Plate 3.) (Original diagrammatic drawing.)

the colpeurynter (always to be filled *after* introduction) or by means of astringent tampons. These are held in position until the tumor is partly reduced, when the reinversion is completed by cold-water injections. Massage of the uterus assists the action of the colpeurynter, and ergot



effects the contraction of the organ. Elevations of temperature give warning of the onset of pelvic peritonitis, when all attempts at reduction must be discontinued.

Celiotomy is indicated only in extreme cases. A better method is that of Küstner, who makes an incision in the posterior vaginal vault, which enables him to incise the posterior uterine wall throughout its entire length, and to reinvert the organ. Kehrer attacks the uterus through the anterior vaginal vault.

### § 8. PROLAPSE OF THE VAGINA AND UTERUS.

When the external os sinks below the interspinous plane, we speak of *descensus uteri*. If in addition to the descent of the uterus the lower portion of the vagina protrudes at the vulva, the case is one of incomplete or partial prolapse of the vagina; if the vaginal vault also protrudes, complete prolapse.

In incomplete prolapse of the uterus the cervix alone protrudes at the vulva; in complete prolapse the entire organ—with the completely inverted vagina, and cystocele or rectocele, or both—lies outside of the introitus.

#### The Normal Situation and Position of the Uterus.

The normally situated uterus lies in the true pelvis in a position of anteversion. The anterior surface is obliquely placed, facing the bladder; the posterior surface is strongly convex, and is parallel to the upper sacral curvature. The longitudinal axis of the organ passes from above downward, and from before backward. If fixed points are desired, the fundus marks the center of the conjugate vera, and the external is in the interspinous plane, being somewhat nearer to the sacrum than to the symphysis. (Plates 14 and 22.)

This position is not a constant one, however; the uterus is in a condition of unstable equilibrium, the fundus descending with every inspiration. In the upright position the fundus is still lower, while the cervix becomes more elevated. It is balanced upon an axis of fixation corresponding to the internal os, this portion of the neck being suspended from the pelvis and sacrum by the supravaginal connective tissue and the involuntary muscle-fibers of the uterosacral ligaments. In the dorsal position the fundus goes backward and the cervix approaches the symphysis. The position is also dependent upon

## PLATE 4.

**FIG. 1.—Incomplete Prolapse of a Retroverted Uterus ; Marked Rectocele ; Vaginal Inversion.**

**FIG. 2.—Incomplete Prolapse of the Uterus, Due to Hypertrophy of the Intermediate Portion of the Neck ; Inversion of the Vagina with Cystocele.** (See Plate 12.) The fundus of the uterus is nearly at its normal height. The sound shows the uterine canal to be longer than normal (longer than 5 or 6 cm.). The distance from the internal to the external os demonstrates the elongation to be in the intermediate portion of the cervix. The portion of the neck that is elongated is further shown by the relation of the anterior and posterior vaginal fornices to the external os and to the internal os.

The illustration shows the posterior vaginal vault at its usual height in the pelvis ; the anterior, however, is lower, and yet holds its usual relation to the external os ; consequently, it is not the intra-vaginal cervix that is hypertrophied, but the middle portion of the neck, situated between the anterior and posterior vaginal fornices and lying higher up.

**FIG. 3.—Total Prolapse of Anteфлекed Uterus and of the Anterior Vaginal Wall, with Cystocele ; Characteristic Flexion of the Urethra.** (See also Plates 8 and 9, Introduction of Catheter.)

**FIG. 4.—Complete Prolapse of Retroflexed Uterus (First Degree) and of Vagina.** Small rectal and vesical diverticula.

## PLATE 5.

**FIG. 1.—Prolapse of Posterior Vaginal Wall ; Rectocele ; Descent of Retroflexed Uterus (Second Degree).** The posterior vaginal wall seldom becomes inverted first ; a rectal diverticulum may form in the pouch, demonstrable to the introduced finger.

**FIG. 2.—Prolapse of the Anterior Vaginal Wall ; Extreme Grade of Cystocele ; Anteфлекion of the Uterus (First Degree) ; Descent of the Uterus.** Evidence of the existence of a cystocele is obtained by the catheter. (See Plates 8 and 9.)

**FIG. 3.—Reposition of Prolapsed Uterus by a Martin Stem-pessary.** (Original diagrammatic drawing, modified according to Schröder.) This pessary is applicable when the genitalia are roomy or relaxed. The stem rests upon the levator ani, receiving lateral sup-

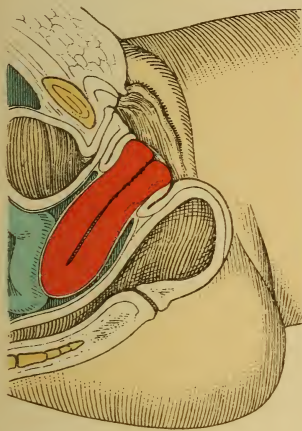


Fig. 1.

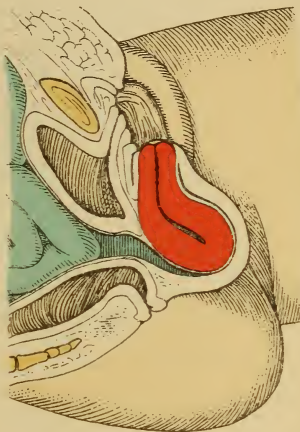


Fig. 4.

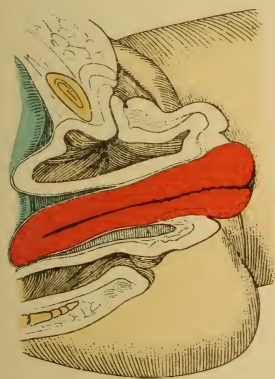

Fig. 2.

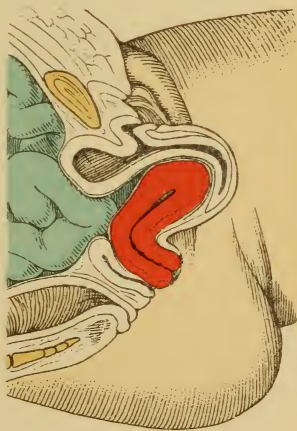

Fig. 3.



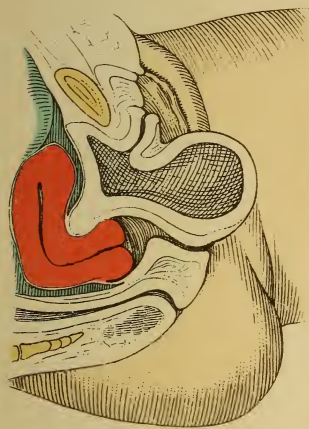


Fig. 2.

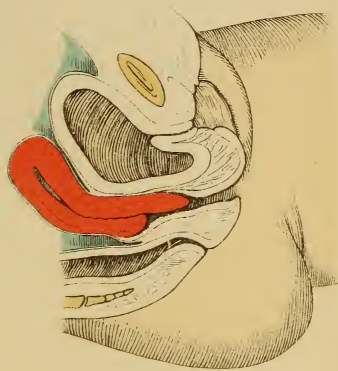

Fig. 4. . . . . Lith. Aust. F. Reichhold, München.

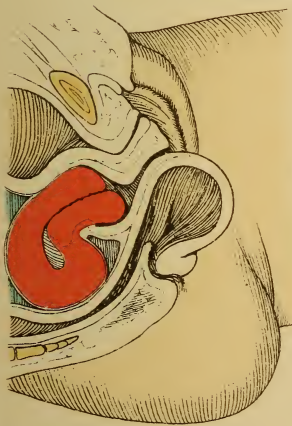


Fig. 1.

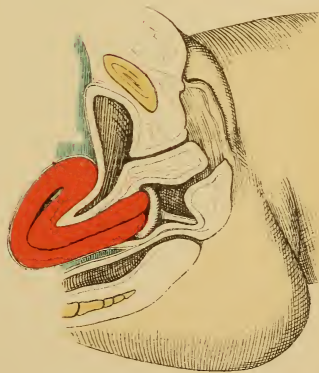

Fig. 3.





port if it slips to one side. This case is one of pseudoprolapse, because the reposition unduly elevates the fundus, anteflexes the body, and draws up a diverticulum from the bladder. The condition is really elongation of the neck, and amputation is indicated.

**FIG. 4.—Hypertrophy of the Anterior Lip of the Uterus, Producing Inversion of the Anterior Vaginal Wall and Cystocele.** (Original diagrammatic drawing modified according to Schröder.)

the degree of distention of the bladder and rectum. (See §§ 10 and 11, Plate 17, Fig. 2 ; Plate 14, Figs. 1 and 4 )

The uterus is not really "suspended," but the ligaments limit the excursions of the organ beyond a certain point. It really rests indirectly upon the floor of the pelvis, the external os pressing against the posterior vaginal wall, and the cervix being grasped by the connective tissue surrounding the vaginal vault. The latter is partly held up by ligaments, but more particularly by the vaginal walls themselves, these in turn deriving their support from the pelvic floor (constrictores cunni, levatores ani) and perineum. The integrity of the perineum is consequently a most important factor in preventing the descent of the internal genitalia, the ligaments being a secondary consideration. It is not to be forgotten that the uterine supports may be insufficient to withstand an increased pressure from above (tumors) or traction from below. These structures are assisted by atmospheric pressure when the patient is in the knee-elbow position, and Sims' speculum is introduced. The round ligaments resemble a bridle, having no supportive action.

The size of the uterus also influences the existing conditions.

The recto-uterine fold of peritoneum is normally 7 cm. above the anus ; the vesico-uterine,  $7\frac{1}{2}$  cm. above the urethral orifice. Note the following measurements :

Length of the uterus (external measurement) :

In virgins . . . . . 6- 8 cm. ; weight, . . . . . 40 gm.

In married women . . 8-10 " " " " . . . . . 100 "

Width :

Of the fundus { in virgins . . . . . 4-5 cm.  
                  { in married women . . . . .  $5\frac{1}{2}$ - $6\frac{1}{2}$  "

Of the neck . . . . . 2- $2\frac{1}{2}$  "

Thickness { in virgins . . . . . 2-3 "  
              { in married women . . . . . 3- $3\frac{1}{2}$  "

Length of uterine cavity :

|  | <i>Entire.</i> | <i>Body.</i> | <i>Neck.</i> |
|--|----------------|--------------|--------------|
| In the immature uterus . . . . .             | 2.6            | 0.8          | 1.8          |
| In the mature virginal uterus . . . . .      | 5.4            | 3.2          | 2.2          |
| In the uterus that has been gravid . . . . . | 5.9            | 3.3          | 2.6          |

The corporeal secretion of the uterus is thick and oily ; the cervical, albuminoid or mucoid. Both are alkaline and contain mucin (coagulated by acetic acid).



The prolapsed mucous membrane of the vagina and vaginal cervix becomes either excoriated (Plates 8 and 10) or covered with a thickened layer of epithelium, the superficial strata of which are horny in character. (Plate 28, Fig. 2.) The lips of the cervix are everted. (Plates 10 and 12, Figs. 28 and 29.) The introitus vaginæ (about 1 or 2 cm. of the vagina) maintains its normal position, even in extreme cases, forming a swollen ring about the prolapsed tumor. The latter consists of the vagina and uterus, and contains diverticula from the bladder and rectum. (Plates 10 and 13.) The urine (or fecal matter) stagnates in these pouches, inducing catarrh and the formation of calculi; especially as the urethra is usually sharply bent upon itself. If the lower and posterior half of the bladder forms the diverticulum, the ureters are likewise bent at an acute angle and may give rise to hydronephrosis. (Plate 4, Fig. 3; Plate 5, Fig. 2; Plate 12.) Retroversion of the uterus acts as a predisposing cause for this condition of affairs (and for prolapse generally), especially when it is combined with laceration of the perineum (loss of support for vaginal wall) or descensus uteri. (Plate 4, Fig. 1; Plate 5, Fig. 1; Plate 13; Plate 19, Fig. 1.) Even the apex of the bladder and the vesico-uterine fold of peritoneum may be in the tumor. As the pouch of Douglas is in close contact with the posterior vaginal vault, it is likewise well down in the prolapse, and may accommodate a loop of intestine. (Plate 4, Fig. 4; Plate 13.)

**The development of the prolapse** is as follows: The anterior vaginal wall loses its normal support, either from perineal laceration (Plate 54) or from weakness of the pelvic floor. (Plates 6, 7, 25, 27.) The tuberculum vaginæ sinks down first, and remains between the nymphæ. Then the upper portion of the vagina begins not only to descend, but also to invaginate itself, as may be demonstrated every time the patient bears down. The cervix of the still normally anteverted uterus is drawn downward

and forward. (Plate 54, Figs. 2 and 3.) By this time the posterior vaginal wall commences to prolapse, making traction upon the posterior vaginal vault and, through it, upon the uterus. (Plate 54, 4.) This organ assumes first a vertical position, and then one of retroversion, its long axis running parallel with that of the vagina, which is now more vertical. At this time the slightest sudden pressure from above, a fall, or a series of similar factors acting in a like manner is sufficient to effect prolapse of the uterus. (Fig. 26.) The same pressure from above, together with the usually existing relaxed uterine wall, causes a bending of the body toward the cervix—retroflexio uteri. The relations of the bladder and peritoneal folds are shown in plates 4 and 5, and in figures 27 and 28.

If the prolapse is complete, the pressure acts still further, everting the cervical mucosa (in extreme cases as far as the internal os), which swells and becomes eroded. (Plates 8, 10 ; Fig. 28.) A lividity of the cervix results from the circulatory disturbances. (Plate 10.) In chronic cases this congestion leads to inflammation and proliferation ; giving rise not only to polyps of the mucous membrane, but also to secondary enlargements and elongations of the uterine neck—elongatio colli. (Plates 4, 5, and 12 ; Fig. 25.)

The body of the uterus takes little part in the process. The superficial epithelial layer becomes horny. (Plate 28, 2.) The muscular coat of the vagina becomes thickened, and the adipose tissue disappears.

**Symptoms.**—When the patient stands or walks, she feels as though the descending organ would fall out ; if the prolapse is complete, it impedes her movements ; it becomes ulcerated and painful from rubbing—the same is true of the thigh. The vaginal and cervical mucosæ become inflamed, not only secreting mucopus, but causing profuse and painful menses. The prolapsed parts are much enlarged—at first from stasis, later from prolifera-

## PLATE 6.

**Inversion of the Posterior Vaginal Wall.** Leukorrhea; intact perineum. (Original water-color.)

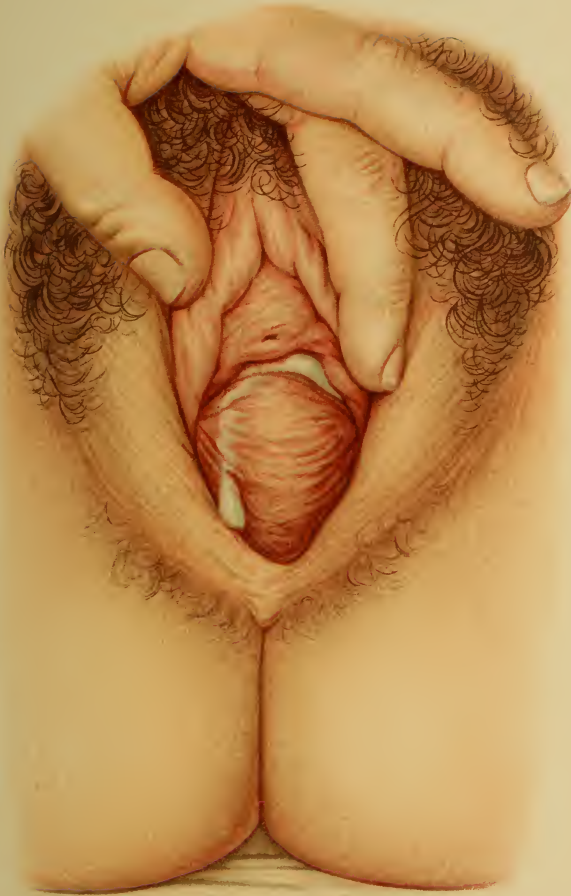---

tion of the connective tissue. (Chronic Metritis, Plates 28 and 32.) The dragging upon the adnexa calls forth nervous and dyspeptic symptoms. Defecation and urination are interfered with from secondary retention. Aside from its subjective discomfort, secondary inflammation of the peritoneum, by encapsulating the tubes and ovaries in exudate, leads to sterility. Structural changes in the uterine mucosa and the difficulties attendant upon cohabitation and upon retention of the semen are productive of the same result. The organs become fixed in their abnormal position.

**Etiology.**—Congenital prolapse of the uterus is one of the greatest rarities. I found such a case in a child with hydromeningocele at the Munich Frauenklinik (Fig. 25); I saw a second in the Heidelberg Frauenklinik in 1894.<sup>1</sup> It is also a rare condition in the virgin, being here caused by heavy lifting. The most frequent causes are found in puerperal injuries and too early attempts at straining, since at this time the uterus already has a tendency to assume or maintain a retrodeviation. Severe labors (forceps) lead to perineal lacerations and to stretching and relaxation of the genital walls and suspensory apparatus. (See explanations of Plates 13, 17, and 54; also p. 57.)

Retroversion of the uterus is easily produced by puerperal subinvolution with a relaxed vagina, chronic inflammatory conditions, frequent labors in delicate women, and tumors that force the uterus downward. Immediately after every normal labor the anterior lip of the cervix may be palpated, just within the introitus vaginæ.

<sup>1</sup> Described in "Arch. f. Gyn." by Dr. Heil. At that time I knew of only a third similar case (Qviesling, "C. f. Gyn.," 1890); since then several have been published.







**Prognosis.**—The danger of acute gangrene from constriction is a remote one. The condition is weakening from all the preceding manifestations. The excoriations predispose to epithelioma (v. Winckel).

**Diagnosis.**—In many patients the prolapse recedes when they lie down or remain quiet; but any increase of the intra-abdominal tension (coughing, lifting, straining at stool) causes it to descend, or to protrude from the vulva.

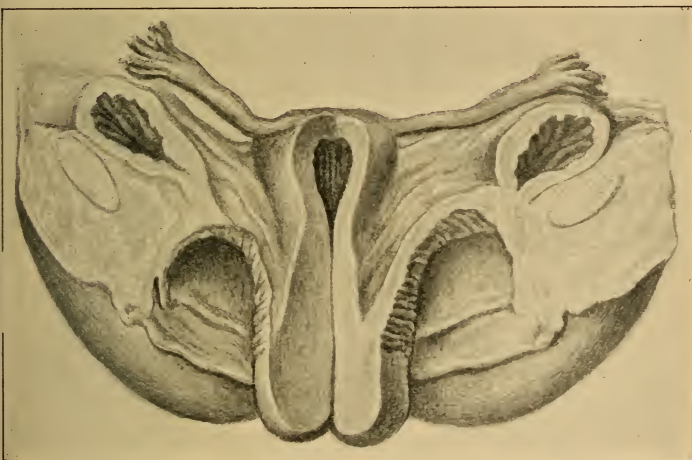


Fig. 25.—Congenital incomplete prolapse of the uterus from a mature fetus with hydromeningocele (Munich Frauenklinik, 1889; "Arch. f. Gyn.," 37, 2). Hypertrophy of the middle portion of the neck; inversion of the vaginal vault; marked development of the ovarian arteries, with iliac arteries of small lumen. The os is notched, and a slight ectropion is present.

The exact contents of the prolapse must be determined. Does it contain the uterus? How much of the vagina? Are vesical or rectal diverticula present? A number of conclusions may be drawn from inspection. (Figs. 26 to 29; Plates 8 to 10.) The external os, the cervical canal, and the length of the uninverted portion of the vagina are recognized by exploration with the finger and sound.

## PLATE 7.

FIG. 1.—**Inversion of the vagina from a perineal tear of the third degree** (into the rectum); the tuberculum vaginæ has descended. (Original water-color.)

FIG. 2.—**View of the Cervix in a Case of Elevation of the Uterus.** The cervix does not present itself as a free projection into the vagina, but forms the apex of the vaginal funnel. The oval external os gapes slightly.

---

Palpation from the rectum demonstrates the existence of a proctoceles and, in doubtful cases, the absence of the uterus from its usual position. The direction taken by the vesical diverticulum is shown by the catheter.

If the uterus is completely prolapsed, it may be grasped outside of the vulva, and a retroflexed (common), ante-flexed, or vertical position may be recognized. (Figs. 26 to 29.)

In an incomplete prolapse the differential diagnosis from **cervical hypertrophy** must be made. The distance from the external to the internal os is to be measured with the graduated sound (the normal uterus has a cervical canal 6 cm. long). The internal os is recognized by the resistance that it offers to the passage of the knobbed tip of the sound. The distance that the anterior and posterior vaginal vaults extend above the external os is also to be determined. (Plates 12 and 15.)

Finally, it must be ascertained whether the uterus is freely movable in its hernial sac, or adherent to its adnexa and to the descended coils of intestine.

**Treatment.—Prophylactic.**—Perineal lacerations are to be repaired at once. If the puerperal uterus is inclined to retrodeviation, keep the patient on her side as much as possible. She should never get up before from the tenth to the fourteenth day, and if the foregoing predisposing causes of prolapse exist, she should be kept in bed for two or three weeks, and then forbidden to lift or to do hard



## GROUP I.

### ANOMALIES OF FORMATION AND ARRESTED DEVELOPMENT.

---

#### CHAPTER I.

##### FETAL ANOMALIES OF FORMATION.

The anomalies of formation of the female genitalia are, almost without exception, examples of arrested development. The differentiation of the Müllerian ducts is imperfect or does not occur—the customary fusion fails to take place, or the ducts unite to form a single tube of limited extent. Defects of the entire genital tract or of individual organs are thus explained, as are also the congenital atresias, fistulas, and partial or complete duplications of the genital tube (Kussmaul).

The following forms are of clinical importance :

##### § 1. APLASIA AND HYPOPLASIA OF THE FETAL RUDIMENTS.

1. Absence of the uterine appendages.
2. Absence of the uterus.
3. Absence of the entire genital tract, with or without—
4. Pseudohermaphroditism.
5. Uterus unicornis : *i. e.*, absence of a portion of one of the Müllerian ducts (Fallopian tube attached to the uterine portion of one Müllerian duct).

6. Atresias—which may be cord-like or diaphragmatic—in the cervix (corresponding to the internal or external os), in the vagina, hymen, or vulva.

7. Congenital rectovaginal or rectovulvar fistulas (atresia ani vaginalis or hymenalis, cloaca vaginalis, or fistula rectovestibularis).

8. Feminine epispadias and hypospadias.

**1 and 2. Total absence of the uterus and its appendages** is very rare, and usually is first discovered at puberty. Solid bundles of muscle-fibers pass up from

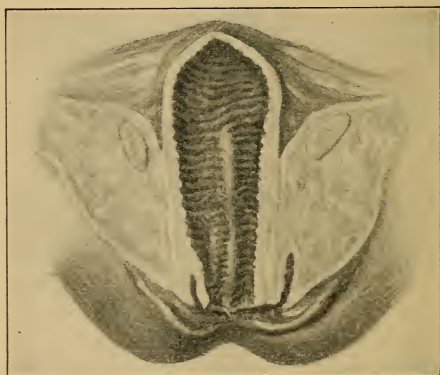


Fig. 1.—The fetal genitalia cut open in a median sagittal plane, so that the divided symphysis is thrown back on either side. Absence of the uterus (original drawing, from a preparation in the Munich Frauenklinik).

a rudimentary vagina and through the broad ligament, which can be recognized as a small transverse partition in the pelvis. The vulva is well developed, as a rule, the most striking external defects being a stunted clitoris, absence of the pubic hair, and smallness of the breasts.

The ovaries, on the contrary, are absent or but partially developed. The Fallopian tubes are patulous only in their ampullæ. In one case I found at autopsy <sup>1</sup> a

<sup>1</sup> In a fetus at the Munich Frauenklinik, "Arch. f. Gyn.," 37, 2.

total absence of the uterus and its appendages, with an elongated vagina. One portion of the fetal rudiments had formed this blind pouch, without any attempt at differentiation of a cervix. (See Fig. 1.)

**Symptoms.**—From the fact that the ovaries are absent it follows that the sexual instinct is usually wanting, although it may be present. The most striking symptom of all—nonappearance of the menses at puberty—may go hand in hand with the periodic appearance of the menstrual molimina.

Should such individuals indulge in sexual intercourse, new troubles arise from the forcible dilatation of the rudimentary vagina, or frequently of the urethra (incontinence of urine sometimes) (Plate 19, Fig. 2), especially since the latter often has a funnel shape, owing to a dropping back of the posterior wall.

**Diagnosis.**—Bimanual examination establishes the absence of the uterus. (Plate 19, Fig. 2; Plate 21, Fig. 2.) The finger is introduced into the rudimentary vagina or rectum, and counterpressure is made either through the abdominal wall or by introducing a sound or the finger into the bladder after dilatation of the urethra, or by tamponade of the vagina. The uterus and adnexa are to be sought for above the vaginal rudiment. Their recognition is by no means easy.

**3 and 4. Absence of the entire genital tract** renders the individual sexless, and may exist without any other malformation sufficient to endanger life. The vulva may be entirely wanting or it may be well developed. In a case that I saw the latter condition obtained, together with a hymen so yielding that it could be pushed in for several centimeters. The individual was subsequently married to her lover, who was fully cognizant of her genital peculiarities.

The clitoris may be robust; the labia majora may be fused, forming a median raphe; the nymphæ may be deformed; and the genital fissure may be closed or so short-

ened that the case assumes a pseudohermaphroditic character. In this event a careful examination will reveal genital glands in the labia majora; in fact, the labia majora not only resemble the scrotum, but may contain testicles.

This condition is known as **pseudohermaphroditism**.<sup>1</sup> If testicles and ovaries are found in the same case, we call the individual a true hermaphrodite. No such case has been established beyond a doubt. Most pseudohermaphrodites have proved themselves to be males, and some of them are capable of procreation, the latter being especially true when the genital eminence is well developed and the catheter demonstrates a culdesac in the posterior urethral wall. Female pseudohermaphroditism is always associated with vaginal atresia.

**Treatment.**—When the uterus does not exist, the attempt to make an artificial vagina is aimless and futile. In such a case it is the duty of the physician to explain the condition of affairs to the patient and to treat the menstrual molimina symptomatically (narcotics and external derivatives, oophorin tablets, castration). In cases of hermaphroditism the predominant sexual type should be determined as accurately as possible, since it has frequently happened that the conjugal relation has been assumed and the individual has first become conscious of his or her true sex during married life.

**5. Uterus Unicornis.**—It sometimes happens that one Müllerian duct remains rudimentary or imperfectly differentiated into its corresponding half of the uterus and appertinent tube. This half has a weaker muscular coat and the uterus is narrower, pointed, and possesses a horn curving toward the better-developed side. (Fig. 2.) The mildest degree of this condition is known as uterus inæ-

<sup>1</sup> The germinal glands are mostly rudimentary; the other sexual attributes are those of the opposite sex. Gynandres: marked degree of male hypospadias, including scrotum; a stunted penis; testicle still in the abdominal cavity or inguinal canal. Viragines: adhesion of the labia, enlarged clitoris; menstrual hemorrhages.

qualis, and arises from arrested development of one side.<sup>1</sup> The outcome of pregnancy and labor in such a case is portrayed in the "Atlas of Obstetric Diagnosis and Treatment" (second edition, Munich). The tube and ovary may be absent on the rudimentary side, or there

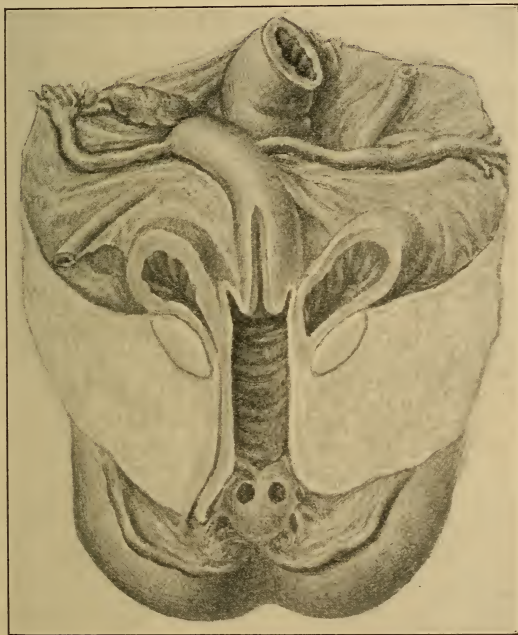


Fig. 2.—Uterus unicornis dexter; left half developed only as an elongated tube. Hymen septus (prepared as in Fig. 1).

may be a longer, undifferentiated tube, which is either solid or partly patulous. In such cases the extra-uterine

<sup>1</sup> In two fetal cases I found that the round ligament was not inserted into the angle between the uterus and the tube, but radiated toward the latter. The broad ligaments and tubes of the two sides were of unequal length.



transmigration of spermatic filaments or ova has been known to occur.

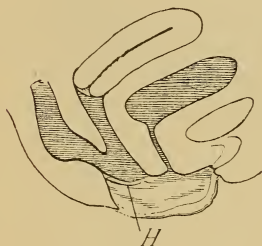
The early diagnosis of pregnancy is of great importance, because the rudimentary horn usually ruptures or a false diagnosis of extra-uterine pregnancy may be made.

**6, 7, and 8. Atresias** may be found in any portion of the genital apparatus. These may be explained in various ways :

(a) They represent an arrested development in early embryonic life, when the Müllerian ducts are simply solid columns of cells. Such atresias are usually cord-like and affect a considerable portion of the duct. (See obliterated vagina, Plate 19, Fig. 2.)

(b) The retarded development may occur a little later, —from the fourth to the sixth week,—and certain invaginations or openings of one hollow viscus into another do not occur, resulting in **atresia vulvæ**, **atresia ani**, or **atresia urethræ**.

Fig. 3.—Atresia ani ; congenital recto vaginal fistula (above the hymen).



These malformations may occur alone or in combination with other developmental errors, such as a persistent cloaca : *i. e.*, that embryonic cavity that connects the bladder with the rectum and is closed externally. (Fig. 12.) The external opening first appears when the rectovesical septum, containing the Müllerian ducts, grows down and forms the perineum. (Figs. 12 to 16.) Certain atresias combined with **congenital fistulas** may be traced back to this embryonic period—atresia ani with a rectovaginal fistula = **atresia ani vaginalis**. (Fig. 3.)

Imperfect closure of the primitive urethra toward the vagina gives rise to the rare condition known as **feminine hypospadias** (to be explained on etiologic and ana-



tomic grounds different from those of a similar condition in the male). Imperfect closure toward the clitoris—**feminine epispadias**—is still rarer, and is usually associated with a fissured clitoris, a cleft symphysis (pelvis fissa), and *inversio* (ectopia) vesicæ: *i. e.*, absence of the anterior wall of the bladder, the posterior wall being plainly visible.

(c) The **fistula rectohymenalis** or **rectovestibularis** (Fig. 6) springs from a later period of the embryonic cycle, and differs from the rectovaginal fistula in that the opening is in the vulva, outside of the hymen. It dates from the formation of the perineum (consequently, later than the cloaca), which is formed by the union of the septum urogenito-

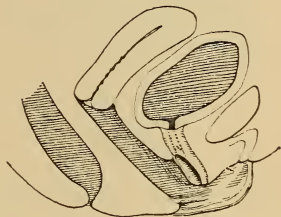


Fig. 4.—Hypospadias; posterior wall of urethra is wanting.

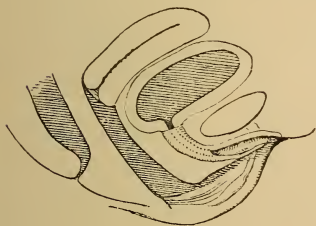


Fig. 5.—Epispadias; anterior wall of urethra is wanting; clitoris fissa.

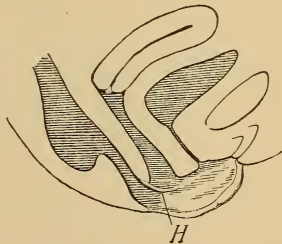


Fig. 6.—Rectovestibular or rectohymenal fistula with congenital atresia ani.

rectale with two lateral eminences, which have grown down and fused by a perineal raphe. (Figs. 14 to 16.)

(d) A fourth group of atresias originates in this fetal period, or at a much later one, in the shape of inflamma-

tory adhesions. These are much more likely to assume a diaphragmatic character. Examples of these are seen in atresias of the vulva and of the hymen and in closure of

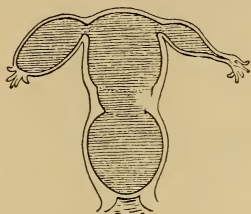


Fig. 7.—Atresia hymenalis, hematocolpos, hematometra, and hematosalpinx (both the internal and the external os may be recognized).

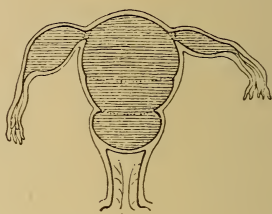


Fig. 8.—Atresia vaginalis from a transverse membrane (both the internal and the external os may be recognized). Partial hematocolpos, hematometra, partial hematosalpinx of both sides.

the vagina, of the cervix, and of the uterine orifices by transverse bridges of mucous membrane. Atresias may

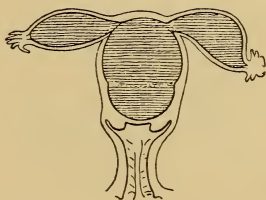


Fig. 9.—Atresia cervicalis uteri. Hematometra, hematosalpinx (internal os may be recognized; external os free).

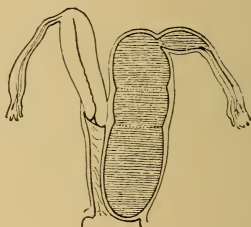


Fig. 10.—Atresia vaginalis with uterus and vagina duplex; left-sided partial hematocolpos, hematometra, hematosalpinx (both the internal and the external os may be recognized).

also be encountered in cases of uterus bicornis. (Figs. 7 to 11.)

**Symptoms.**—The symptoms of the genital atresias vary, and appear at different periods of life, according to their nature. Every new-born child should be carefully examined as to the permeability of the urethra and anus. This is frequently neglected, and anal atresia, or even complete closure of the urethra, is discovered only after days, either by accident or through symptoms of retention.

The hymen also deserves attention, for although atresia in this situation is usually first discovered at puberty, there are recorded cases in which the menses had never

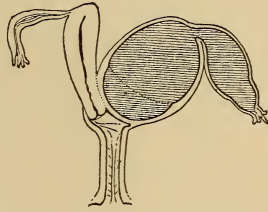


Fig. 11.—Atresia of the external orifice of a bicornate uterus; left-sided hematometra, hematosalpinx.

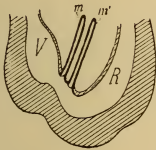


Fig. 12.—For the sake of simplicity, the two Müllerian ducts are drawn one behind the other, instead of side by side. They empty into the cloaca, which connects the bladder (allantois, *V*) and the rectum (*R*), and which has no external opening. A slight invagination indicates the position of the future anus, and a similar one, the urogenital sinus.

appeared, owing to the presence of this anomaly, and yet the condition remained unrecognized until the patient assumed the marital relation. The cardinal symptom of all genital atresias, with the exception of those cases of uterus bicornis in which one side is patulous, is nonappearance of the menses. Increasing distention of the genital tract by mucus and by menstrual blood is the cause of the earliest disturbances. According to the location of the atresia, we have a hematocolpos, a hematometra, or a hematosalpinx.

The symptoms are as follows: Pain, at first periodic

and then continuous, with exacerbations similar to the pains of labor; vesical and rectal disturbances; indigestion and vomiting, due to the pressure of the accumulated blood. Hematosalpinx occurs in uterine atresias earlier than in those of the vagina. (Plate 40, Fig. 2.)

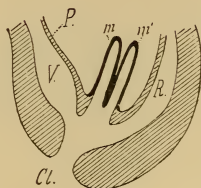


Fig. 13.—The Müllerian ducts are of larger lumen, and have descended with the rectovesical septum to empty into the open cloaca (*P* = peritoneum).

It is dangerous on account of the ease with which the tubal wall may be torn, and consequently the examination should be conducted with great gentleness. The peritoneum is frequently subjected to inflammatory irritation by the escape of small quantities of blood from the tubal ostia. The same dangers exist in collections of blood in closed rudimentary cornua.

In unilateral atresia of a double genital canal (uterus septus cum vagina septa) we have less to fear, as the hematoma is more likely to rupture into the patulous side. (Figs. 10 and 11.) The bloody tumor may undergo putrefactive or suppurative changes. When only one genital canal exists, rupture commonly occurs through a thinned-out portion of the cervix. The blood may escape into the peritoneal cavity (peritonitis) or beneath the peritoneum, extending down around the vagina to the floor of the pelvis—hæmatoma vulvæ or vaginæ.

Hematosalpinx occurs in uterine atresias earlier than in those of the vagina. (Plate 40, Fig. 2.) It is dangerous on account of the ease with which the tubal wall may be torn, and consequently the examination should be conducted with great gentleness. The peritoneum is

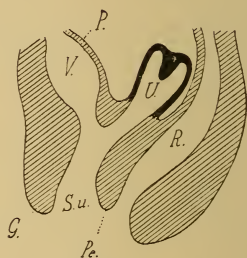


Fig. 14.—The two Müllerian ducts have fused to form the uterus (*U*); a septum still exists in the fundus. The sinus urogenitalis is longer (*S. u.*). *G* = genital eminence = future clitoris; *Pe* = perineum. The urethra opens high up, and is still more marked than the genital canal.

In atresia ani vaginalis the feces escape through the vagina. (Fig. 3.) If the closure is sphincter-like, a periodic discharge of gas and feces occurs. When

the opening is high up in the vagina, retention is impossible despite the strictest cleanliness. If the opening is small or the intestine is bent at an acute angle, inflammatory and obstructive symptoms may manifest themselves. The same is true, *mutatis mutandis*, of atresia ani vestibularis (Fig. 6) and anus perinealis. Complete absence of perineum may also be observed from failure of fusion of

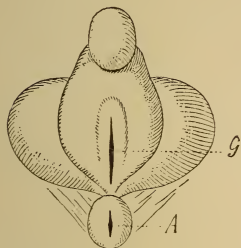


Fig. 15.—External genitalia of figures 14 and 16. Behind the relatively important genital eminence (clitoris) the opening of the sinus urogenitalis (*G*) is seen, and posterior to this, the anus (*A*).

the lateral eminences. Incontinence of urine exists with the more marked degrees of hypospadias, and especially with epispadias. (Figs. 4 and 5.)

**Diagnosis.**—Persistent nonappearance of the menses always demands an ocular inspection of the parts. When vaginal or hymenal atresia exists, the bluish protruding membrane is seen, while cervical atresia renders the passage of the uterine sound impossible. Should the closure be at the internal os, the cervix alone is patulous; if at the external os, it is impervious. In unilateral atresia of duplicate genitalia one side will not permit the introduction of a sound.

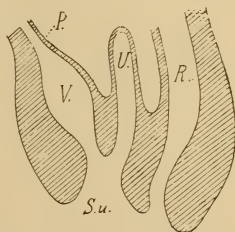


Fig. 16.—Further descent of the urogenital septum, thereby shortening the sinus urogenitalis (*S. u.*).



Palpation completes the diagnosis. The finger is introduced into the rectum, and a firm elastic tumor is felt anteriorly, above which the uterus is recognized as a small hard body. If the distention is more marked, the uterus assumes an hour-glass shape, in consequence of the resistance of the internal os. The tubes should be sought for, exercising great care and gentleness. (Figs. 7 to 11.)

Cord-like atresia of the vagina is recognized by bi-manual palpation through the rectum. (Plate 19, Fig. 2.)

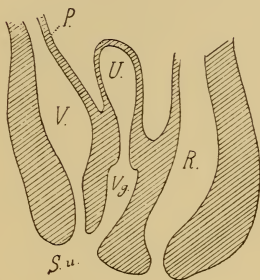


Fig. 17.—During the fifth fetal month the cervix (both vaginal and supravaginal) is differentiated from the vagina (*Vg.*). The urethra is also to be distinguished from the bladder. The vesicovaginal septum assists in the formation of the vestibule.

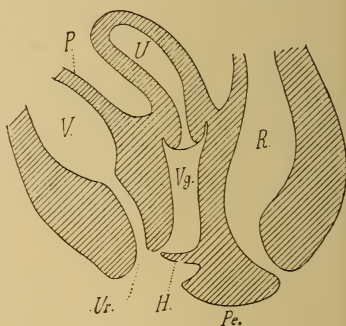


Fig. 18.—Scheme of the completed genitalia after the formation of the hymen.

**Treatment.**—The gynatretic membrane should be incised without delay, and the blood should be *slowly* drained off. Collapse has followed when the latter caution has not been observed. If a tubal sac has ruptured, immediate celiotomy and removal of the blood are indicated. Abdominal section is also demanded when the hematometra is in a rudimentary accessory cornu. If uterus bilocularis or vagina bilocularis (with a septum)



exists, it is better to excise the entire partition than simply to incise it.

Cases of pyocolpometra from secondary infection of the retained blood are treated in a similar manner, a drainage-tube being introduced and the cavity being washed out several times daily.

If there is a complete absence of the vagina (Plate 19, Fig. 2), its position being indicated by a fibrous cord, a new vagina must be made. Sounds are passed into the bladder and rectum, and the operator cautiously dissects up through the connective tissue. Skin-grafting should be employed to prevent a cicatricial closure of the newly formed tube. If adhesions occur in spite of this, or if, from the nature of the case, they are to be dreaded from the beginning, the ovaries should be removed by abdominal section and the uterus should be sutured into the vulvar wound, in order to prevent a subsequent hydrometra.

Congenital defects of the perineum and epispadias and hypospadias are to be repaired by plastic operations. In atresia ani vaginalis the rectum is brought down through the perineum as far as possible, and is connected with an artificial perineal anus. The fistula then closes either spontaneously or after mild cauterizations.

## § 2. HYPERPLASTIC ANOMALIES OF FORMATION.

### 1. Duplication of Entire Organs.—

#### (a) Of the whole genital tract:

*a.* Uterus didelphys: *i. e.*, uterus and vagina grow as the two Müllerian ducts (Figs. 12 and 13), and remain without further differentiation as two solid cords or as two tubes;

*β.* Uterus et vagina duplex: *i. e.*, two genital tubes completely differentiated into uteri and vaginæ. These lie side by side and each possesses a tube and an ovary.

Both these malformations are seen only in those monsters incapable of independent life. At the Munich Frauenklinik I observed two examples of type *a*, with ectopia viscerum, total absence of bladder and kidneys, persistent cloaca. etc.; and one of type *β*, with eventration of all the intestines in an umbilical hernia and with atresia ani.

Duplication of the vulva is sometimes seen, but has no clinical significance. ("Arch. f. Gyn.," 37, 2.)

- (b) **Of the uterine appendages:** ovaries, tubal ostia—arising from a division of the Müllerian ducts.
- (c) **Of the uterus:** bicornis. (Plate 2, Figs. 2 and 19.)  
Those portions of the Müllerian ducts that should form

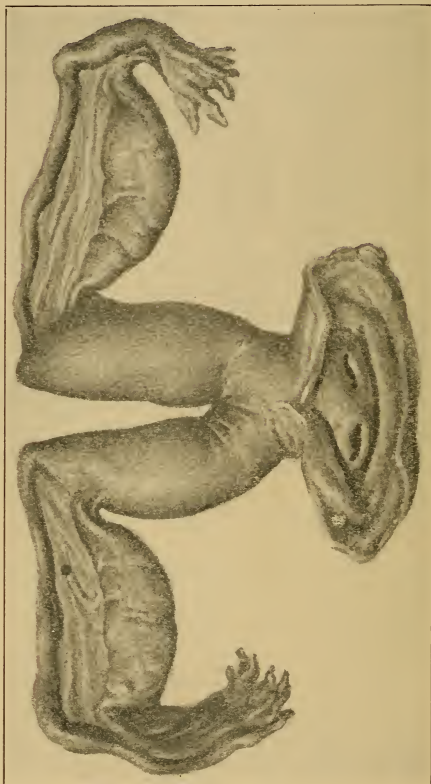


Fig. 19.—Uterus bicornis bicollis with vagina simplex (specimen from Heidelberg Frauenklinik).

the body of the uterus do not fuse, but develop separately, remaining attached to a common neck. This malformation may be associated with the one to be described presently.

In the mildest degree of duplication of the uterus the fundus simply shows a depression—uterus introrsum arcuatus.

2. **Duplication by a Septum.**—The Müllerian ducts fuse, but the partition dividing them does not disappear.

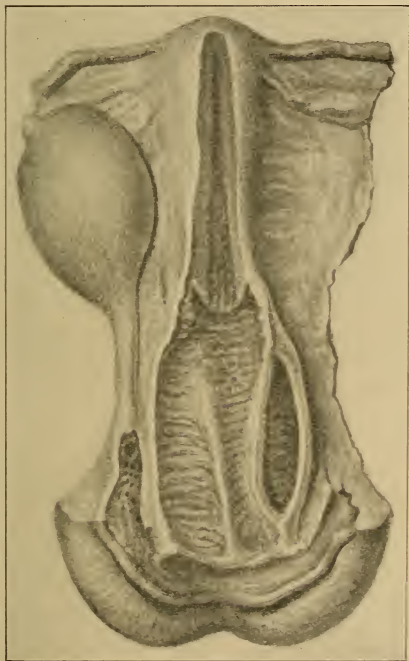


Fig. 20.—Vagina septa with atresia of one canal. Skene's glands empty into the urethral orifice (Munich Frauenklinik, "Arch. f. Gyn.," 37, 2).

(Figs. 10, 13, 14.) This disappearance usually begins in from the eighth to the twelfth week, commencing in that portion of the tube that subsequently (from the twentieth to the thirtieth week) forms the vaginal cervix. This

## PLATE 1.

**The Vulva of a Nonpregnant Multipara** (original water-color from a case at the Heidelberg Frauenklinik). The labia majora and minora are separated. In addition to the remains of the hymen, there is to be seen a congenital blind canal, about 1 cm. in depth, at the posterior commissure. The author has repeatedly found analogous structures in the fetus (see Plate VII, Fig. 19, of the "*Arch. f. Gyn.*," 37, 2), as well as cysts of the hymen in the same situation. The perineum is intact.

## PLATE 2.

**FIG. 1.—Intravaginal Cervix of an "Infantile" Uterus.** In these and the following analogous illustrations the parts are brought into view by Sims' or Simon's specula, the patient being in the dorsal position. The labia are held apart, and the furrowed vaginal wall is forced back, so that the cervix presents itself in the depth of the vaginal funnel.

The Sims position is the one best adapted for the physician without assistance, because then it is necessary to introduce the posterior speculum only, the anterior vaginal wall falling back of its own accord. The upper half of the body rests upon the left shoulder and breast; the left arm lies upon the table, parallel to the body, and can hold the speculum if necessary. The left thigh is almost completely extended; the right is strongly flexed on the abdomen. The physician stands behind the patient.

The illustration represents the pale, small cervix of a deficiently developed uterus, often combined with congenital stenosis of the cervical canal and puerile ante flexion of the uterus. (See § 3, 1-4, and Fig. 22 in text.)

**FIG. 2.—Duplication of Cervix in a Case of Uterus Bicornis Septus with a Single Vagina.** In the embryo the Müllerian ducts do not lie quite symmetrically side by side, but the right one is nearer to the symphysis. This asymmetry may be recognized in the illustration, from the relation of the two external orifices to each other. (Figs. 10-21 in text and § 2.) Where the uterus is duplicated, two cervixes may present themselves in the vagina, which is usually divided by a septum. Uterus subseptus may exist with only a single external os.

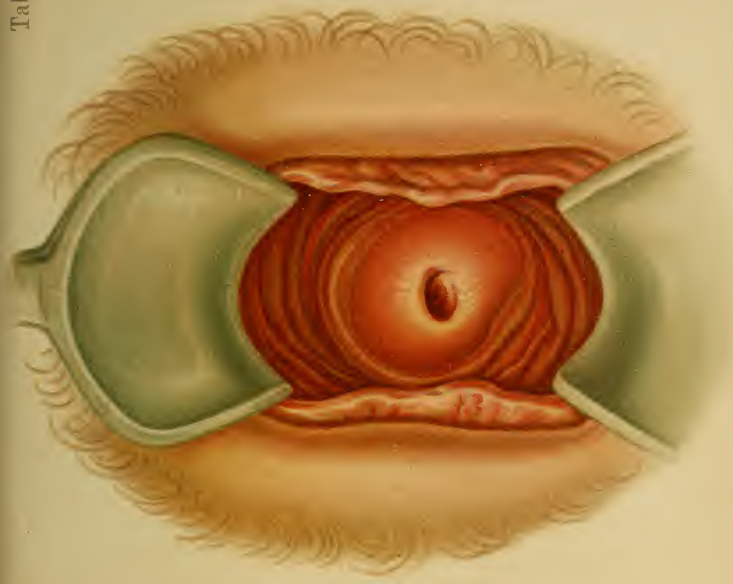


Fig. 2. *Lip. Inc. P. Reichhold Munchen.*

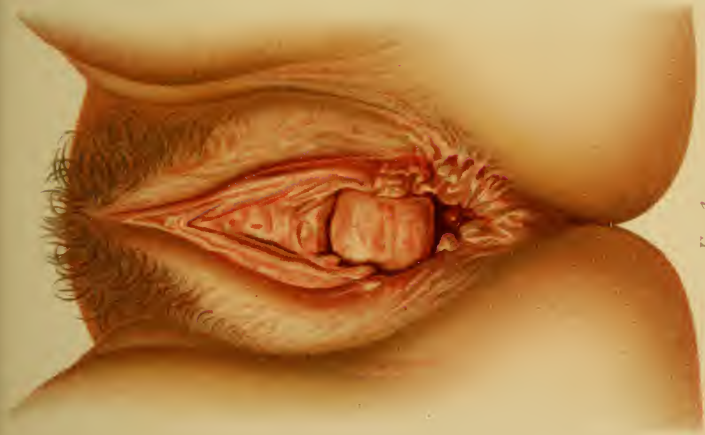

Fig. 1.





work for some time. When the genitalia are relaxed and the vagina threatens to invert, support the perineum with a T-bandage; on the eighth day of the puerperium a pessary may be introduced. Catarrh, constipation, and tumors are to be appropriately treated.

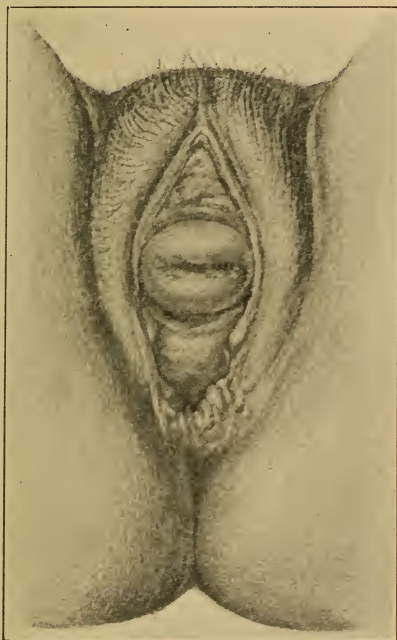


Fig. 26.—Incomplete prolapse of the uterus; inversion of the vagina from perineal tear of the third degree (into the rectum). The os is notched (photograph from original water-color).

If the prolapse is beyond the preventive stage, an apparently rational therapy—from our knowledge of the supports of the internal genitalia (based upon the author's experiments and those of Kimmel<sup>1</sup>)—would be the

<sup>1</sup> Kimmel, Inaug. Dis., 1894, Heidelberg.

strengthening of the muscles of the pelvic floor by massage. This has, nevertheless, been followed by but few permanent results. At the present time it is better to treat these cases with the pessary or by operation.

The **operative treatment** is radical and sure. In retro-deviations the uterus is brought forward into its normal

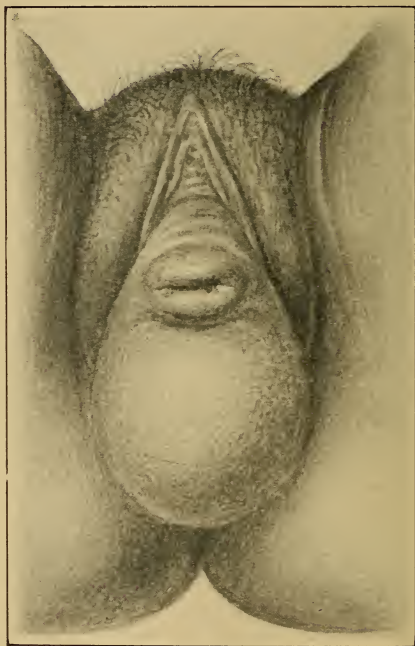


Fig. 27.—Complete prolapse of a retroflexed uterus, with rectocele. The os is notched (photograph from original water-color).

position by retrofixatio colli uteri, with or without opening of the recto-uterine pouch; by shortening the round ligaments, either in the inguinal canal or after an anterior colpotomy. By the latter route the broad ligaments may be shortened or a thickened uterus may be anteflexed by

excision of a wedge-shaped piece from its anterior wall. After the menopause the uterus may be separated from the bladder and stitched to the vagina or bladder (*vaginofixation* or *vesicofixation* of Dührssen, Mackenrodt). If the organ is held by strong adhesions, or if the ligaments and

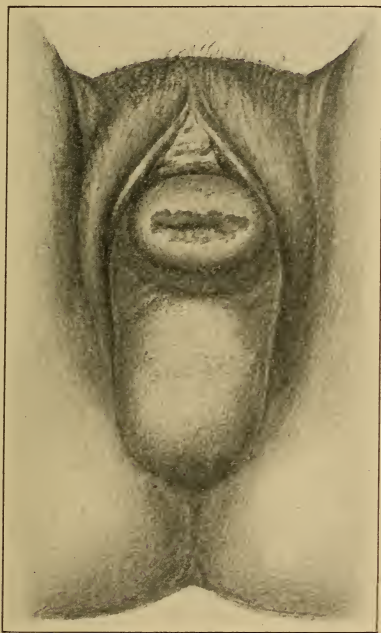


Fig. 28.—Complete prolapse of a retroflexed uterus; simple erosion, without rectocele. (See Fig. 27.) (Photograph from original water-color.)

vaginal walls are greatly relaxed, *ventrofixation* should be performed; the best method is that of Czerny-Leopold, which consists in stitching the uterine serosa (Sänger stitches the round or broad ligament) directly to the parietal peritoneum of the abdominal wall.

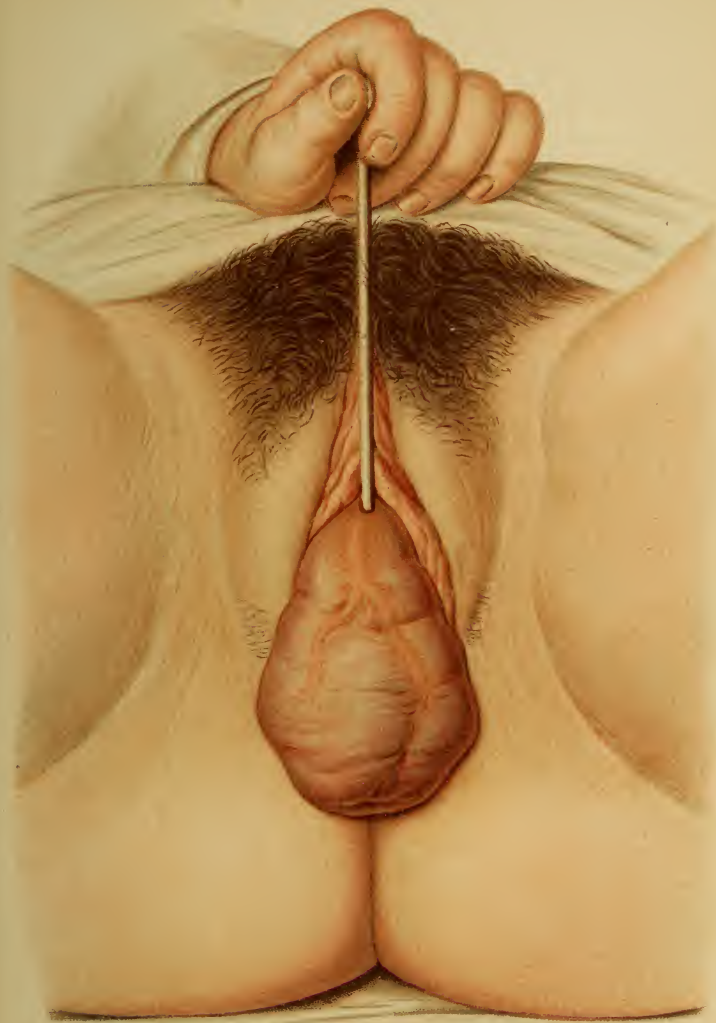## PLATE 8.

**Complete Prolapse of an Anteфлекed Uterus; Cystocele.**

Ascertained by the introduction of the sound into the diverticulum (note direction of sound ; latter held like a pen). Excoriation of the inverted mucous membrane. (Original water-color.)

---

Retention is secured by narrowing the vagina and repairing the perineum ; *anterior colporrhaphy* of Sims, in cystocele, by excising a portion of the mucous membrane (shaped like a myrtle leaf) and bringing the edges of the wound together ; [An oval denudation (Martin), reaching from the meatus urinarius to the cervix, and closed by tier sutures of catgut, to narrow the vagina and to leave a firm support for the bladder, is the most popular method in America for repairing the anterior vaginal wall. Except where great elongation of the anterior vaginal wall has occurred, the purse-string operation of Stoltz has been discarded, because it necessarily shortens the anterior vaginal wall by approximating the meatus and cervix, and thus tends to retrovert the uterus.—ED.] *posterior colporrhaphy* of G. Simon, Hegar, Bischoff, Martin, v. Winckel, Fritsch, Neugebauer, Kehrler, either by excising a triangular piece of mucous membrane, the base corresponding to the perineum, or by excising pieces of irregular outline and removing so much of the lateral wall that the posterior wall is narrowed and the perineum raised. Posterior colporrhaphy is also combined with plastic operations on the perineum—*colpoperineauxesis* (Hegar, Kaltenbach) or *colpoperineoplasty* (Bischoff). [The anatomic and physiologic principles embraced by Emmet's colpoperineorrhaphy have been so thoroughly appreciated by American surgeons that Emmet's operation is usually chosen to the exclusion of all others.—ED.] These operations should be most carefully planned and carried out. The portions to be excised are first outlined, then removed, the edges of the







wound freely loosened up, and the sutures accurately placed.

Considerable experience is necessary to enable the operator to remove neither too much nor too little tissue. When the operation is completed, the vulva should not gape, and the vaginal walls should be well supported by

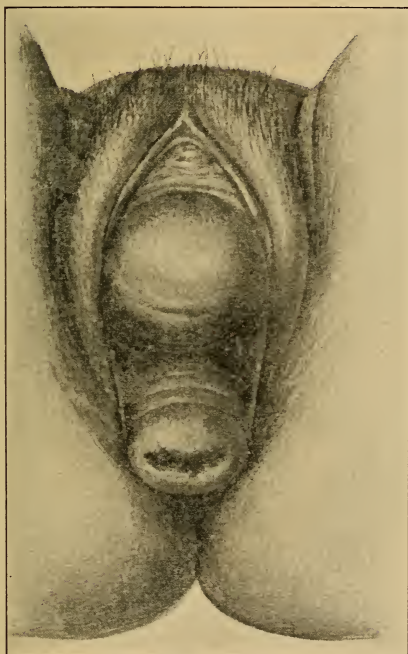


Fig. 29.—Complete prolapse of an anteflexed uterus; simple erosion.  
(See Plate 28.) (Photograph from original water-color.)

the new perineum. Buried catgut or fine silk may be used as suture material in the vagina; in the perineum, silkworm gut or silver wire is to be employed.

If an ectropion or an ulceration exists, the incision may be made to include this portion of the cervix. Not only

## PLATE 9.

**Extreme Inversion of the Vagina, with Cystocele and Incomplete Prolapse of the Retroverted Uterus.** (Original water-color.) Density of the mucous membrane. Thickening of the vessels.

---

superficial parts of the mucous membrane, but also extensive wedges of muscular tissue (see Metritis), or conic pieces of the hypertrophied cervix, may be excised, and deep sutures of silk or silkworm gut may then be inserted.

The preparation of the patient and the after-treatment must receive as much care as the operation. Before the operation, laxatives, vagina well scrubbed out with antiseptics (three times, including the cervical mucosa), and the prolapse returned, are measures to be employed because the parts are then less vascular. After the operation, three weeks in bed ; in the first days, liquid diet and a few drops of laudanum ; removal of the perineal stitches at the end of the first week ; if nonabsorbable sutures have been used in the vagina, they are taken out later. Vaginal irrigation, if discharge is fetid ; laxatives, to avoid tension on the sutures.

If the uterus is so strongly adherent to the hernial sac that its reposition is impossible or can not be borne (in spite of massage and stretching and tearing the pseudo-ligaments), and the subjective disturbances are great, nothing remains but total extirpation (Kehrer).

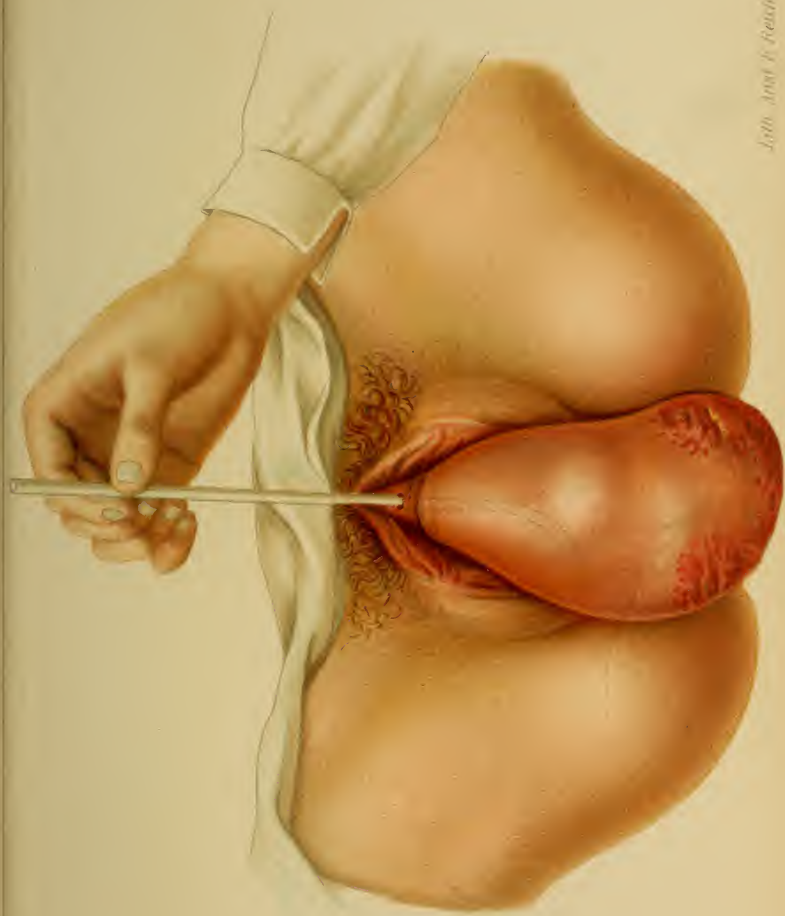If the operation is refused, **pessaries** and **rings** may be used for retentive purposes. Among these may be mentioned :

1. The round ring of Mayer (Plate 20, Fig. 3), when the lower part of the vagina is still narrow. It is harm-

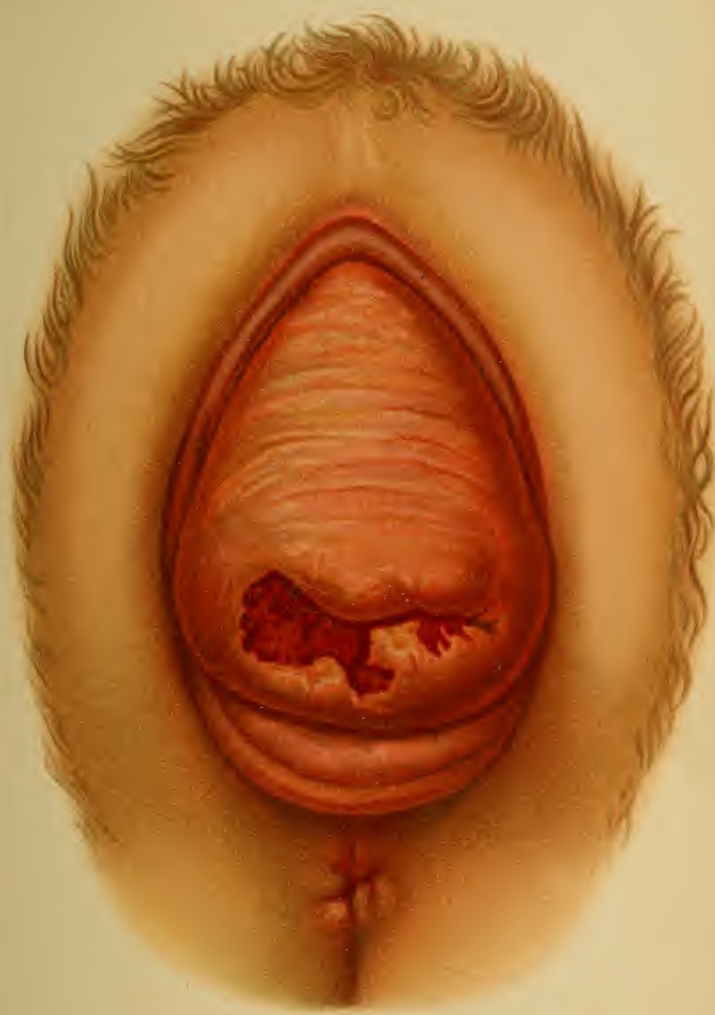---

## PLATE 10.

**Incomplete Prolapse of the Uterus ; Simple Erosion ; "Circular" Thickening of Cervix ; Rectocele.** (Original water-color from a case at the Heidelberg Frauenklinik.)











ful, inasmuch as it dilates the vagina. Those made of celluloid or hard rubber are better than the soft-rubber variety.

2. The B. S. Schultze sledge pessary (Figs. 32 and 33) corrects the retrodeviation of the uterus and allows a natural range of motion when the vagina is very large and relaxed. It is better for prolapsus than—

3. Schultze's 8-shaped pessary, which is so constructed that it is supported by the perineum. (Fig. 31.) It is of greatest utility when the introitus vaginæ is intact.

4. Hodge's lever pessary, especially applicable in inversion of the anterior vaginal wall (Plate 20, Fig. 4; Fig. 30), because it does not dilate the middle portion of the vagina, but puts it on the stretch.

5. The Zängerle-Martin stem-pessary (Plate 5, Fig. 3) rests upon the levator ani and is applicable in obstinately recurring prolapse, and roomy, relaxed genitalia. The old stemmed hysterophore is worthless, and is at best to be looked upon as a last resort, when the lower vagina is dilated.

The following two pessaries, on the contrary, are not sufficiently appreciated in practice :

6. Hewitt's cradle or clamp pessary (VI-shaped, a ring bent upon itself), and—

7. Breisky's egg-shaped pessary of hard rubber (especially Nos. 2 and 3), which are especially adapted to inoperable cases beyond the menopause. It is held in position by a T-bandage, and must be removed with forceps.

See Directions for the Application of Pessaries, §11.

The **reposition** of the prolapsed organ is accomplished with the patient in the dorsal position. The pressure upon the cervix acts in the direction of the vaginal axis, upward and backward, pushing back first the posterior vaginal wall, then the uterus, and lastly the anterior vaginal wall. Tampons (saturated in glycerin, renewed twice daily) retain the prolapse temporarily, the dorsal position being maintained. Breisky gave his patients a tampon-

## PLATE 11.

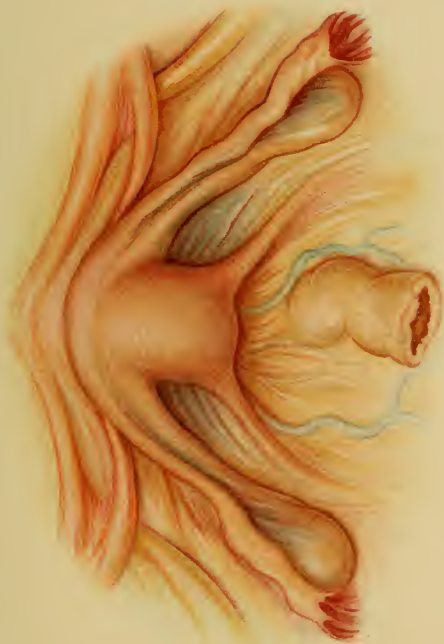**Anteflexion of the Uterus in a Child.** View of Douglas' pouch. (Original water-color, from cadaver.)

---

carrier, enabling them to introduce the tampons themselves.

As a supplement to the foregoing, **elevatio uteri** will now be considered. The uterus plays an entirely passive rôle in this change of position, as tumors of the organ itself, or of adjacent organs, or peritoneal residues, and pseudoligaments lift it wholly or partly above the pelvic inlet. (Plate 16, Fig. 1.)

The **diagnosis** and the **treatment** are the same as those of the causal affection. The former is often difficult, and as the condition is usually associated with structural changes, the organ becoming thinner and softer, the sound is to be used with caution. The uterus may be *pushed* up from below, or *drawn* up from above. The cervix often projects into the vagina as a mere cone. (Plate 7, Fig. 2.)





## CHAPTER III.

### THE PATHOLOGIC POSITIONS, VERSIONS, AND FLEXIONS OF THE UTERUS.

Pathologic positions are displacements of the uterus *in toto*, the individual portions of the same holding their normal mutual relations. They may be forward, backward, or to one side. Versions are turnings of the uterus, as a whole, about an imaginary axis passing through the internal os. This axis may have a transverse or a sagittal direction. In the condition known as a flexion, on the contrary, the body of the uterus forms an angle with the cervix. These three forms may be observed in combination with one another or with a "high position." (Compare with *Elevatio Uteri* on p. 72.) Three degrees are differentiated, dependent upon whether the fundus is above, at the same level with, or below the external os.

#### § 9. THE PATHOLOGIC POSITIONS OF THE UTERUS AND ITS ADNEXA.

The uterus as a whole may be displaced forward, backward, or to one side : antepositio, retropositio, and lateropositio (dextropositio and sinistropositio).

The displacement of the organ is a passive one, the most frequent cause being perimetritic or parametritic exudates. These may be either recent, tumor-like masses forcing the uterus away from them, or contracting bands of scar-like adhesions pulling the organ toward them. (Plates 44 and 45.) It can thus be seen that the uterus may be forced consecutively in two opposed directions at

## PLATE 12.

**Incomplete Prolapse of the Uterus ; Elongation of the Intermediate Portion of the Neck with "Circular" Hypertrophy of the Vaginal Portion ; Inversion of the Anterior Vaginal Wall ; Cystocele.** The posterior vaginal vault is almost at its normal height. (See Plate 4, Fig. 2.) (Original water-color from a specimen in the Munich Frauenklinik.)

---

different stages of the disease. (Plate 16, Figs. 1 and 2 ; Plate 17, Fig. 1 ; Plate 58, Fig. 2.)

Tumors act in the same manner. There may be tumors of the uterus itself (antepositio from a myoma of the posterior wall, Plate 58, 4), tumors of neighboring organs (Plate 59, 2 and 4, Ovarian Cystomata), or tumors of Douglas' pouch, especially those of the rectum and sacrum. Finally, excessive distention of adjacent organs may produce the same result. The bladder (Plate 17, 2, and Plate 14, 4), the rectum in cases of chronic constipation, and a pyosalpinx (Plate 59, 3) furnish examples.

A special variety of lateroposition is of a congenital and physiologic nature, brought about by unequal growth of the Müllerian ducts and their adnexa (tubes, ligamentum latum).<sup>1</sup> (See Fig. 2 in text.)

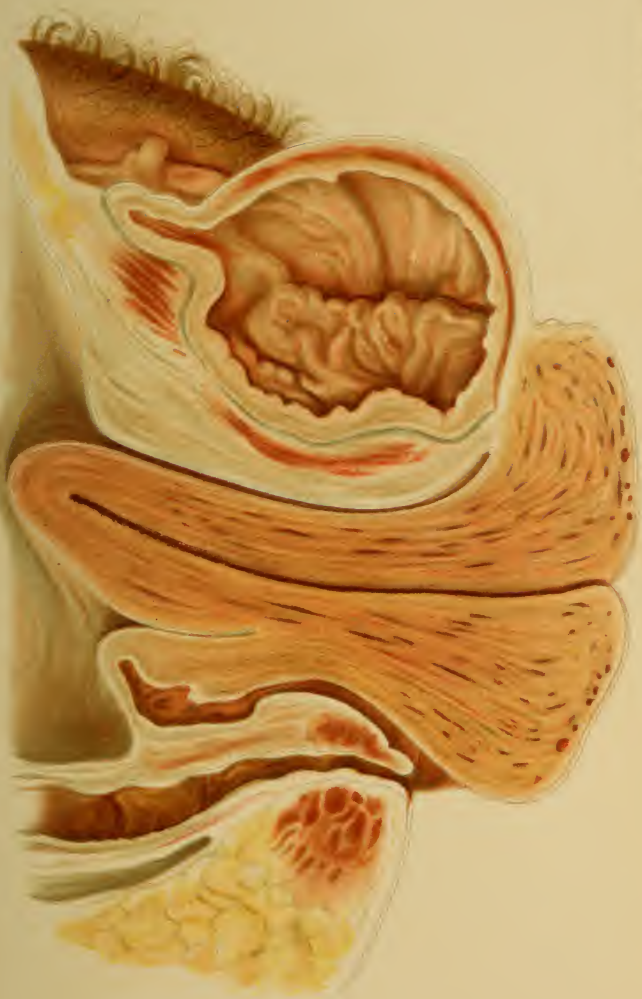---

## PLATE 13.

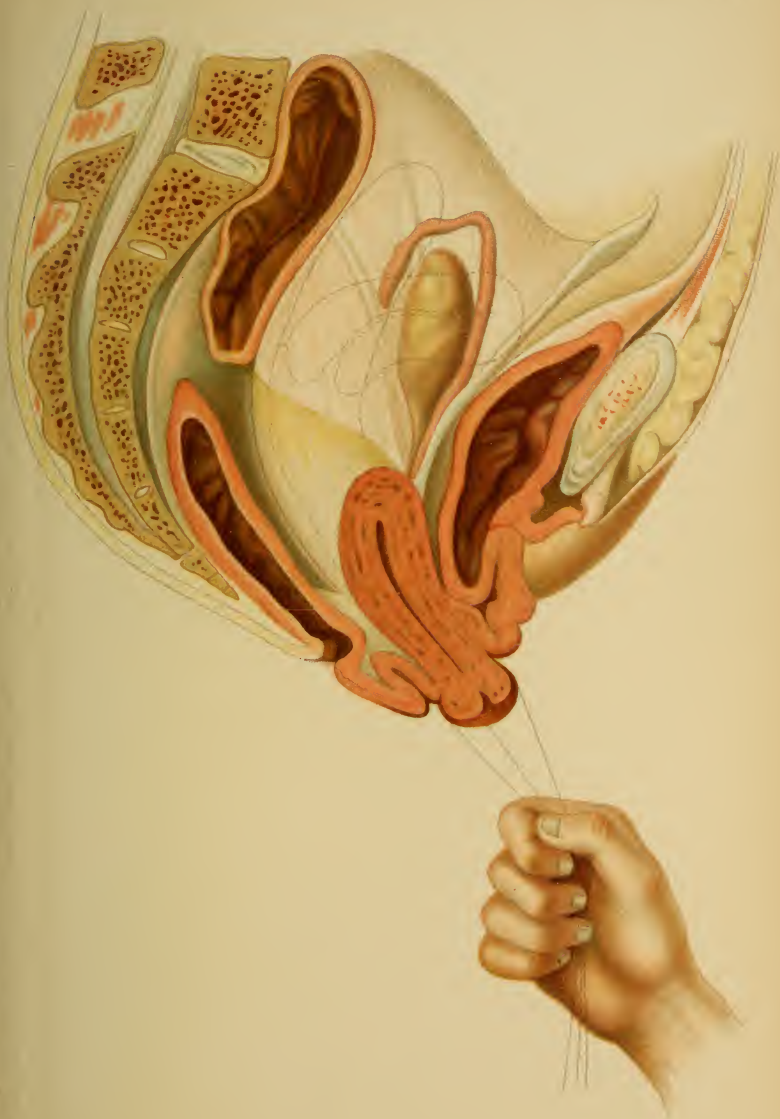**Artificial Prolapse for Operative Purposes, with the Arising Inversion of the Vagina and with Cystocele.** The uterus first assumes a position of retroversion. Further traction directs the organ downward in the direction of the vaginal axis (see the dotted lines, which show the normal position of the uterus at the beginning and its subsequent stages of transition). The pathologic process proceeds in the same way. (Original diagrammatic sketch making partial use of a drawing of Beigel's.)

<sup>1</sup> In 130 postmortem specimens of adult female genitalia, I found the adnexa of the right side longer in 31.5% ; of the left side, in 27%.











**Diagnosis.**—The presence or absence of a flexion is first determined bimanually, and then the cause of the displacement is ascertained. The changed position of the uterus is quite frequently combined with retroversion (Plate 17, 2), elevation (Plate 14, 4), or both (Plate 16, 1). Extra-uterine pregnancy must be excluded if tumors of the adnexa or of Douglas' pouch are present. The sound is to be employed only after the position of the body of the uterus has been accurately determined. It is clear from the foregoing that an exact differential diagnosis, especially of the tumors of Douglas' pouch (see p. 74), must be made. In uncomplicated changes of position both vaginal vaults retain their normal form and relations; the position of the vagina, on the contrary, is changed, its curve being lessened and its walls being placed under greater tension (anteriorly in antepositio).

The **treatment** consists in the removal of tumors and the extension of cicatricial bands by massage.

The **tubes and ovaries** are frequently displaced by inflammatory processes or through relaxation and congestion of their ligaments. The inflammatory virus (mostly gonococci, staphylococci, and streptococci) escapes from the abdominal ostium of the tube, and causes perimetritic, perisalpingitic, and perioophoritic exudations. Its contraction dislocates the movable adnexa, and agglutinates them with the intestine and with the serosa of Douglas' pouch. (Plates 44 and 45.) The process may cause the tubes to be bent at an acute angle. Ovariocolpocele and pyocolpocele have already been mentioned; they can, with or without the uterus, form the contents of almost any variety of abdominal hernia. (See § 6; § 7, *Inversio Uteri Pro lapsi*; Plate 3, Fig. 2.)

The ovaries usually change their position with the uterus, and consequently displacements (one side or both) in all directions are encountered. Descent of the ovary, combined with retroversion of the uterus, is the most fre-

quent one (Plate 19, Fig 1); the ovary may be palpated beneath the uterus. They may also be displaced by tumors that proceed from the ovary itself (with or without adhesion to adjacent viscera) or from neighboring organs. The normal position of the internal genitalia is described on page 57.

The **symptoms, diagnosis, and treatment** will be found in the chapter upon inflammation of these parts.

#### § 10. THE ANTEVERSIONS AND ANTEFLEXIONS OF THE UTERUS.

Every anteversion or anteflexion is not pathologic. By pathologic anteflexions are meant only those that are permanent, and that are commonly associated with a lessened mobility of the corpus uteri. This lessened mobility may refer to its position in the pelvis or to the relation that it holds to the cervix. The latter is designated as a "rigid" angle of flexion if it has arisen from an inflammatory proliferation of connective tissue in an abnormally flexible organ. This variety of anteflexion was described in § 3 (3 and 4) as that of infantile and puerile uteri.

**Etiology.**—With the exception of the abnormally flexible infantile form, there is always some cause for the displacement outside of the uterus.

1. Cord-like residues of parametritic or perimetritic exudates are most common causes. The latter may either bind the corpus uteri down to the bladder or to the anterior pelvic wall (Plate 14, Fig. 4), or may fix the neck posteriorly (this being more frequent). Anteflexion results if traction is made upon a still flexible uterus by an adhesion of the posterior wall corresponding in position to that of the internal os. (Plate 15, Fig. 1.) It also follows fixation of the neck anteriorly, as shown in plate 15, figure 2; this is a rare occurrence, however.

2. Tumors likewise produce anteversions and anteflexions in different ways: either by the pressing downward



and forward of tumors of other organs (ovarian cystomata), or by a myoma of the anterior uterine wall, which can simulate a flexion (determine course of uterine canal with sound, see Plate 14, Fig. 3), or by submucous polyps, as shown in plate 15, figure 4. Anterior myomata cause anteversion or antelexion, according to their situation in the cervix or the corpus uteri.

3. The body of the uterus may likewise tip forward and sink down, from an increase of its own weight (metritis, hyperemia of menstruation, first weeks of pregnancy).

4. Küstner found marked congenital antelexion of the uterus in strong, vigorous children; my experience confirms this, and I have frequently been able to demonstrate, in addition, a profuse secretion of glairy mucus in the cervical canal and follicular cysts in the ovary.

**Diagnosis.**—Certain symptoms and objective signs, mentioned in § 3 (3 and 4), are to be emphasized: Dysmenorrhea, sterility, constipation, and vesical disturbances are not so frequently the result of mechanically changed conditions (flexion at the internal os with stenosis, pressure of the corpus uteri upon the bladder; Plate 14, Fig. 2; Plate 15, Fig. 3) as of endometritic and parametritic hyperemia and proliferation. Constipation, associated with violent pain and digestive disturbances, and due to the cicatricial contraction of pararectal exudates, is one of the most constant concomitant phenomena. Catarrh of the bladder is also quite frequent. Disturbances of innervation play a frequent and important rôle.

The pathologic character of the anteversion or antelexion must be established: the lessened mobility of the body of the uterus; the neck, usually higher and bound down posteriorly; the cause of the fixation, commonly parametritic masses of exudation about the cervix (Plate 59; Plate 61, Fig. 2), and its pararectal extensions. The sound determines the direction of the cervical canal; and the relation that the fundus holds to the long axis of the neck is revealed by bimanual palpation.

## PLATE 14.

FIG. 1.—**Anteversion of the Uterus.** Normal position, when the bladder is empty and the uterus is not bound down. The vagina passes in a normal manner from behind forward and from above downward.

FIG. 2.—**Anteversion of the Uterus** (pathologic, as the fundus is lower than the cervix). The os looks backward and upward. Cervix elevated. Bladder pressed upon.

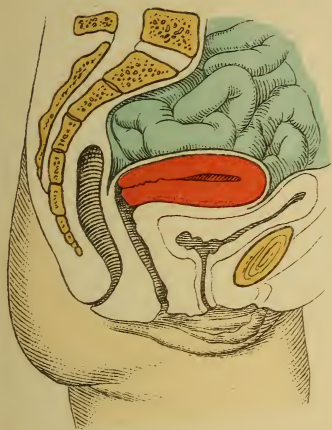FIG. 3.—**Myoma of the Anterior Uterine Wall Simulating an Anteflexion of the Second or Third Degree.** Differential diagnosis by the sound. Pressure on the bladder.

FIG. 4.—**Anteversion (or Anteflexion) of a Fixed Uterus (at the Same Time Retroposition from a Full Bladder).** The corpus uteri, bound down to the bladder, is elevated by the filling of the same; when the angle of flexion is not rigid, extension of the uterine axis occurs.

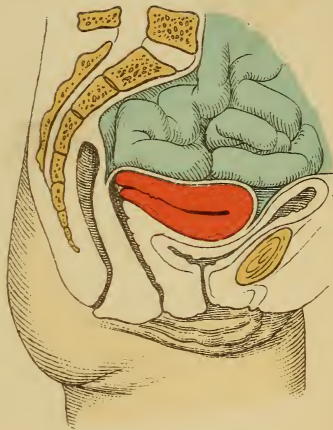
---

**Treatment.**—The cause must be removed as far as possible. See sections on parametritis, perimetritis, metritis, myomata, and § 3 (3 and 4). The symptomatic treatment is that of the uterine catarrh (see endometritis), the pain (see parametritis and § 4, 8), the vesical disturbance (see cystitis), and the constipation. The latter must be dealt with energetically: tepid injections of water ( $\frac{1}{4}$ – $\frac{1}{2}$  of a liter), oil, or occasionally infusion of senna; abdominal massage; vegetable diet; and medication by the mouth, commencing with the milder drugs. (See therapeutic table.) The intestinal tenesmus is treated with the same narcotics as those used for the parametric pains and dysmenorrhea; these are given in the form of suppositories or intestinal injections. Hydrotherapy is of value. During the inflammatory exacerbations and attacks of pain the patient must be kept in bed.

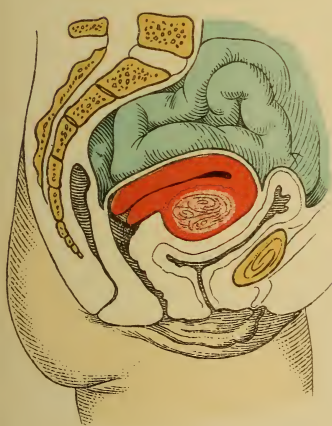
Contracting scars in the vaginal vault must be excised. (Plate 55, Fig. 1.) The treatment with the intra-uterine stem-pessary has been portrayed in § 3 (3 and 4). It is furthered by the introduction of the round ring of Mayer.



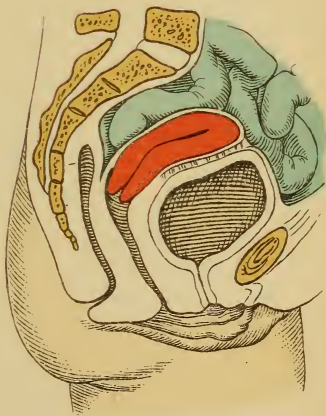
*Fig. 1.*



*Fig. 2.*



*Fig. 3.*



*Fig. 4.*



Cicatricial bands situated high up are to be stretched or torn by massage. (Plate 23.)

## § II. THE RETROVERSIONS AND RETROFLEXIONS OF THE UTERUS.

When the fundus uteri is placed vertically above the neck, or passes backward from it, and the condition is a permanent one, we speak of retroversion. We consider that its different degrees, as well as those of retroflexion, are independent of the absolute height of the fundus.

**Etiology.**—Congenital retroversion, or a vertical position of the corpus uteri, is found in feebly developed organs. Congenital retroflexions are likewise described (Saxtorph, C. Ruge, v. Winckel), and puerile retroflexions are more frequent than the later pathologic ones. Von Winckel and Küstner explain that some of the latter arise from the former by the action of pernicious influences, as a habitually full bladder and premature excessive straining. The puerperium may have a similar effect, from the dorsal position and the relaxed uterine walls.

The puerperal process, however, operates in another manner, furnishing one of the most frequent causes: namely, inflammation in combination with injuries of the vaginal vault, and stretching, tearing, and relaxation of the genitalia. (Fig. 3 of Plates 16 and 17.)

Weakened conditions, either general or local (chronic diseases, dyscrasias, postpartum subinvolution, neuropathies, masturbation), are also predisposing causes of relaxation. In this group belong those cases of simple retroversion in which spasmodic flexion has been observed by the author.

The neck may be drawn anteriorly by contracting scars (Plate 15, Fig. 2; Plate 17, Fig. 4), pushed forward beneath the corpus uteri by tumors (chronic distention of the rectum, etc.), or the organ may be bound down to the rectum or posterior pelvic wall by perimetritic adhesions. (Plate 16, Figs. 1 and 2; Plate 38.)



## PLATE 15.

**FIG. 1.—Anteflexion of the uterus of the second degree** (fundus uteri at same height as vaginal cervix) from posterior perimetritic adhesions or contracting parametritic exudates of Douglas' folds at the level of the internal os. Gaping of external os. Pressure on the bladder. The pararectal adhesions produce pain and constipation.

**FIG. 2.—Anteflexion of the uterus of the first degree with the neck lying horizontally** (rare condition); the body drawn toward the bladder by parametritic adhesions; a vesical diverticulum is drawn toward the internal os. The corpus uteri is vertical. The os looks forward and a trifle upward. The vaginal vault is drawn anteriorly, so that the vaginal axis is vertical.

**FIG. 3.—Anteflexion of the Infantile Uterus with Stenosis of the Cervix and Internal Os; Dysmenorrhea** (more frequent condition, see § 3, 3 and 4).

**FIG. 4.—Anteflexion of the uterus of the third degree** (fundus lower than the vaginal cervix), caused by a submucous uterine polyp (fibromyoma).

## PLATE 16.

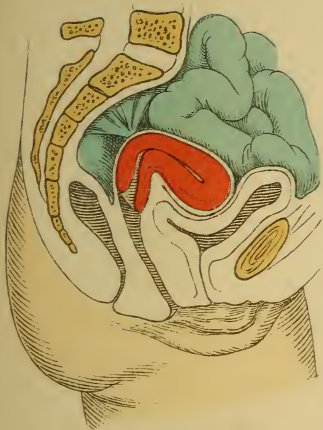
**FIG. 1.—Retroversion of a Fixed Uterus.** The uterus is vertical and is fixed by sacro-uterine and recto-uterine adhesions—the contracted and shortened uterine ligaments. Vagina put on the stretch by the elevation of the uterus.

In retroversions the chief causes for the deviation are changes in the ligaments; in retroflexion, changes in the uterine parenchyma, together with changes in the ligaments. Retroversion easily passes into retroflexion. If the adnexa are not bound down in Douglas' pouch, they usually lie above the uterus and laterally.

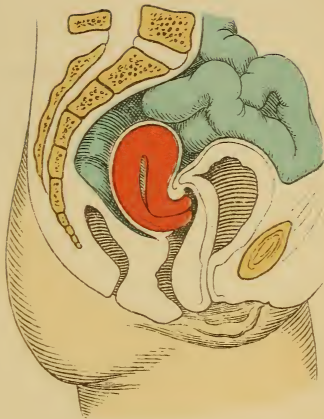
**FIG. 2.—Retroflexion of a fixed uterus** (first degree, fundus higher than the cervix); uterus bound down throughout its entire length to serosa of Douglas' pouch by perimetritic adhesions. Cervix forced anteriorly, anterior lip thinned, the anterior cervical wall likewise; posterior lip thickened. Vagina thrown into folds by the descensus. Pressure of the intestines upon the uterus.

**FIG. 3.—Slight retroflexion and descent of the puerperal uterus from relaxation of the genitalia** (dorsal position, pressure

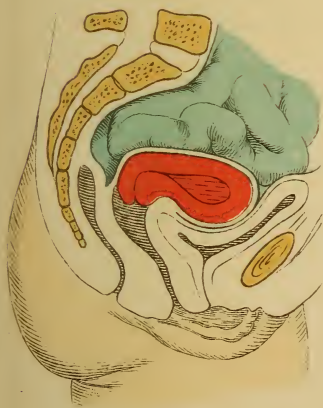




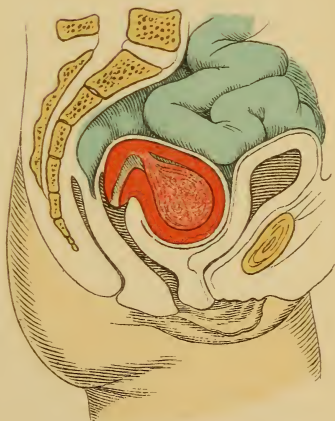
*Fig. 1.*



*Fig. 2.*

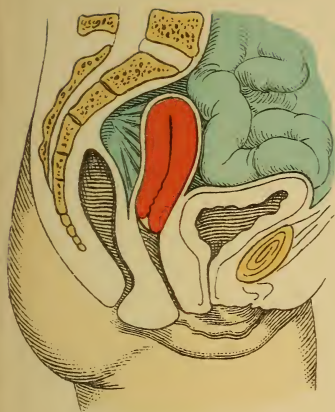


*Fig. 3.*

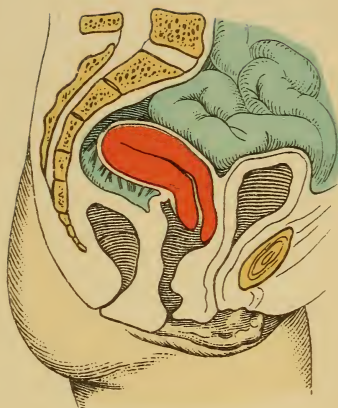


*Fig. 4.*

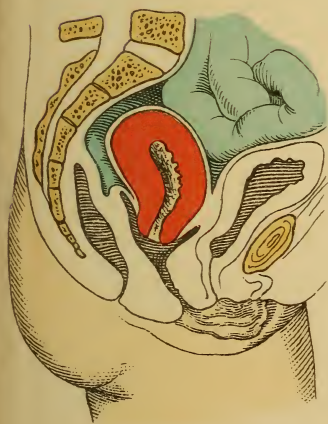



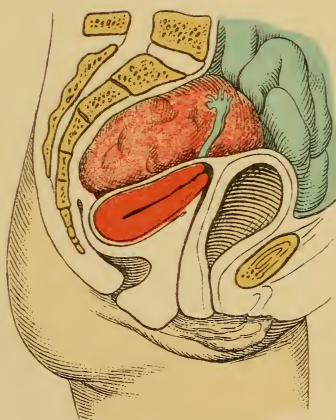
*Fig. 1.*




*Fig. 2.*



*Fig. 3.*



*Fig. 4.*



of the abdominal organs ; later, hard work, etc.). Puerperal metritis is very often the cause of subinvolution.

**FIG. 4.—Retroversion of the Uterus (Third Degree, Fundus Lower than the Cervix) from Pressure of an Ovarian Cyst.** The os is directed forward and upward. The vagina is vertical and extended. Pressure upon the rectum.

---

Uterine myomata (Plate 18, Figs. 1 and 2) or tumors of the vesico-uterine space pressing down from above may effect retroversion and retroflexion. (Plate 16, Fig. 4.) The dorsal position, a heavy, relaxed, puerperal uterus, and the weight of the intestines, usually combined with descensus uteri (Plate 16, Fig. 3), may bring about prolapse of a retroflexed uterus. (Plate 4 ; Figs. 27 and 28.)

Apart from primary inflammatory processes, secondary adhesions of the posterior serosa of an already retroverted uterus may also occur.

**Symptoms.**—Menorrhagia from hyperemia of inflammation or relaxation, and secondary proliferation of the mucosa as a result of the latter ; dysmenorrhea, partly as a result of the proliferative changes, partly from the mechanical obstruction of the flexion, and spasmodic uterine contraction ; catarrhal secretion ; sterility, less common than in ante flexion.

The pressure of the vaginal cervix produces urinary disturbances from angulations of the urethra and the ureters (Plate 19, Fig. 1), and the displacement also interferes with defecation (flattened, ribbon-like stools).

Reflex nervous disturbances appear,—not only those of digestion (vomiting with migraine, dyspepsia), but also those of the respiratory and circulatory organs (tachycardia, uterine cough, uterine asthma, neuralgia, etc.),—as well as a host of hysteric symptoms : convulsions, unconsciousness, hystero-epilepsy, cardialgia, paraplegia, aphonia, spasmodic cough, globus and clavus hystericus, and hypersensitiveness. Motor and sensory disturbances of the lower extremities (weakness, formication, cramps of

## PLATE 17.

**FIG. 1.—Encapsulated Peritoneal Exudate in Douglas' Pouch. Descent and Anterior Position of a Fixed Uterus (Furrowed, Curved Vagina).** A circumscribed peritonitis, or a gravitating peritonitis from other abdominal organs, causes an accumulation of exudate in the recto-uterine space; the overlying intestines roof in the culdesac, and by an adhesion of the serous surfaces an encapsulation of the pseudotumor is brought about. The uterus is adherent to the bladder as far as the fundus.

**FIG. 2.—Retroposition of the Uterus by a Full Bladder.** From its normal attachment to the bladder the uterus is at the same time elevated and the vagina extended. The uterine body is directly over the vagina, and their longitudinal axes correspond. This position predisposes to prolapsus uteri; consequently, the frequent habit of the young of imperfectly emptying the bladder may help to bring about a descent of the uterus.

**FIG. 3.—Descent and Retroflexion of the Uterus of the First Degree, Brought About by Relaxation of the Folds of Douglas.** To be recognized by the low position of the vertically situated vaginal cervix and by the curvature of the vagina. These symptoms make up the picture of relaxation of the genitalia and their supporting apparatus (ligaments and pelvic floor), which predisposes to prolapse of the genitalia. The external os gapes—ectropion of relaxation.

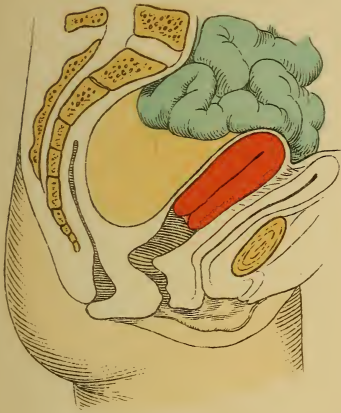
**FIG. 4.—Retroflexion of the uterus of the first degree, with a normally directed neck, caused by the contraction of parametric adhesions that bind the latter to the bladder (see § 11, Etiology).** The weight of the intestines, combined with relaxation of the uterine wall, and the dorsal position (as in puerperium) force the body of the uterus backward.

---

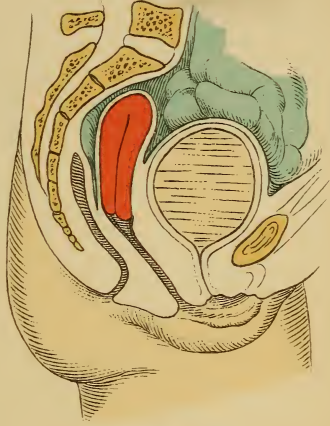
gastrocnemius) are also observed. They are due to reflex action, pressure, or inflammation.

**Diagnosis.**—By bimanual examination, after vaginal palpation and inspection have shown the anterior cervical lip to be thinned and shortened, the posterior lip thickened, and the os directed toward the symphysis. The body of the uterus is palpated either by allowing the abdominal hand to sink into the pouch of Douglas or from

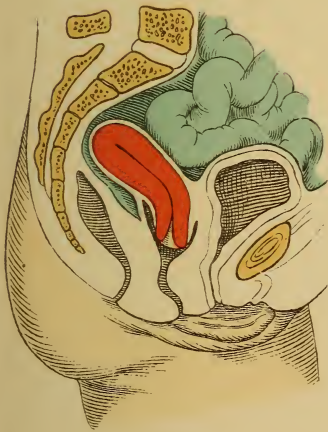




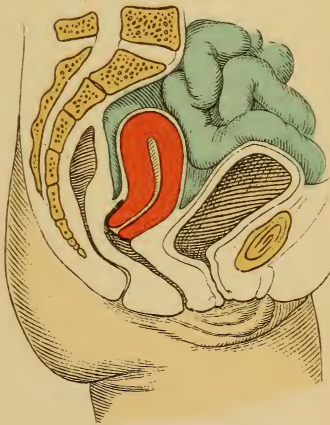
*Fig. 1.*



*Fig. 2.*



*Fig. 3.*



*Fig. 4.*



the rectum. The presence or absence of adhesions must be determined.

**Treatment.**—The manual treatment of the retrodeviations is fully demonstrated in plates 21 and 22. By this method a freely movable uterus may be replaced : *i. e.*, its body laid upon the anterior vaginal vault. Massage may be instituted if the organ is bound down by adhesions (Thure Brandt, Plate 23), the latter being forcibly torn if necessary ; or the contractile elements of the uterus, of its ligaments, and of its vessels, may be stimulated.

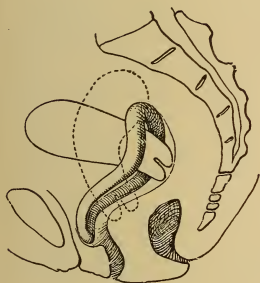


Fig. 30.—Hodge's lever pessary in retroflexion of the uterus, first degree. It effects a normal position chiefly by causing tension of the posterior vaginal vault.

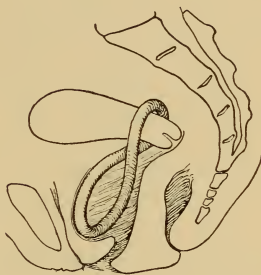

Fig. 31.—Schultze's 8-shaped pessary fixes the cervix in normal position ; it is supported by the vaginal wall and the pelvic floor.

If the free uterus can not be replaced by this method, the bullet forceps of Küstner is used, or the sound is cautiously employed. (See explanation to Figs. 1 and 2, Plate 20.)

When the uterus is brought back into its normal position, a lever-pessary is introduced as a retentive measure. (See Figs. 30–33.) Cold douches to the cervix and sacrum, alternate hot and cold vaginal douches, ergotin subcutaneously, and tamponade to strengthen the uterine walls and their ligaments are useful adjuvants.

The **lever-pessaries** are tried in the following order :

1. The **S-shaped Hodge pessary** (rather sharply curved), when the sacro-uterine ligaments are not sensitive.
2. The **8-shaped Schultze pessary**, when the pelvic floor is normal and the vagina is not too relaxed. Sometimes the instrument must be quite long.
3. The **sledge-shaped pessary of Schultze**, when the vagina is relaxed or the pelvic floor is defective.
4. **Hewitt's clamp pessary**. (See p. 71.)

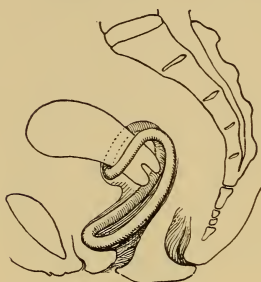


Fig. 32.—Rarer application of Schultze's sledge-pessary with firm pelvic floor.

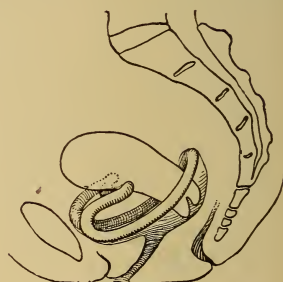


Fig. 33.—Usual application of Schultze's sledge-pessary. It is supported by the vaginal wall and the symphysis. The cervix is fixed between the anterior and the posterior bar. Employed in retroflexed descended uterus.

**Directions for the Application of Pessaries.**—The appropriate pessary is to be introduced with the patient in the dorsal or knee-elbow position, and the vagina should be held open by a duck-bill speculum, allowing the uterus and adnexa to fall forward.

1. The round, flexible caoutchouc ring of Mayer is compressed with the fingers or the Fritsch forceps (Plate 20, Fig. 2), introduced beyond the constrictor vaginæ, and placed so that the cervix rests within its opening, which should not be too small. The ring should slightly dilate the vagina.

2. The **S**-shaped pessary of Hodge and the more curved one of Thomas with a bulbous enlargement of the upper bar (made of hard rubber or celluloid, rendered flexible by hot water, or of copper wire covered with caoutchouc) are introduced into the vagina in the sagittal plane. (Plate 20, Fig. 4.) When the pessary is above the constrictor vaginae, it is rotated 90 degrees, so that the upper and broader bar comes to lie in the posterior vaginal vault, as shown in figure 30.

It acts as follows: The broad posterior bar lifts the uterus and pries it anteriorly; the cervix is drawn posteriorly by the longitudinal and transverse traction upon the vagina, and especially upon the uterosacral ligaments. From the new position of the cervix and from the pressure of the intestines upon the posterior uterine surface the uterus rests firmly upon the posterior vaginal wall; the descent of the organ and the accompanying disturbances consequently cease, even if the retrodeviation is not wholly removed. The tension upon the sacro-uterine ligaments resulting from the descent is relieved by the transverse tension and elevation of the vaginal vault. In married women the simple curved pessary, allowing of cohabitation, is the more applicable, the lower bar resting upon the pubic symphysis. Should this render the emptying of the bladder difficult, it may be provided with a curve (concave anteriorly). If the upper bar makes the vaginal vault too tense, it should be bent backward.

3. The **8**-shaped Schultze pessary is inserted with its smaller half about the cervix. (See Fig. 31.) It is made of hard rubber or of copper wire covered with caoutchouc, and rests upon the pelvic floor.

4. The sledge-shaped pessary of Schultze is so introduced that the longer bar lies above and behind the cervix, the shorter bar being in front. (Fig. 33.) The shorter curvature rests against the pubic symphysis. This pessary is used instead of the **8**-shaped one when the pelvic floor is relaxed. If the vagina is too roomy, the longer bar is



## PLATE 18.

**FIG. 1.—Retroversion of the Uterus from Two Intramural Myomata.** By palpation, the condition simulates a retroflexion of the second degree. The sound demonstrates the course of the uterine canal, and consequently the true condition. External os directed anteriorly. Rectum pressed upon; constipation; Douglas' pouch filled up. Urinary disturbances also ensue.

**FIG. 2.—Transition from Retroversion to Retroflexion of the Uterus from an Intramural Myoma of the Anterior Wall.**

**FIG. 3.—Retroflexion of the Uterus of the Third Degree (Fundus at the Height of the Cervix).** Descent of the uterus recognized by the folding of the vaginal wall (the os is below the interspinous plane also). Pressure upon the rectum. The os looks anteriorly. The uterine body fills the pouch of Douglas. Thickening of the posterior uterine wall and lip; thinning of the anterior one.

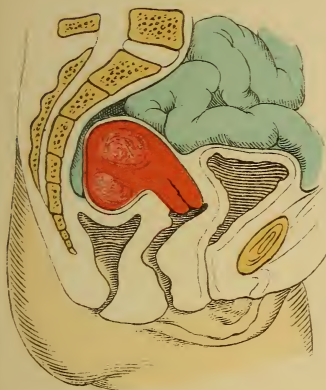**FIG. 4.—Retroflexion of the Uterus of the Third Degree (Fundus Lower than the Cervix).** Inveterate case; os looks anteriorly, gapes widely (ectropion); anterior wall of the neck and lip of the os thinned. High position of the cervix; extended, vertical vagina. Douglas' pouch filled by the uterine body.

## PLATE 19.

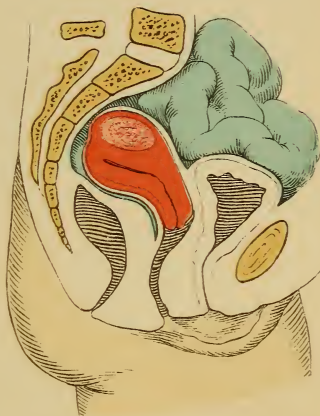**FIG. 1.—Retroversion of the Uterus; Vaginal Ovariocele.** Angulation and dilatation of the ureters. Vertical position of the vagina. (See §§ 7 and 11.)

**FIG. 2.—Bimanual Examination from the Rectum of a Case of Cord-like Total Atresia of the Vagina with a Rudimentary Solid Uterus.** During cohabitation the immissio penis has taken place into the urethra—probably congenitally funnel-shaped—and dilated it as far as the internal sphincter. The palpating finger can be pushed into the bladder without difficulty, and its withdrawal is followed by a quantity of urine. A slight incontinence exists. (Original diagrammatic drawing from a case.)

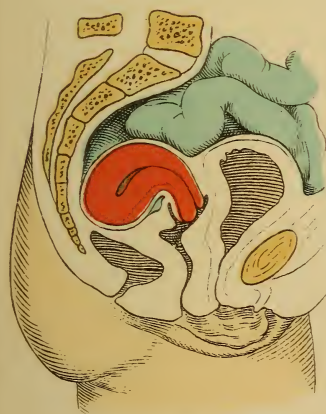



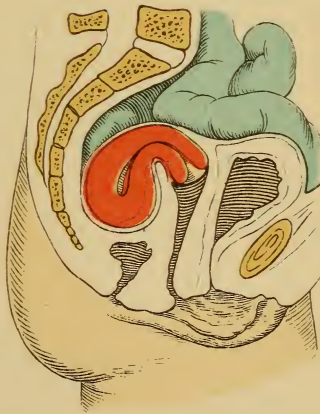
*Fig. 1.*



*Fig. 2.*

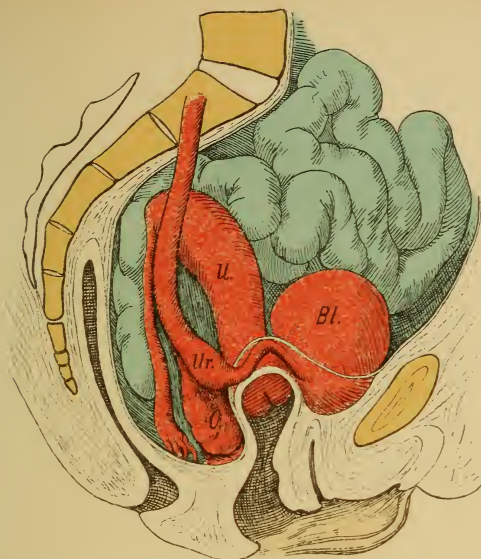


*Fig. 3.*

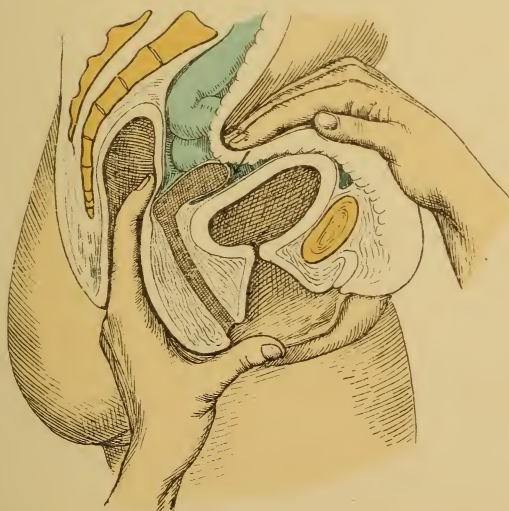


*Fig. 4.*





*Fig. 1.*



*Fig. 2.*



brought forward and used as a support, while the smaller one holds the cervix in its concavity. Material same as preceding: the 8-shaped pessary is made of rings from  $8\frac{1}{2}$  to 19 cm., the sledge-shaped of rings from  $10\frac{1}{2}$  to 14 cm., in diameter (from 7 to 10 mm. thick).

A ring is in good position if its lower end is not visible at the vulva; if it does not threaten to fall out; if it does not overdilate the vagina, but may be easily rotated on its longitudinal axis; if the upper half of the vagina is rendered moderately tense; finally, if the fundus uteri is anterior and the cervix posterior, since otherwise the folds of Douglas are not relaxed.

If the foregoing conditions are complied with, the disturbances soon disappear. In only one-fifth of the cases is a really permanent cure obtained, so that the uterus remains anteriorly without support.

**Disadvantages.**—If the ring is improperly constructed (uneven, too large, too thin, or made of wool, hair, leather), or remains in position too long, it excites hypersecretion, ulcerations, and abscesses. Fistulous tracts communicating with neighboring organs may result. Even with a pessary made of good material, I have seen this occur after the menopause. If the ulcers cicatrize, embedding the ring, or if the latter becomes incrustated with phosphates from the secretions or with dried masses of mucus and blood, it is difficult to remove the instrument. After removal of the wall of granulations the ring is to be seized with dressing forceps and extracted by rotatory movements. It is sometimes necessary first to break it *in situ*.

To obviate these difficulties the ring should be removed and cleaned after each period, although a pessary may remain in the healthy genitalia for two or three months without harmful results. Repeated vaginal irrigations of nonirritating fluids must be made: daily, if leukorrhea exists.

The ring is to be immediately removed upon the appearance of pain.

## PLATE 20.

**FIG. 1.—Reposition of a Retroverted Uterus by Means of Küstner's Bullet Forceps.** The uterus is first brought into the vertical position by traction; the cervix is then pushed backward, and the fundus uteri, if freely movable, comes forward.

**FIG. 2.—Reposition of a Retroverted Uterus by Means of the Sound.** The latter is introduced with its concavity directed anteriorly, and is pushed in until its knobbed end has passed the internal os. The concavity is now turned posteriorly, corresponding to the pathologic course of the uterine axis. If 5 or 6 cm. of the sound have passed into the uterus, its knobbed end lies in the fundus. The curvature of the sound is now cautiously (!) rotated anteriorly, the handle of the sound being depressed at the same time.

**FIG. 3.—Introduction of the Elastic Ring of Mayer by Means of Fritsch's Forceps.** The ring should lie about the cervix.

**FIG. 4.—Introduction of Hodge's Pessary.** This is bent into the shape of an S, as shown in the adjacent figure (Thomas' pessary is still more sharply bent at the upper bar). (See Fig. 30.)

---

It is very important to determine whether the displacement or its complications cause the existing trouble, or whether hysteria alone exists.

The inflammations of the bladder, endometrium, and perimetrium are to be treated in the usual manner. If adhesions render the reposition impossible, the condition is made bearable by firm tamponade of the posterior vaginal vault with glycerin tampons.

If pregnancy occurs, the pessary is allowed to remain until the fifth month; the retroflexed gravid uterus is to be similarly controlled in order to prevent incarceration beneath the sacral promontory.

Operative measures are adopted, partly to dispose of very resistant adhesions, which usually elevate the uterus considerably, partly to fix the organ anteriorly, either by celiotomy or per vaginam.

If the uterus is freely movable [Alexander's operation.—



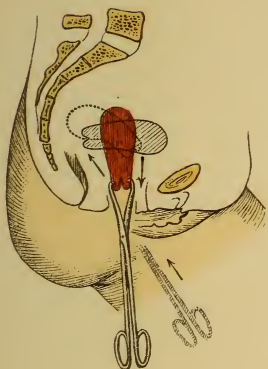


Fig. 1.

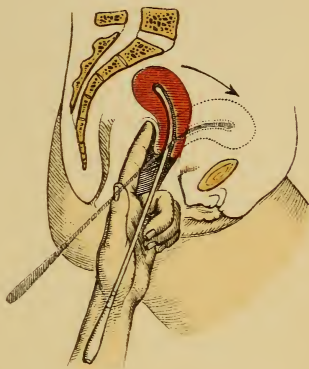


Fig. 2.

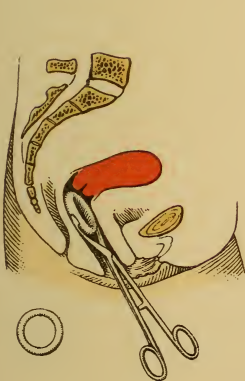

Fig. 3.

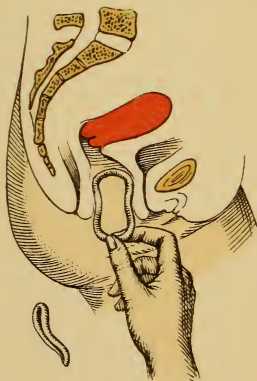


Fig. 4.



ED.], retrofixatio colli or vaginofixation is indicated ; if it is markedly adherent, ventrofixation (suspensio uteri) is to be performed. (See p. 67.)

### **The Applicability of Pessaries with Respect to Certain Complications of Retroversion.**

1. *Retro-uterine Adhesions*.—These are to be slowly stretched by massage three or four times for at least twelve sittings. First elevate in retroposition, to stretch or tear the adhesions, then anteflex the uterus, introduce a ring, and keep the patient in bed with an ice-bag upon the hypogastrium (remember the possible production of a hematocele !). The tamponade of the posterior vaginal vault is a palliative measure.

2. *Chronic perimetritis* furnishes a *noli me tangere* ; it must be cured first (absorption cure).

3. *Parametric bands and scars from lacerations* (Plate 55, Fig. 1) are excised, the longer diameter of the denudation being transverse, and the edges are so brought together that the row of sutures is in the longitudinal axis of the vagina, producing an elongation of the same (Martin).

4. *Chronic Metritis*.—This is to be treated first by wedge-shaped excisions, and then a pessary is to be applied ; if the pessary is not well borne, glycerin tampons. In acute metritis antiphlogistic treatment until the pain has disappeared.

5. *Endometritis*.—This will require astringent and antiseptic vaginal douches twice daily ; the pessary should be frequently removed ; treat the uterus by cauterization, intra-uterine irrigation and medication, atmocausis, etc. Erosions of the os are to be cauterized or excised.

6. A *stenosis of the cervix* is to be dilated or incised.

7. If the cervix is too short, it exerts insufficient leverage upon the body, which becomes flexed, or the cervix slips away from the ring and displacement occurs ; reversed introduction of the Hodge pessary with the upper bar posterior is recommended.

## PLATES 21 AND 22.

**Manual Reposition of a Retroflexed Uterus (First and Second Degrees).** First step: The body of the uterus is palpated from the posterior vaginal vault by the index and middle fingers. Second step: While these two fingers push the organ upward, the other hand covers in the pelvic inlet, passes behind the uterus, and presses down along its posterior surface until (third step) it touches the fingers in the vagina. In this manner the uterus is held from above, and is hindered from slipping backward. Fourth step: The fingers in the vagina may now leave the posterior vaginal vault and push the cervix upward, while the external hand presses the fundus toward the apex of the bladder, thus forcing the uterus into its normal position. The position of the adnexa may be determined by analogous steps. The abdominal walls should be relaxed (full bath if necessary), and the limbs should be flexed at an angle of 60 degrees. The tubes are felt as round cords; the ovaries (which can not be fixed) as bodies of the size of an almond. The ovaries lie 2 or 3 cm. laterally and behind the uterus, on the inner margins of the psoas muscles. The healthy ovaries exhibit a characteristic sensitiveness to pressure.

---

8. The anterior vaginal wall being too short, it may be lengthened by the operation mentioned under 3 (Skutsch).

9. The abnormally roomy, relaxed vagina is to be narrowed by colporrhaphy; if not permitted reversed application of the sledge-pessary, as in figure 32.

10. The puerperium is an appropriate time for the treatment of the organs and ligaments, which at this period are capable of being modeled and stretched. Replace by the method of Schultze—pushing back the cervix, elevating

---

## PLATE 23.

**Massage** (Thure Brandt). By steps similar to those shown in plates 21 and 22 the finger-tips meet behind the retroverted uterus and rub and stretch the adhesions between the latter and the rectum. At first the blood supply of the adhesions is increased; they become softer and more easily stretched. The uterus is finally “lifted” (Fig. 2) in order to lengthen the parametric bands.

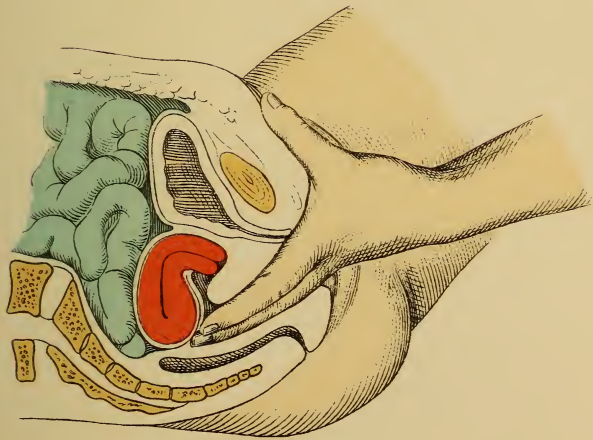


Fig. 1.

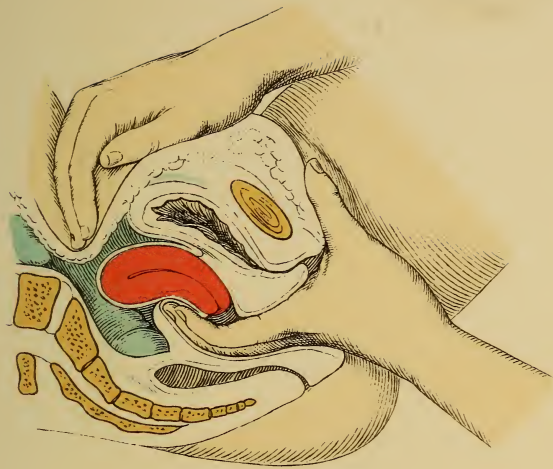


Fig. 2.





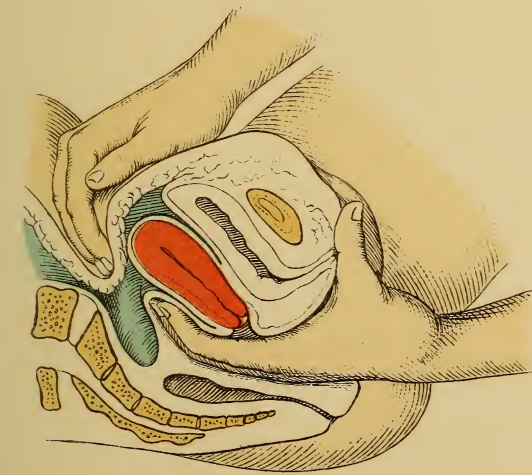

Fig. 1.

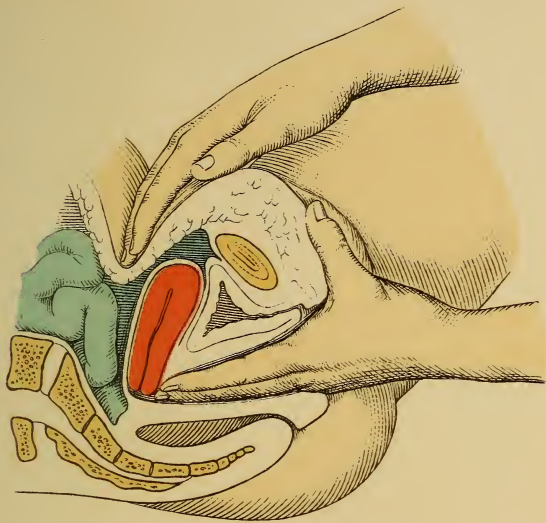


Fig. 2.



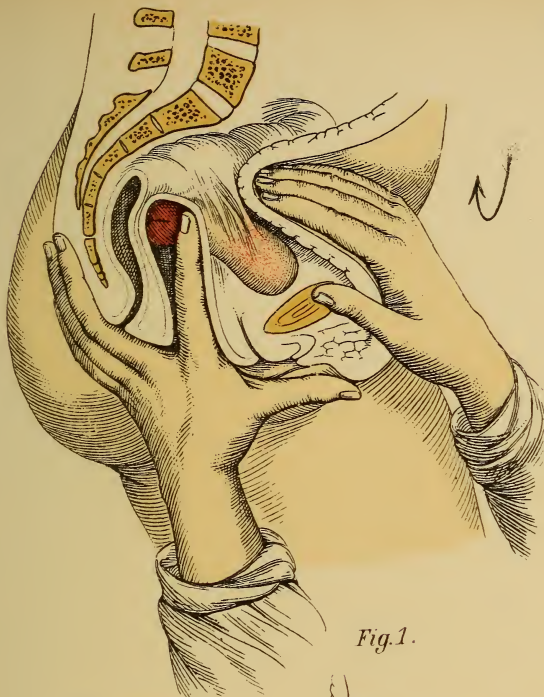


Fig. 1.

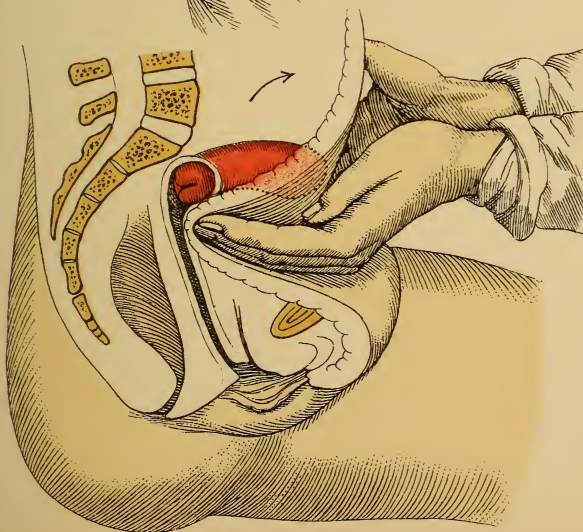


Fig. 2.



the fundus, and thus causing the body to spring forward. Retention is maintained by two glycerin tampons placed transversely in the anterior, or, at other times, the posterior, vaginal vault. Enforced lateral position.

During pregnancy it is necessary for the ring to remain only until the fifth month, because the uterus then holds itself in proper position from its increased size.

11. In *narrowing of the introitus vaginæ* (stenosis of the hymen, vaginismus) operative measures are to be adopted and a ring is to be introduced.

12. The combination of perineal defect with vaginal inversions and prolapsed uterus is to be treated by operation; otherwise, the sledge-pessary.

13. *Tumors* and *senility* are contraindications.

14. If the ring is in good position and the patient still complains, it is to be removed and another cause for the disturbances (hysteria) sought.

**Torsion of the uterus** is a pathologic turning of the uterus about its longitudinal axis, caused by tumors or abnormal distention of neighboring organs, or by parametritic or perimetritic fixations. (Plates 44 and 45.) It is usually combined with other displacements. The vaginal cervix shows the effect of the torsion. (Plate 55.)

There is a **physiologic torsion** (cause of the first vertex position), since the anterior surface of the uterus, usually in dextropositio, is turned toward the right, and the left margin approaches the symphysis (the child consequently has more room for its back on the left side than on the right, which is narrowed by the spinal column).

## GROUP III.

### INFLAMMATORY AND NUTRITIONAL DISTURBANCES.

---

#### CHAPTER I.

#### INFLAMMATION AND ITS CONSEQUENCES: ACQUIRED STENOSES AND ATRESIAS, CONTRACTIONS OF ORGANS, EXUDATIONS, AND ADHESIONS.

Inflammation in any portion of an organ affects either the parenchyma—*i. e.*, the epithelial and glandular tissue (*glandular inflammation*)—or the connective tissue (*interstitial inflammation*). Both varieties may occur together. The inflammation may run an acute or a chronic course. The former variety proceeds with active proliferation (hypertrophy and hyperplasia, small round-cell accumulations); the latter with contraction, due to the transformation of the spindle cells into connective-tissue fibers. The inflammation causes a more profuse secretion, which may be serous, mucous, or purulent, according to its severity and the nature of the affected tissue.

In the majority of cases the inflammation follows upon infection with bacteria, among which gonococci, staphylococci, and streptococci play by far the most important rôle.

The nature of the infection will depend upon the incidents of sexual life (cohabitation, puerperium); upon



operations, or upon contiguity to diseased organs (tuberculosis).

Bacteria and yeast fungi found in the secretions of the uterine cavity are not always to be considered the cause of inflammation. They have entered and flourished either because the secretion has become pathologic, or because the introitus vaginæ and the cervical canal have become affected and gape. The primary causes are the frequent active and passive hyperemias, resulting from disturbances of innervation and atonic conditions of the pelvic and abdominal organs.

The cause of the latter may have originally been infectious inflammations that have undergone resolution, but that have left behind them a diminished contractility of all the elastic elements. Such infectious inflammations may have occurred in early life. Uterine inflammations in virgins are usually of a noninfectious character, and the result of masturbation. They lead to a lessened tonicity of the whole genital system: hyperemia and relaxation of the ligaments, retroversion and retroflexion of the descending uterus, swelling and gradual descent of the ovaries. In those who have borne children, failure to nurse and general weakness play the most important rôle, as well as injudicious conduct during the puerperium, causing subinvolution and consequent chronic metritis. In one group of such cases the primary cause may have been a mild puerperal infection, which has been confined to the mucosa.

**Terminations.**—Rarely, spontaneous cure; destruction of the parenchyma from retention of secretion, abscess formation, or cicatricial contraction; in some cases the general health is affected.

## § 12. GONORRHEA.

The acute disease arises from infection with the pus of a florid urethral gonorrhea: *i. e.*, one rich in gonococci.

## PLATE 24.

FIG. 1.—**Gonorrhea.** Papilloma of the hyperemic cervix ; purulent discharge (from Mraček).

FIG. 2.—**Gonorrheal Cervicitis.** Bloody discharge. Erosio simplex. (Original water-color.)

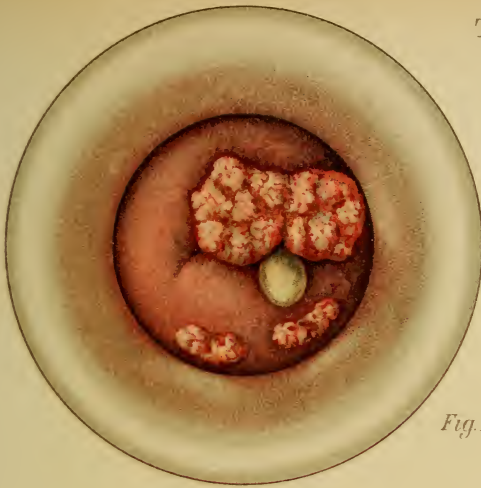FIG. 3.—**Gonococci and Pus=corpuscles.**

---

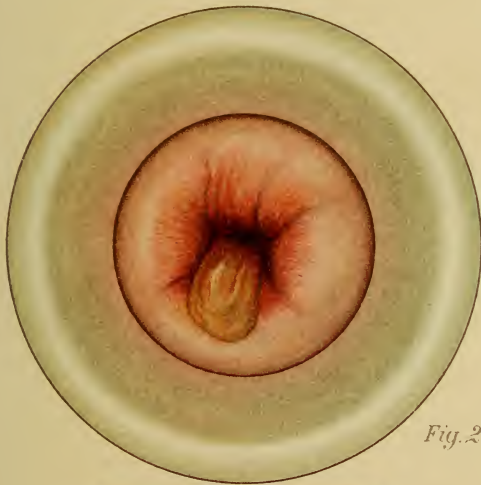(Plate 24, 3.) The vulva and the vestibule are covered with thick, yellow, creamy pus, which wells out of the vagina upon separation of the labia. As the disease progresses the discharge becomes more fluid, but remains yellow. (Plates 24 and 27.) The parts are swollen, strikingly red, and sensitive. If the finger is introduced into the vagina and stroking movements are made against the pubic symphysis, pus can be stripped from the urethra. (Plate 25.) Urination causes marked ardor urinæ followed by vesical tenesmus ; every quarter or half hour the desire to urinate returns ; the emptying of the bladder never seems complete. The symptoms of vesical catarrh present themselves ; the urine becomes cloudy and has a pungent ammoniacal odor (neutral or even alkaline reaction).

Bartholin's glands do not become inflamed until a later period (Plates 25 and 26), and in comparatively rare cases proliferation of the papillæ of the skin occurs (condylomata acuminata). (Plate 24, Fig. 1.)

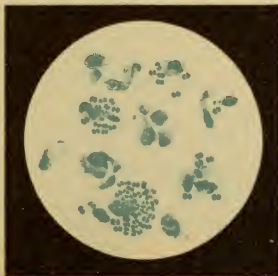
The vaginal mucosa is likewise inflamed, sensitive, and dotted with red points, corresponding to the hyperemic papillæ. The greater portion of the purulent secretion does not come from the vagina (which has no glands), but from the cervix, which becomes infected at the same time. (Plate 24, 2.) The swollen cervical mucosa is deep red and protrudes at the external os ; a cervical endometritis consequently exists. At first the process stops at the internal os.



*Fig. 1.*



*Fig. 2.*



*Fig. 3.*



Gonorrheal vaginitis, properly speaking, is a more chronic process and occurs only in children.

A different course is taken by infection from a **latent gonorrhea** (gleet of the male, *goutte militaire*, consisting of a very short stricture of the pars membranacea with a painless, scanty secretion, especially noticeable as the "morning drop"; rarely, sensitiveness of the urethra and epididymis; during sexual excitement darting pains at the root of the penis). A creeping inflammation arises, the first symptoms of which (ardor urinæ and discharge) are usually overlooked. The disturbance becomes more marked as the process invades the mucous membrane of the body of the uterus.

In this situation both forms of the disease pursue a similar course.

**Endometritis** of the body of the uterus causes irregularities of menstruation, the various pathologic varieties alternating (see §4); at the same time, as a result of the inflammatory hyperemia of the uterus, a sensation of a heavy body—of a fullness in the pelvis—presents itself; later, there is actual uterine pain. These pains, however, may also proceed from inflammations of the tubes, as the cocci quickly invade the latter from the uterine cavity.

Here the process halts for a second time, and the latent gonorrhea may remain stationary, just as the acute form does at the internal os. The gonococci may, however, penetrate into the myometrium, or may gain access to the blood and set up new areas of infection, especially in the joints. The gonorrhea becomes a lurking chronic inflammation with a dubious prognosis. The discharge is increased and purulent.

Frequently the inflammation does not extend to the peritoneum from the tube because the isthmus or the fimbriated extremity of the latter becomes agglutinated. In this way a closed sac is formed, which becomes filled with pus—a **pyosalpinx**.



## PLATE 25.

**Bartholinitis Dextra Gonorrhœica.** Perforation of the abscess on the inner surface of the nymphæ; urethritis; relaxation of the vaginal walls. (Original water-color.)

---

If the peritoneum is affected, it occurs in one of two ways: either through the tissues of the tubal wall by means of its lymphatic paths, or by continuity of structure, creeping out upon the peritoneum and ovary. The latter may likewise be infected by means of the lymphatics or from the peritoneum.

Painful, chronic, circumscribed inflammations of the serosa of Douglas' pouch arise—**perimetrosalpingitis** and **perimetro-oophoritis**. Interstitial inflammation of the ovary may terminate in abscess. These changes are accompanied by attacks of fever and considerable pain, and lead to serofibrinous exudates in the recto-uterine space, which subsequently form adhesions between the serous surfaces of the pelvic organs. These are responsible for the manifold displacements and anomalies of position of the uterus, its adnexa, the intestinal coils, and the rectum.

The disease of the tubes (it is usually bilateral) is the cause of a new symptom—sterility (one-child marriages).

It is worthy of note that the gonococci prepare the way for the pus cocci, so that in the later stages we have to do with a mixed infection.

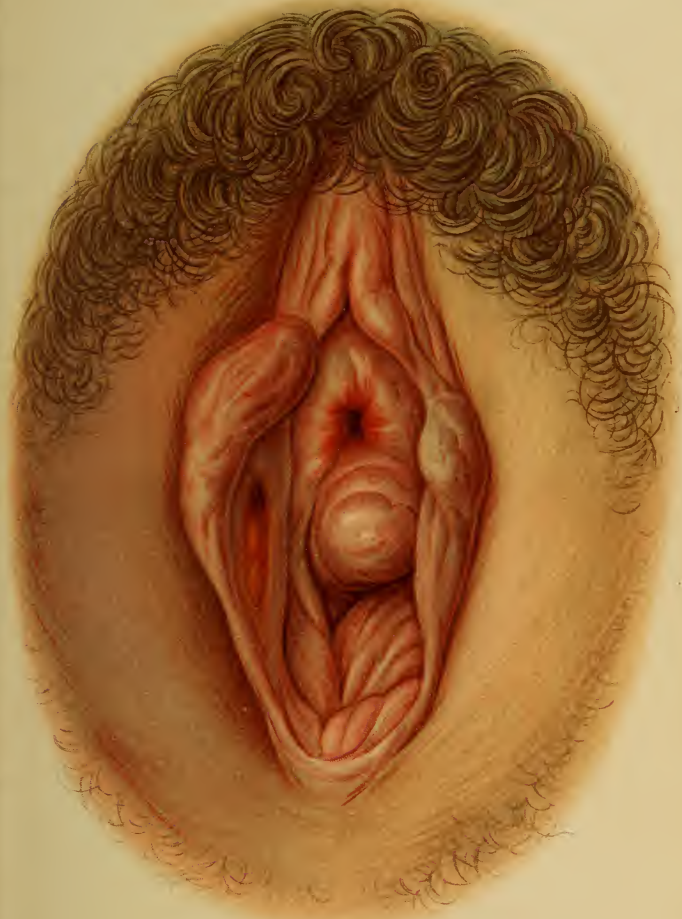**Symptoms.**—Ardor urinæ (finally vesical catarrh and bartholinitis, the former being recognized by the cloudy, alkaline urine containing crystals of triple phosphate and acid urate of ammonium, numerous micrococci, and mucus, pus-, and blood-corpuscles; the latter, by the increased

---

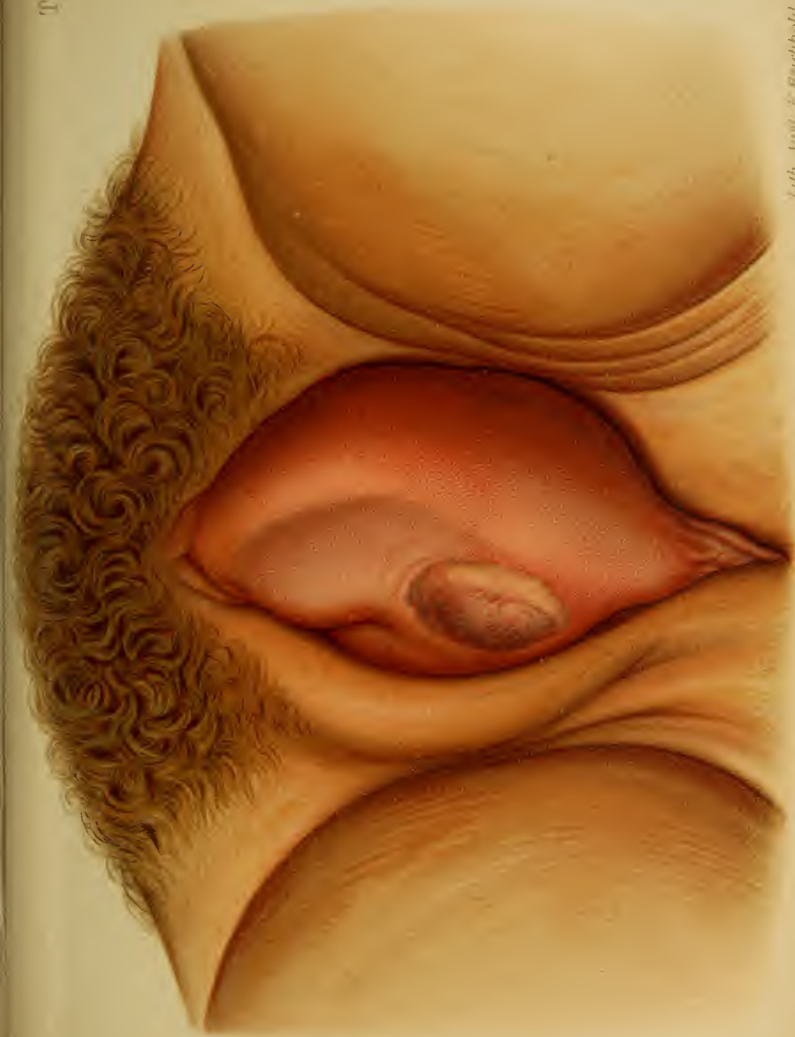## PLATE 26.

**Bartholinitis Sinistra Gonorrhœica.** Abscess formation (from Mragek).











tenderness, redness, swelling, and finally fluctuation at the lower third of the labia majora, see Plates 25 and 26); purulent discharge from the vagina, irregularities of menstruation, pain, and sterility.

**Diagnosis.**—Demonstration of the gonococci (by staining for half a minute in an effective alcoholic solution of methylene-blue—see Plate 24, Fig. 3; it is the only coccus decolorized by Gram's method; above all, it is found *within* the pus-cells); a general or punctiform reddening of the vagina; the pus is seen to come from the cervix; pain is localized in the uterus, adnexa, or peritoneum of Douglas' pouch.

**Treatment.**—In fresh cases with colpitis alone: Vaginal irrigations with a 5% solution of protargol (five times daily for two weeks, then twice daily with potassium permanganate); keep the parts clean, especially the vulva (cervicitis is usually present, however). Dilatation of the cervical canal by means of metal dilators, after having carefully disinfected it and the vagina by means of antiseptic solutions; intra-uterine irrigation with two liters of a 0.5% to 2.5% (even 5%) solution of protargol (increase the strength gradually for two or three weeks). Following this, the introduction of 5% to 10% protargol salve or bougies, wiping out the vagina with a 10% protargol solution and gauze tamponade with protargol salve or protargol glycerin. In the third week of this treatment the application of astringents to remove the remaining swelling of the mucous membrane mentioned on page 93: Aluminum acetate solution (2 to 5%), bismuth subnitrate (2 to 3%). This treatment is to be carried out with caution, the patient being kept at absolute rest in bed for the greater part of its duration, to prevent the disease from spreading to the adnexa. It is based upon Neisser's recommendation of the silver albuminates (especially protargol) as specifics.

If for any reason this treatment can not be properly carried out, we must return to the earlier method of treat-

## PLATE 27.

**Gonorrheal Vulvitis and Vaginitis.** Old perineal tear of first degree ; external hemorrhoids ; intertrigo. (Original water-color.)

## PLATE 28.

**FIG. 1.—The Microscopic Structure of the Parts of the Vulva.** (1) Stratified squamous epithelium with the excretory ducts (2) of the numerous sebaceous glands of the labium majus, whose connective tissue (3) is sparingly supplied with blood-vessels. (4) Stratified squamous epithelium of the nymphæ (still without sebaceous glands in the fetus), covering numerous connective-tissue papillæ ; the cavernous tissue is traversed by numerous capillaries, which form a mass of erectile tissue at (6). This is surrounded by dense bundles of fibers receiving their blood supply from (10) and passing to the outer lamella (8) of the hymen, the squamous epithelium (9) of which is likewise stratified. The inner lamella of the hymen is composed of bundles of fibers and vessels, which come from the vagina (12). (Original drawing from a specimen obtained from a newly born girl.)

**FIG. 2.—Longitudinal Section Through the Cervix in a Case of Old Prolapse of the Uterus.** The stratified squamous epithelium of the cervix shows a superficial horny degeneration. The transition from the squamous epithelium of the outer wall of the cervix to the cylindric epithelium of the cervical canal is seen at (3). Its displacement inward is due to the slight ectropion of the lips of the os. The stasis of the blood and lymph in prolapsed uteri is apparent from the dilated vessels (4). (Original drawing.) (See Plates 10 and 12.)

**FIG. 3.—Simple, Papillary, and Follicular Erosion of the Cervix.** (Original drawing combined from different specimens.) At the left are seen the intact stratified squamous epithelium of the vaginal cervix ; this is continuous with cylindric epithelium, which is formed by the cuboid cells of the matrix after desquamation of the squamous epithelium has occurred (*erosio simplex*). Further to the right are seen papillary elevations with cylindric epithelium (*erosio papilloides*). Glandular follicles showing cystic dilatation from retained mucus, or filled with exudation, are seen in the inflamed connective tissue, which is traversed by dilated vessels with round cells (*erosio follicularis*). Some muscle-fibers are above and to the left. (See Plate 29, Fig. 4 ; Plates 33, 35, and 37 ; Plate 60, Fig. 2 ; and Plate 90, Fig. 1.)



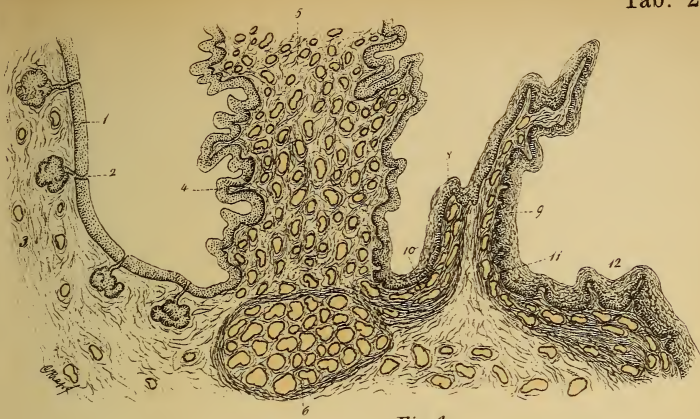

Fig. 1.

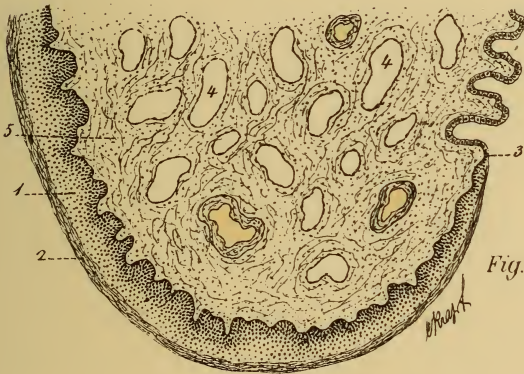

Fig. 2.

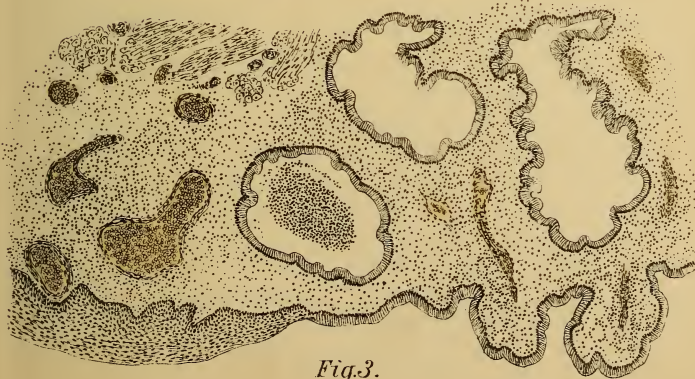

Fig. 3.



ment: let the cervix alone, wash away the secretions several times daily with 2 or 3 liters of solutions of silver nitrate, potassium permanganate (bright red), bichlorid of mercury (1 : 2000 to 1 : 4000), the patient being in the recumbent posture; wipe out the vagina several times a week and pack with protargol gauze (10 %); finally, the patient is allowed to introduce tampons of protargol glycerin.

The husband must have his urethra appropriately treated.

Argonin—also an albumin-silver combination—contains less silver than protargol. Argentamin, on account of its greater penetration and its ability to excite inflammation, is adapted only to neglected cases, in which it is of considerable service. Nitrate of silver is of value in the after-treatment because of its astringent qualities. Largin contains 11.1 % silver in combination with nucleo-albumin, and excels all others in its power of killing the gonococci; it is, however, inferior to them in rendering the soil unfit for the organism.

For the urethritis (female): wipe out the urethra with a 5 % protargol solution, sublimate 1 : 5000, or a 2 % solution of silver nitrate, and introduce a 5 % protargol bougie every day for a week; the bladder may eventually be washed out with a 1 % to 2½ % protargol solution.

If the Bartholinitis goes on to abscess formation, incise when fluctuation occurs and pack with iodoform gauze; if it recurs, excise it entire and bring the edges of the wound together.

Condylomata are removed with scissors or cauterized with 25 % chromic acid, concentrated carbolic acid, or nitric acid.

Cystitis: Wash out the bladder as previously directed; later, with a 1 % or 2 % silver nitrate solution and a 2½ % solution of cocain (¼ to ½ liter, lukewarm, using catheter and Hegar's funnel, or Küstner's urethral funnel).

Internally, diuretic drinks (milk, tea, juniper berries, etc.) and urotropin—0.5—three times daily.

In the second group of cases—the older ones—only

1 of 6.

## PLATE 29.

**FIG. 1.—Elephantiasis Vulvæ.** (Original drawing.) (1) Stratified squamous epithelium covering the connective-tissue papillæ. Numerous lymph capillaries (3) are seen in the connective-tissue stroma (2). Some round-cell deposits are present, due to the proliferation. (See Plate 51, Fig. 1.)

**FIG. 2.—Condyloma Acuminatum.** (Original drawing.) (See Plate 24, Fig. 1.) Fine dendritic proliferation of the connective-tissue papillæ (2), which are covered with a very thick layer of stratified squamous epithelium (1).

**FIG. 3.—Vaginal Secretion.** (1) Polygonal squamous epithelium (seen from the side at 6); (2) red blood-corpuscles; (3) leukocytes; (4) oidium albicans; (5) staphylococci; (7) bacilli; (8) trichomonas vaginalis.

**FIG. 4.—Cross-section of an Ovule of Naboth Situated in the Wall of the External Os.** (Original drawing from a specimen.) (1) Simple cylindric epithelium of the cervical mucosa; (2) partly desquamated cylindric epithelium from dilated cervical glands (ovula Nabothi); (3) cervical glands; (4) stratified squamous epithelium of the vaginal cervix. (See Plate 37, Fig. 2; Plate 60, Fig. 2; Plate 90, Figs. 1 and 3.)

after the vagina has been washed out for weeks do we proceed to treat the uterus on the principles laid down under endometritis and metritis. (See §13.) If affections of the adnexa are not rigidly excluded by careful bimanual examination, every intra-uterine therapeutic measure will be replied to by these organs with an exacerbation of the trouble. The salpingitis, etc., must be first treated. (See § 16.)

In commencing joint affections the temporary constriction of the extremity is to be carried out according to the method of Bier.

### § 13. CHRONIC ENDOMETRITIS. EROSION AND ECTROPION OF THE EXTERNAL OS.

Endometritis is an affection of the uterine mucous membrane alone; it may appear as a disease *sui generis* without

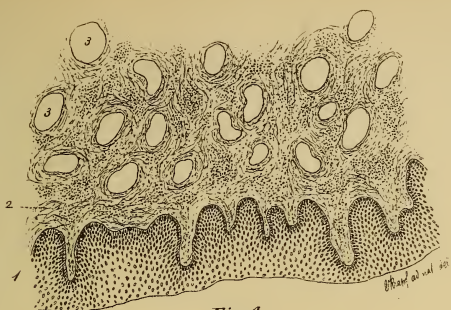


Fig. 1.

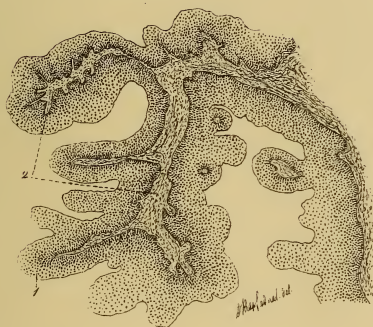

Fig. 2.

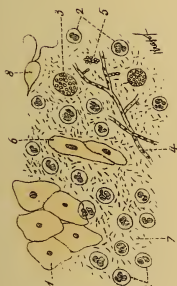


Fig. 3.

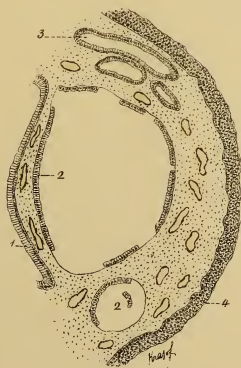


Fig. 4.







affecting other organs, and causes little general disturbance.

Although gonorrhea plays the most important rôle in the etiology of the infectious uterine inflammations, there are, nevertheless, an important class of cases in which we must seek another cause. This is especially true when they occur in the virgin. Pyogenic organisms, not infrequently owing their introduction to the practice of masturbation, are partly responsible for them.

Another group of cases frequently leading to a general disease may be traced to a septic infection, whether it occur in the puerperium, or as the result of operative measures or of trauma.

Clinically, we are able to differentiate :

1. Catarrh (*a*) of the cervical mucosa ; (*b*) of the corporeal mucosa, usually of a nonbacterial nature.
2. Purulent inflammation (*a*) of the cervical mucosa ; (*b*) of the corporeal mucosa, almost without exception of a bacterial nature.

From an anatomic standpoint the first form is synonymous with the pure glandular inflammation ; the second, with the interstitial inflammation accompanied by some glandular change. (See explanation to Plates 30 and 31 and p. 107.)

The affections of the cervix are the more frequent ; those of the mucous membrane of the uterus, the more severe.

**(a) Catarrh of the Cervix and Chronic Cervicitis and Their Consequences : Erosion and Ectropion.**

The acute inflammation of the mucous membrane and wall of the cervix is, without exception, of an infectious nature, and is due to the invasion of gonococci or streptococci following puerperal lacerations, trauma, or operations upon the cervix. In the latter case either the ulceration of the vaginal cervix or the inflammation of the entire uterus and its surrounding connective tissue may be the more prominent manifestation.

## PLATE 30.

FIG. 1.—**Normal Uterine Mucosa.** (Original diagrammatic drawing.) The mucous membrane of the entire uterus is covered with a single layer of ciliated cylindric epithelium. In the cervix these cells are club-shaped and considerably higher than in the corpus uteri. Both forms produce mucus, which ascends from the more easily stained protoplasm about the nucleus to the upper portion of the cell, from which it is emptied. As this process goes on, the nucleus of the utricular cell ascends and descends, while the more actively secreting cervical cell possesses two constituent parts: a lower rounded portion, always containing the nucleus, and devoted to secretion; an upper portion, connected with the former by a narrow isthmus, and devoted to the storage of the secretion. This upper portion consequently does not take the nuclear stains. The nuclei of the cervical cells are necessarily all at the same level, while in the utricular cells this is not the case. The cervical cells are fixed by means of processes that extend underneath the contiguous epithelium. In the intact healthy uterus the cylindric epithelium extends to the external os, where the squamous epithelium of the vagina commences.

The uterus may be anatomically divided into two parts—the body and the neck. Corresponding to the utricular and cervical cells, we also have two specific forms of glands: large, acinous glands in the cervix (cervical glands); long, narrow, tubular glands, chiefly in the body (utricular glands). These glands are distributed as follows:

In the body of the uterus, only tubular utricular glands with low epithelium, the nuclei being centrally situated. In the cervix above the plicæ palmatæ, both cervical and utricular glands, the former having unusually high epithelium. In the plicated region, simply folds and recesses, no real glands; the plicæ are studded with slender, thread-like papillæ, which are covered by a low, almost cuboid, cylindric epithelium.

In the lowest portion of the cervix both acinous and tubular glands are found; there is also another variety of papillæ—low, fungiform, and covered with large club-shaped cervical cells.

The secretion of the healthy uterus is scanty. The vagina contains no glands, or only a few (*glandula aberrantes*) at its junctions with the uterus and with the vulva.

The mucous and submucous connective-tissue stroma is richly supplied with round cells and vessels, which allow of considerable varia-

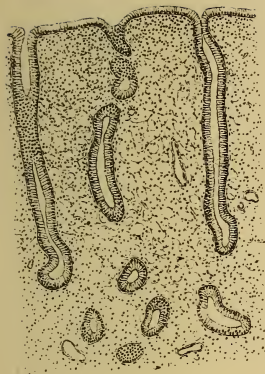


Fig. 1.

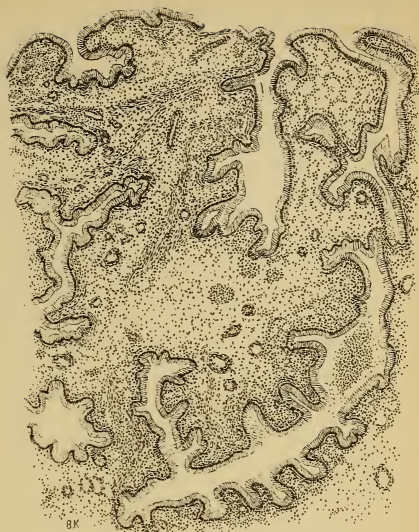


Fig. 2.

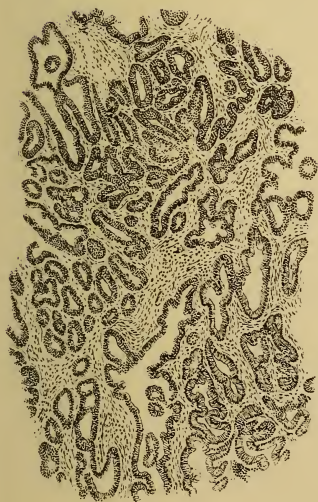

Fig. 3.

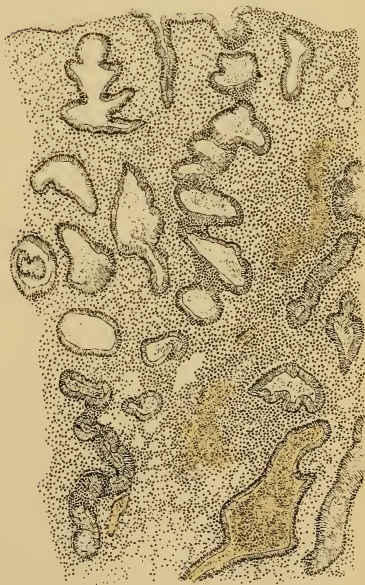

Fig. 4.





tion in the degree of swelling of the mucous membrane, whether it be momentary or corresponding to the periodic congestions. This also explains its rapid regeneration. The muscularis is situated beneath the submucosa.

**FIG. 2.—Hyperplastic Glandular Endometritis.** (Original drawing from a specimen.) The individual glands are more numerous and are increased in extent by lateral pouchings (Ruge); the walls are enveloped in a connective-tissue capsule, which is richly infiltrated with leukocytes and round cells; the remaining stroma shows practically no inflammatory or proliferative process. If the stroma gave evidences of the latter, the condition would be known as endometritis fungosa (Olshausen), the mucous membrane being considerably thickened. If the proliferation of glandular and interstitial tissue is circumscribed, the condition is known as endometritis polyposa.

**FIG. 3.—Malignant adenoma (glandular cancer)** (original drawing from a specimen) differentiates itself from hyperplastic endometritis by the fact that the glandular (epithelial) proliferation exceeds that of the connective-tissue stroma; the relative proportion between the two differs from the normal. The glandular tissue eats up the stroma, so to speak, destroys the muscularis, and finally invades other organs or gives rise to metastases along the lymphatic channels. The stroma always shows marked round-cell infiltration; the glandular spaces are lined with stratified squamous epithelium—an evidence of the active proliferation. There is a striking irregularity in the form of the glands and in the picture as a whole.

**FIG. 4.—Hypertrophic Glandular and Interstitial Endometritis.** (Original drawing from a specimen.) The glandular hypertrophic form rarely occurs alone, and consists of an enlargement (no increase or marked pouching) of the glands (Ruge); they become coiled like a corkscrew, showing, at most, a serrated pouching. In this specimen the interglandular tissue shows proliferative round-cell infiltration; hemorrhages have occurred in both glandular and connective tissues. The superficial epithelium has undergone partial desquamation.

---

Chronic cervicitis arises as a sequel to such an inflammation, especially if the external os has been lacerated and gapes.

The noninfectious inflammations of the cervix present

## PLATE 31.

FIG. 1.—**Acute Interstitial Endometritis.** The interglandular connective tissue is in active proliferation, and consists of densely packed round cells. The glands are partly pressed aside and partly converted into retention cysts (ovula Nabothi) by distortion of their excretory ducts. Hemorrhage into the stroma. Epithelial desquamation. (Original drawing from a specimen.)

FIG. 2—**Chronic interstitial endometritis** is the continuation of the former, the round cells becoming changed into rigid connective tissue. The glands atrophy. The vessels become thick-walled. The superficial epithelium is absent or almost squamous (the squamous epithelium of the external os can be seen at the left of the illustration).

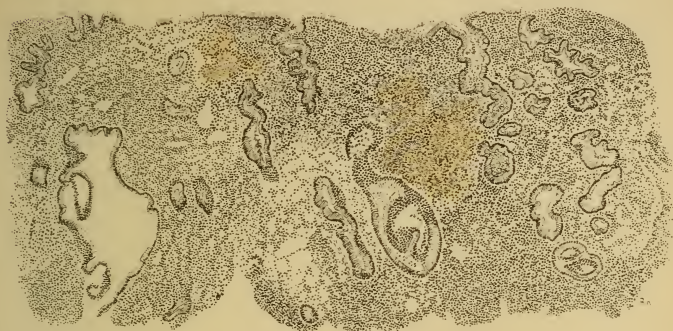
FIG. 3.—**Postabortive Endometritis.** An island of decidual cells may be seen under the partly regenerated superficial epithelium. Few glands, many round cells, strongly dilated capillary blood-vessels.

the same clinical picture. A condition of relaxation is the primary cause; it may lead to ectropion even though no laceration exists. If the inflammation is limited to the mucous membrane, we speak of catarrh of the cervix.

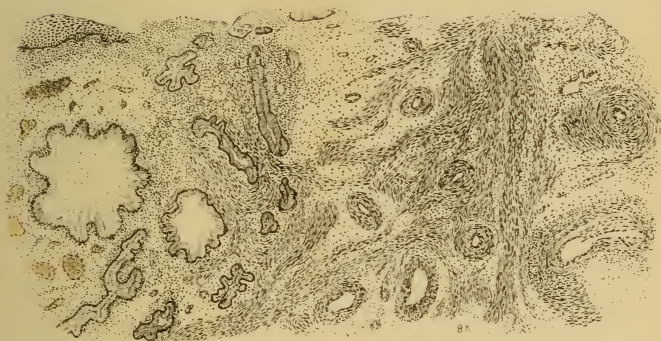
**Symptoms.**—The discharge is the first and most constant symptom. In uncomplicated catarrh it is mucoid; in purulent cases (mixed infection) it is mucopurulent as a result of the admixture of pus-corpuscles. This discharge in time weakens the individual and hinders conception by the formation of a cervical plug of tough mucus. The blood-vessels are overfilled and are easily torn on account of the inflammatory proliferation of the mucous membrane. (Plate 30.) Reflex menorrhagia and dysmenorrhea occur, as well as slight hemorrhages from contact. Pain is present, however, in the intervals between the periods, if the swollen mucous membrane protrudes from the external os—**ectropion**. (Plate 28, Fig. 3; Plates 35 and 56.)

Ectropion usually occurs when the commissures of the os uteri have been lacerated. I have repeatedly seen it

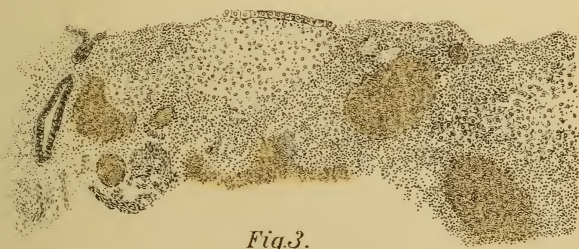



*Fig. 1.*



*Fig. 2.*



*Fig. 3.*



arise in the intact uterus if pessaries were introduced when the organ was relaxed and in a lower position than usual.

**Diagnosis.**—Palpation discloses the thickening of the cervix, and the examining finger is covered with mucus or pus. Changes of structure can be felt only in the older ectropions, and such a condition should always lead one to suspect a beginning cancer.

**Inspection (Speculum).**—In a multipara with ectropion the examination of the mucous membrane is easy; in the closed orifice of the nullipara we discover, at most, retention cysts of the cervical glands—ovula Nabothi. (Plate 29, Fig. 4; Plate 56, Fig. 1; Plate 69, Figs. 1 and 3.) In these cases we must draw the os well down by means of forceps, evert the lips with tenacula, or dilate the external os.

The cervical cavity is distended by the profuse, tenacious secretion; this may be demonstrated by the sound. (Plates 47 and 67.)

The secretion also causes a desquamation of the superficial layers of the squamous epithelium about the os uteri, and *erosio simplex* is produced. (Plate 28, Fig. 3; Plate 33, Fig. 1.) If the cells of the matrix become cylindric and arrange themselves in glandular formations, we have to do with an *erosio papilloides*. (Plate 90, Fig. 1.) If either one is combined with the formation of ovula Nabothi, we speak of *erosio follicularis*. (Plate 37, Fig. 2.)

**Differential Diagnosis.**—Between erosion and ectropion: In the former the external os is centrally situated within the erosion; in the latter it is outside of, and pressed away by, the ectropion. (Plates 33, 37, and 56.)

Differentiation between *erosio papilloides* and epitheliomatous papilloma is best made by the microscope. (Plate 28, Fig. 3; Plate 79, Figs. 1 to 3.) The follicular form may produce polypoid excrescences by a circumscribed elevation of portions of the mucous membrane. (Plate 90, Fig 3.)

Between ectropion (Plates 34, 35, and 56) and incipient

## PLATE 32.

**FIG. 1.—Marked Congestion and Beginning Simple Erosion of the Posterior Lip of the Os, as a Sign of Uterine Inflammation: Endometritis and Metritis.** The simple erosion (see Plate 33 also) consists of a casting-off of all the epithelial cells above the cuboid layer, allowing the cutaneous capillaries to shine through more distinctly. The constant irritation of the uterine secretion is the cause of the desquamation.

**FIG. 2.—Slight Congestion of the Cervix of a Multipara with a Characteristic, Broad, Fissured External Orifice.**

cancer: Touch is not to be depended upon, since both conditions offer the sensation of hard, solitary nodules. (Plates 81, 83, 84, and 90.) Inspection shows ovula Nabothi in ectopion; nodules with destructive ulceration in carcinoma. If ulceration does not exist, all that remains is the microscopic examination of an excised piece.

**Prognosis.**—It is of importance to remember that catarrh of the cervix is cured with difficulty, and that the inveterate forms have a tendency to malignant degeneration.

**Treatment.**—The local treatment of the cervical mucosa is exactly the same as that of the uterine mucous membrane. (See p. 109.) The swelling of the vaginal cervix and of the ovules of Naboth is greatly lessened by multiple punctures and scarifications. If the external os is narrow, lateral incisions are to be made—to the vaginal vault, if necessary.

Erosions are to be treated by cauterization: Acetic acid, to which 4% carbolic acid has been added, is poured into the

## PLATE 33.

**FIG. 1.—Congenital Simple Erosion of the Cervix of a Virgin.** (Original water-color from a case.)

**FIG. 2.—Leukorrhœa and Simple Erosion.** (Original water-color from a case.)



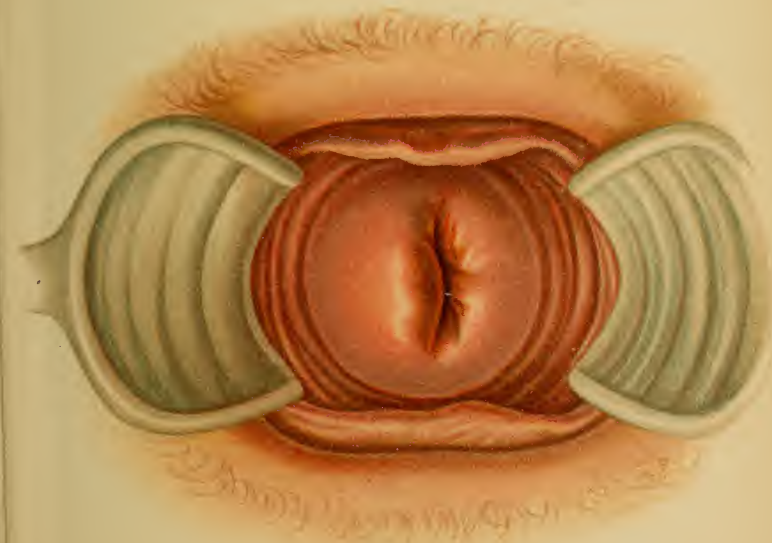


Fig. 1

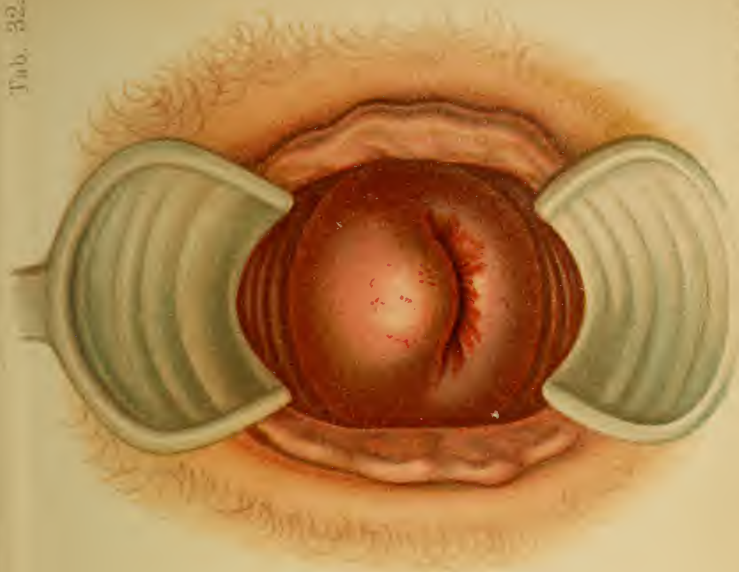


Fig. 2. Lab. and A. Bartholin. Mombou





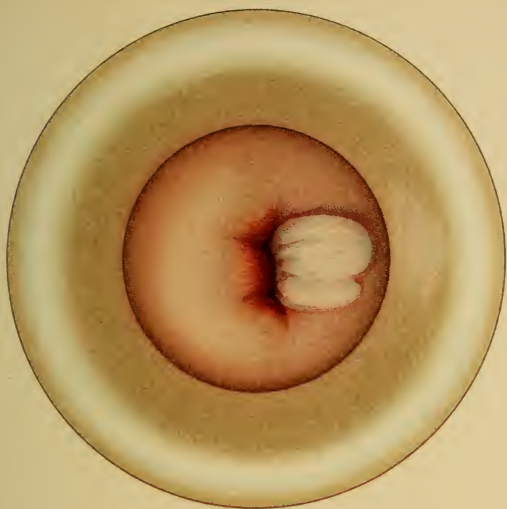


Fig. 2.

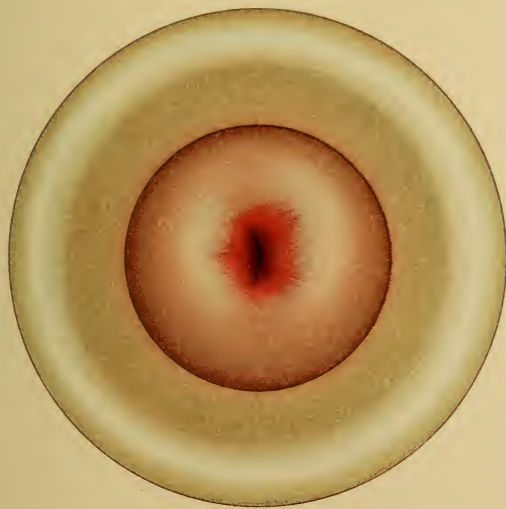

Fig. 1.



speculum and allowed to act for several minutes (daily, for a few weeks). The reddened ulcerated patches gradually disappear as the pathologic cylindric epithelium is replaced by epidermoid cells. Weak solutions of cupric sulphate or zinc chlorid act more quickly. If the epithelial covering is cast off in deeper ulcerations, cauterize with one drop of fuming nitric acid, afterward washing out with warm water; otherwise, excise. Above all, remove the cause—the discharge.

Ectropion and follicular hypertrophy of the mucous membrane, if present in but a slight degree, vanish when the catarrh is treated with caustics. The severe forms are treated by operative measures: by removal of the swollen mucous membrane by means of a wedge-shaped excision from the entire thickness of the cervical wall (see Metritis under § 14); by excision of the connective-tissue commissures of the gaping os uteri followed by suture. In other cases the pessary should be removed and an operation for prolapse should be performed.

#### (b) Endometritis Corporis Uteri.

Any endometritis, whether it be cervical or corporeal, may appear as an acute or a chronic process, or in milder or severer forms.

The latter division denotes not only difference of grade, but also qualitative change:

The milder forms produce no structural change; the secretion is more profuse and is mucoid and glairy; hemorrhages occur.

The severer forms lead to proliferation and to a purulent discharge.

There are certain histologic peculiarities that explain these differences (see Plates 30 and 31); these are as follows (Ruge, Veit):

I. *Endometritis glandularis*: (1) Hypertrophic—*i. e.*, the glands proliferate in length only, becoming rolled up between the surface of the mucosa and the muscularis. Their longitudinal section resembles

## PLATE 34.

**Ectropion with Extreme Relaxation of the Cervical Wall and Intact Commissures of the External Os.** Anemic cervix following climacteric menorrhagias from myomata. (Original water-color from actual case.)

a corkscrew. (2) Hyperplastic—the glands proliferate in length and breadth, forming lateral pockets.

II. *Endometritis interstitialis*: (1) Acute round-cell proliferation leads to purulent secretion; (2) chronic or cirrhotic connective-tissue formation, contraction, leading at last to atrophic endometritis.

The glandular forms occur as mixed forms, especially with acute interstitial endometritis; if the hyperplasia and proliferation are pronounced, we have:

III. *Endometritis fungosa* (mixed form), if the proliferation is diffuse; or—

IV. *Endometritis polyposa* (mixed form) and *endometritis follicularis* (Plate 90, 3), if it is circumscribed.

From groups II and III the following varieties may be separated, their most striking symptom being either hemorrhage or a casting-off of the mucosa:

V. *Endometritis exfoliativa* (dysmenorrhœa membranacea, see § 3).

VI. *Endometritis dissecans* with phlegmon.

VII. *Endometritis hæmorrhagica*: scanty secretion; fungous mucosa; after abortion in acute infectious diseases.

If the endometritis is the result of an abortion, we designate it as:

VIII. *Endometritis post abortum*, to be recognized by the large decidual cells.

The ovules of Naboth arise (Plate 29, Fig. 4; 56, Fig. 1; 69, Figs. 1 and 3):

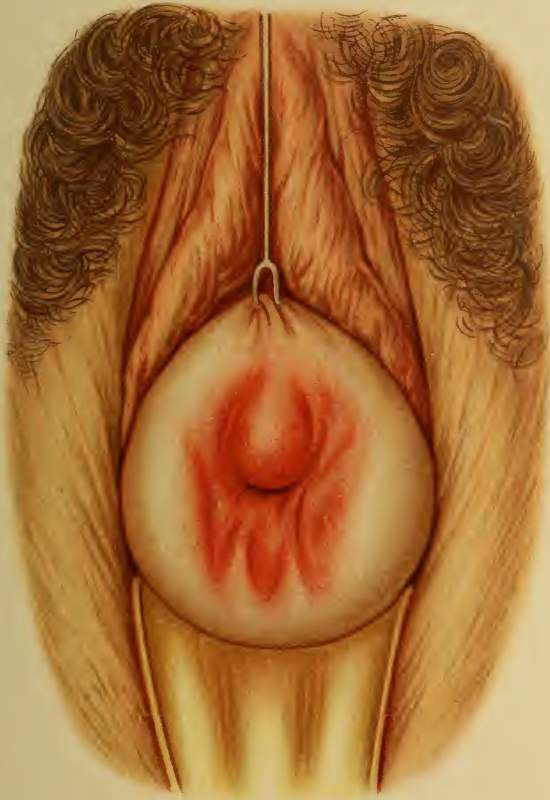1. From excessive proliferation and secretion in I (2).
2. From a too narrow excretory duct in I (1).
3. From occlusion of duct by angulation in I (1).
4. From compression of duct by inflamed connective tissue in II (1).
5. From cicatricial closure in II (2).

The **symptoms** of chronic endometritis corporis uteri are the same in infectious and noninfectious cases:

1. Pain, at the time of the menses (dysmenorrhea),

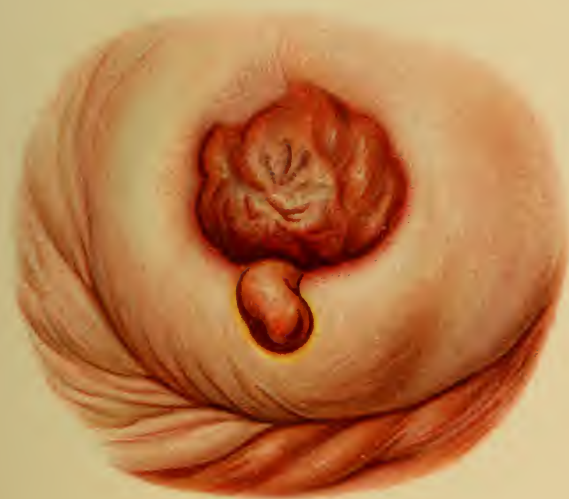## PLATE 35.

**Mucous Polyp and Ectropion of the Anterior Lip of the Uterus.** The cervical walls are relaxed and anemic; the commissure of the os uteri is intact. (Original water-color from actual case.)











with or without casting-off a decidua menstrualis ; or, rarely, in the interval (intermenstrual pain) ; or permanent, ceasing with the beginning of the flow, so that the menstrual period is the only time at which there is no pain ; or permanent, with exacerbations at the menstrual epoch. (See § 17.)

2. Discharge, mostly bloody, serous, mucoid (Küstner, Schröder) and purulent (B. S. Schultze). Determined by means of tampons.

3. Changed character of menstruation ; menorrhagia and dysmenorrhea.

4. Sterility.

5. Reflex nervous disturbances : pains in the umbilical region, dyspepsia, all varieties of hysteric troubles.

As the myometrium is usually involved, the symptoms of myometritis may complicate the clinical picture.

**Diagnosis.**—1. The sound causes characteristic pain as it passes the internal os ; the entire uterine mucosa is hyper-sensitive. The sound also reveals the size of the uterine cavity and any roughenings or fungosities that may be present.

2. Abrasio mucosæ (curetment, raclage, excochleation)—the tissue is removed and its structure examined with the microscope.

3. In doubtful cases the cervical canal is dilated (metal dilator of Fritsch, Küstner's adjustable dilator, laminaria—well sterilized) and the entire uterine cavity is palpated.

**Prognosis.**—Serious results follow from the hemorrhage and from the discharge, as well as from the occurrence of malignant degeneration.

**Treatment.**—Above all, provide for a regular and sufficient discharge of the secretions. The external os, and especially the internal os (normally 4 mm. in diameter), are usually constricted from the inflammatory swelling of the mucosa, and may require mechanical dilatation. To aid in removing the secretions, vaginal irrigations

## PLATE 36.

FIGS. 1 *a*, 1 *b*, 1 *c*. —**Different Molds of the Uterocervical Canal as Shown by Swollen Laminaria.** The end to which the silk thread is attached lay in the external os. (Original water-color from actual cases.)

FIG. 2.—**Curetment in Fungous Endometritis.** Relaxed, anemic cervix; sharp, although irregular limitation of the squamous epithelium at the external os. (Original water-color from actual case.)

---

with astringents (alum, tannin, bismuth subnitrate, zinc sulphate) or antiseptics (potassium permanganate, solution of aluminum acetate,<sup>1</sup> formalin, 1 : 4000 to 1 : 2000 corrosive sublimate), exciting the uterus to contraction and washing the cervical mucosa.

The character of the diseased mucous membrane must be changed by using astringents or caustics. The stronger caustics (10 % zinc chlorid, for example) should not be used, as they may produce strictures, stenoses, and pathologic adhesions. These substances are best applied in liquid form (sesquichlorid of iron in 50 % solution or pure, 2 % solution of silver nitrate, 5 % solution of zinc chlorid, fuming nitric acid) by means of cotton and the aluminum sound.

At the same time the infectious virus must be removed, either by the foregoing caustics or by antiseptics. In addition to intra-uterine irrigation (Fritsch's two-way catheter), pencils of itrol or iodoform may be introduced.

The cervix may be dilated and the uterine cavity may be disinfected at the same time by packing the uterus with itrol or iodoform gauze (following Abel, to be removed daily). Landau introduces yeast cultures.

The changed and infected mucous membrane may be removed by radical methods—abrasion, curetment (ravage, excochleation).

<sup>1</sup> See Therapeutic Table.



Fig. 1 a



Fig. 1 b



Fig. 1 c

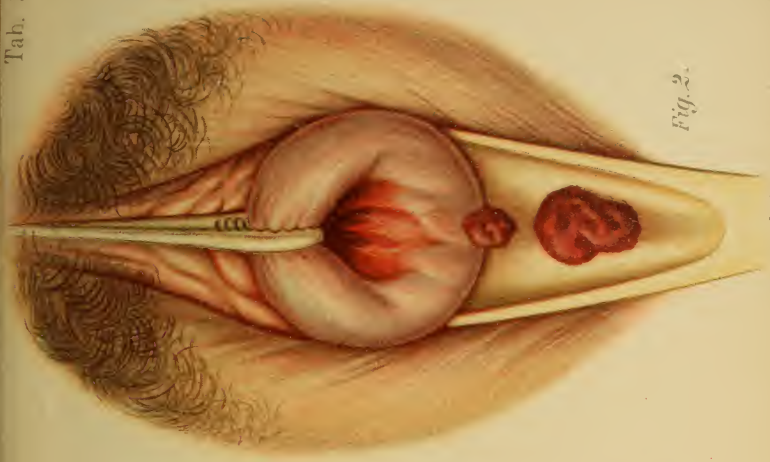


Fig. 2.





After careful disinfection and dilatation the cervix is fixed with bullet-forceps and the uterine walls are carefully and evenly scraped. Simon's sharp spoon or the dull wire curet may be used. [The dull wire curet is practically useless.—ED.] The various portions of the cavity should be cureted in some definite order. The cureting is to be immediately followed by packing with antiseptic gauze (itrol, iodoform) or with gauze saturated with some caustic (solution of ferric chlorid, formalin). This controls the hemorrhage, acts as a disinfectant, and brings the medicament in contact with the remaining diseased mucous membrane. It is still better to follow up the curetment with atmocausis or zestocausis. (See Treatment of Chronic Metritis.)

Narcosis is necessary in the majority of cases. The intra-uterine irrigations may sometimes cause colic.

For three or four days after the curetment daily intra-uterine douches of 2% carbolic acid act favorably; in the marked cases of proliferative fungous endometritis the process is kept within bounds by washing out the uterine cavity twice daily, and then applying astringents (solution of sesquichlorid of iron, tincture of iodin) by means of the sound.

According to my experience, atmocausis and zestocausis (vaporization, vapocauterization) are productive of better and more permanent results than these scraping and cauterizing methods.

#### § 14. CHRONIC METRITIS.

The clinical picture of chronic metritis consists of inflammatory hyperemia and swelling and sensitiveness of the entire organ. It leads to a connective-tissue hyperplasia rather than to a proliferation of the muscle-cells. The inflammation progresses slowly, with acute and subacute exacerbations, and in some cases ends in cirrhosis. The endometrium is nearly always diseased, and consequently

## PLATE 37.

**FIG. 1.—Chronic Metritis with Ovula Nabothi.** Metritis is an inflammation of the uterine muscularis. If the process is of long duration, the muscle-cells are partly replaced by scar-tissue (see Plate 31, Fig. 2), which in our illustration retracts the cervical mucosa and causes a visible wrinkling. The ovula Nabothi are retention cysts, resulting from distortion of the ducts by contracting connective tissue. (Plate 29, Fig. 4.)

**FIG. 2.—Gonorrheal Endometritis with Simple Erosion and Ovules of Naboth; Inflammatory Hyperemia.** (Plates 29, 30, and 31.) Thick, yellow, creamy pus flows from the os and fills the vagina. The ovula Nabothi are also filled with pus. The erosion is the result of the endometritis. The simple infection with gonococci soon gives place to a mixed infection with staphylococci and streptococci, the former organisms having prepared the soil for the latter. The process creeps up the tubes and then progresses to the nearest peritoneal surface (metritis, oophoritis, perisalpingitis), at first producing exudations, then adhesions and cicatricial bands. (Plates 44 and 45, Fig. 36.) The gonococci, as a rule, invade only the superficial layers of those membranes covered with cylindric epithelium.

The adhesions of the tubes and ovaries lead to the formation of abscesses (Pyosalpinx, Plate 42) and sterility. The perimetritic process causes displacements of the uterus and its adnexa.

---

the symptoms of myometritis and endometritis are inseparably associated.

There are two stages: (a) The stage of hyperemia and round-cell infiltration: the uterus is soft and easily torn, as a result of the edema and fatty degeneration of the muscularis. (b) The stage of cirrhotic induration: the uterus is tough, anemic, or livid from venous stasis

---

## PLATE 38.

**Retroversion of the Fixed Uterus (First Degree) and Agglutination of the Cervix (Acquired).** A peritoneal pseudoligament holds the uterine fundus in retroversion. Caustics or senile processes cause adhesions and, later, atresia of the cervix. Changed direction of the vagina in retroversion of the uterus. (Original water-color from a specimen in the Munich Frauenklinik.)

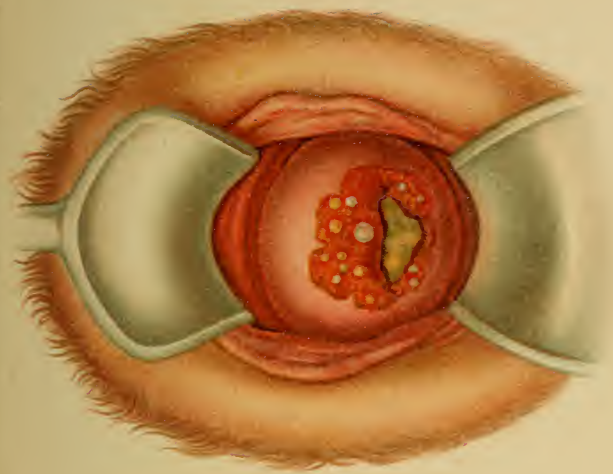


Fig. 2

*Tab. Anat. T. Boettgeri, München.*

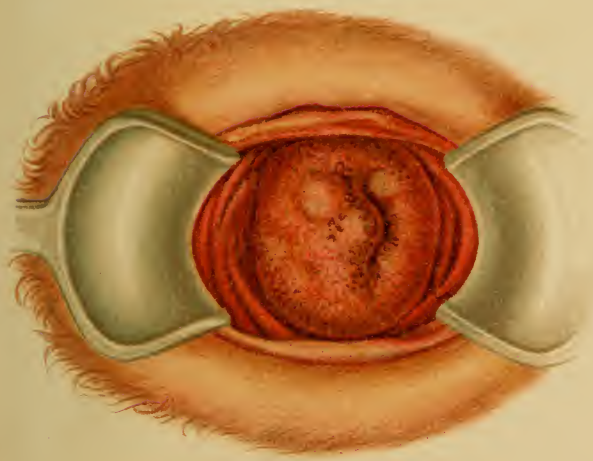
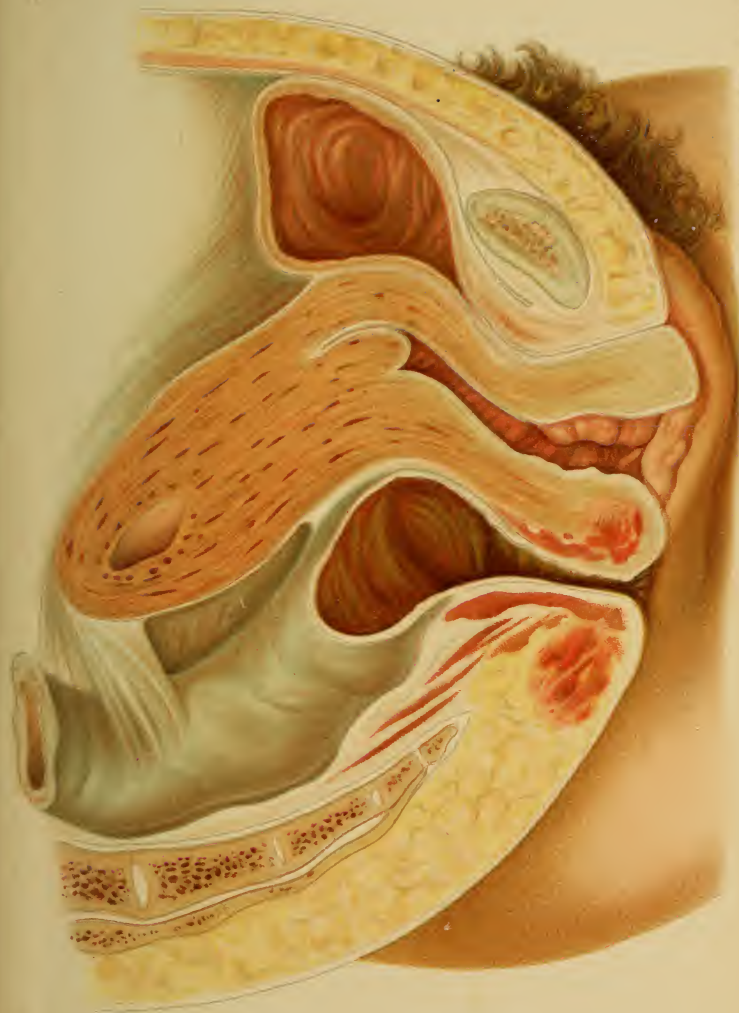

Fig. 1









(arterial walls thickened, their lumen narrowed, muscularis partly replaced by connective tissue).

**Etiology.**—(1) From puerperal subinvolution; (2) from the irritation of a chronic endometritis; (3) from the penetration of infectious germs (especially gonococci); (4) from other hyperemic irritations, such as masturbation; (5) from venous stasis in flexions, prolapse, or other displacements accompanied by engorgements (habitually full bladder, chronic constipation, or secondary stasis from circulatory disturbances in other organs); (6) rarely, from an acute metritis.

**Prognosis.**—Although the disease does not cease at the menopause, but usually several years later, this time is the best for effective treatment. The prognosis is more favorable if the second stage appears early, as the disturbances then disappear.

**Symptoms.**—A sensation of fullness (as if a heavy body were in the abdomen), pains in the side and sacral region, discharge, menorrhagia, dysmenorrhea, dysuria, and constipation. The symptoms are more pronounced at the menstrual epoch or when obstinate constipation exists. They are favorably influenced by rest in the dorsal position.

**Diagnosis.**—The cervix is soft, thickened, and hyperemic, with swollen lips, from the accompanying endometritis—ectropion, erosion, ovula Nabothi. (Plates 32 and 56.) In the second stage the cervix is livid, hard, and wrinkled. (Plate 37, Fig. 1.)

Hypersensitiveness is not always present, but a peculiar softening and enlargement of the organ occur, causing it to resemble a gravid uterus at the second and third months. The sound reveals the elongation of the uterine cavity and a thickening of its wall.

Any variety of inflammation of the surrounding tissues and organs may occur. Conception takes place with difficulty, and leads to abortion or to premature delivery.

**Differential Diagnosis.**—In the first months it is dif-

## PLATE 39.

**Acute Purulent Pelvic Peritonitis (Peritonitis of Perforation).** View of pouch of Douglas and the posterior wall of the uterus and left broad ligament with its tube and ovary. The pus has been wiped off of the uterus but allowed to remain on the serosa of Douglas' pouch. (Original water-color from a specimen at the Heidelberg Pathologic Institute.)

---

difficult to differentiate a gravid uterus from an inflamed organ; the former is softer, especially at the cervix and internal os (bimanual from the rectum), and rests upon the cervix like a round, thickened body; the latter is more sensitive. Pregnancy must always be thought of, especially if intra-uterine treatment is under consideration.

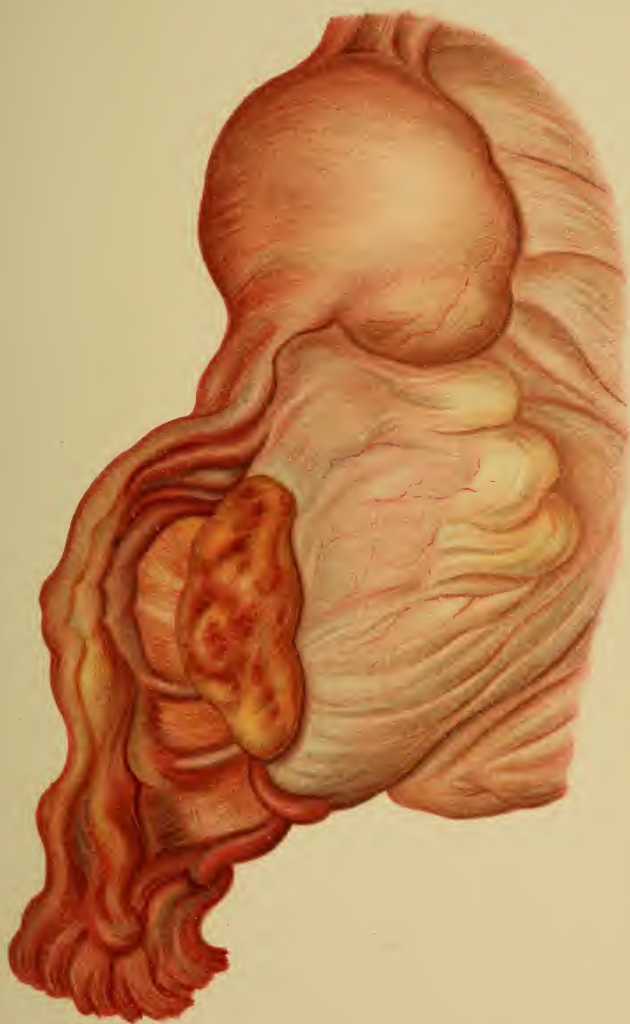Intra-uterine tumors may be palpated with the sound, or directly with the finger after dilatation of the cervix. The inflamed uterus is elongated, especially the cervix, which is contracted in virgins and everted in multipara. In cancer small pieces may be removed and examined microscopically.

If the case is simply one of endometritis, the increase in volume and the hypersensitiveness of the entire organ are not marked.

**Treatment.—Prophylactic.** — During menstruation: rest in bed (not all the time); avoid everything inducing congestion (excitement, especially sexual; heating drinks; constipation; colds). During the puerperium: Ergotin, warm or cold applications, abdominal massage; hot vaginal irrigations (117° to 127° F.) or warm general baths (95° to 100° F.) in the second week.

Special treatment of the hyperemic stage—absorptive: hot injections and baths, with or without salt or lye.

The hyperemia is controlled by constricting the vessels: Ergot or ergotin, hydrastis, stypticin; hot vaginal injections; scarifications of the cervix (every three or four days,  $\frac{1}{2}$  to 2 fluidrams, especially before the period) relieve





congestion and pain. Compression by means of vaginal tamponade and sand-bags or shot-bags laid upon the abdomen.

Glycerin tampons are used as derivatives, and the secretion is further stimulated by astringents and caustics. The applications are to be repeated every week, but only in the first stage. Curetment, followed by chlorid of iron or iodine (Playfair's aluminum sound).

The application of steam to control hemorrhage (menorrhagia) is, according to the author's experience with *atmo-causis*, a most valuable addition to our therapeutic measures. It was first employed by Snegirew, the instrumentarium being perfected by Pinkus. My own observations show that it is as effective in obstinate endometritis as it is in inflammations of the myometrium. It is not advisable for one unskilled in gynecologic practice to make use of this method, especially if he is without assistance. It is as little adapted for ambulatory treatment as is curetment.

The instrumentarium is as follows: A tested boiler with safety-valve and thermometer; a rubber tube (tightly screwed to the boiler), rather thick and well wrapped; and a two-way intra-uterine catheter with a discharge-tube for the steam returning from the uterine cavity. The catheter is covered with gauze or celluloid to protect the cervix from injury and subsequent stenosis. The pressure and temperature of the steam and the duration of its action must be gaged to suit the individual case. A curetted uterus or one having a small cavity must be treated more mildly, probably using only the zestocautery: *i. e.*, the *closed* catheter, 105° to 112° C., for from ten to twenty seconds; with a large cavity and a thickened endometrium, 110° to 115° C., for fifteen seconds. If obliteration is desired, steam at 115° to 120° C. for from one-half to two minutes is to be employed. This may be repeated, whereas ordinarily the application should not be renewed until the next menstrual period has passed. Narcosis is not neces-



sary, but is usually desirable ; the same is true of assistance. The cervix must be dilated.

The methods of treatment just named are symptomatic and palliative. If pain and a sensation of fullness are present : frequent scarifications and glycerin tampons ; abdominal belt and pessary to remove tension from the uterine ligaments.

For the menstrual disturbances : Previous scarifications, warm sand-bags upon the abdomen or warm alcoholic fomentations (narcotics). In menorrhagia : ergotin, tamponade, application of ferripyrin or introduction of ferripyrin-gauze tampons, gelatin injections, atmocausis.

#### **Operations for the Purpose of Reducing the Size of the Collum Uteri and Removing the Diseased Mucous Membrane.**

These results, together with the removal of scars from lacerations, are best accomplished by means of *wedge-shaped excisions* (or amputation of the cervix, removal of conic pieces of tissue—operations of Sims, Hegar, Simon, Schröder). The following operations are to be particularly recommended :

*Schröder's Operation.*—The inner circumference of the os with its diseased mucous membrane is completely excised. The remaining outer half of the cervical wall is turned in and sewed to the remains of the cervical mucosa.

*A. Martin's Operation.*—The entire vaginal cervix is excised in the shape of a cone. The cervical mucosa is then drawn down and stitched to that of the vagina.

*Kehrer's Operation.*—Wedge-shaped pieces are excised from both lips of the os uteri. Their base is formed by the cervical mucosa, and they extend through the entire cervical wall.

**After the Operation.**—Glycerin or iodoform-gauze tamponade (one day) ; then vaginal irrigations ; for secondary hemorrhage firm gauze tamponade with ferripyrin, solution of sesquichlorid of iron, or suture ; if catgut has not been employed, removal of sutures in eight days.



## § 15. SEPSIS.

(Acute Vulvitis, Vaginitis, Endometritis, Myometritis, Salpingitis, Parametritis and Perimetritis, Peritonitis.)

The acute inflammations of the endometrium and myometrium present practically the same clinical pictures. They are due to the invasion either of gonococci or of septic germs. It is to the inflammations caused by the latter that attention is now directed.

**Etiology and Clinical Aspect.**—Invading pyogenic organisms (streptococcus pyogenes ; staphylococcus aureus, albus, citreus, etc.) excite septic inflammations ; the avenues of infection are either the skin or mucous membrane of the genitalia, or the peritoneal covering.

The opportunity for invasion through the lining mucous membrane is given by trauma, by faulty technic in operations and examinations (sounds, dilators), or by the puerperal process.

By virtue of the peculiar quality of the secretion and of the wound surface, which is particularly adapted for the multiplication of invading organisms, the puerperal infections are of the greatest importance. The secretions may stagnate in closed spaces, at body-temperature, and in direct communication with numerous lymphatic channels.

The "gynecologic" infections take the following courses, according to their point of introduction, the infection depending not only upon the place of entrance, but also upon the virulence of the germ and upon the general and local power of resistance of the individual.

**Vulva** (*Phlegmone Vulvæ*).—The infection usually remains local and leads to abscess formation. The perineal infections, especially when near the rectum, lead to thrombophlebitis and general infection.

**Vagina** (*Colpitis Crouposa et Diphtheritica, Phlegmone Vaginæ, Abscesses, Paracolpitis, Paraproctitis*).—The infection remains local, at most spreading to the adjoining

## PLATE 40.

**FIG. 1.—Acute Catarrhal Parenchymatous Salpingitis (Due to Gonococci and Streptococci).** The tubal catarrh is the first consequence of the invasion of the cocci in the endosalpinx, and it produces a hypersecretion of mucus. The endosalpinx commences to proliferate; the connective-tissue papillæ (1), covered with columnar ciliated epithelium, form dendritic ramifications that fill the lumen of the tube (2). The stroma of the papilla is infiltrated with young round cells (6). The submucosa (4) and the muscularis (5) are still healthy, but there is a commencing perivascular (3) round-cell infiltration. (Original drawing from a specimen.)

**FIG. 2.—Hematosalpinx.** In gynatresias (see Figs. 7–11 in text) the menstrual blood remains in the uterus and finally dilates the tube (2); the epithelium (1) desquamates after the papillæ (3) have been flattened by pressure; the vessels (5) of the submucosa (4) are dilated from stasis; there is a reactionary round-cell accumulation (7) about the blood-vessels in the muscularis (6). Tubal hemorrhages occur during the periods, in heart disease and kidney disease, in cases of myomata and ovarian cystomata, and in extra-uterine pregnancy. (Original drawing from a specimen.)

**FIG. 3.—Pyosalpinx.** The ostia being closed, the pus distends the tube. The epithelium (1) is completely destroyed; the papillæ (2) are flattened; the stroma (3), rich in round cells, is bathed in pus; and the elasticity of the tubal wall is destroyed because the muscle-fibers (4) are separated and replaced by connective tissue (6). The submucous capillaries are dilated from stasis; the vessels of the muscular layer show a chronic inflammatory thickening. Such pus sacs contain different varieties of microbes, the virulence of which depends upon the age of the abscess at the time of its rupture. (Original drawing from a specimen.)

---

connective tissue. Contrary to what is the rule in puerperal cases, the process very rarely extends to the uterus.

**Uterus** (*Endometritis et Metritis Acuta*).—The course is doubtful, and if progressive, it may be a very chronic affection.

**Symptoms.**—Bloody and mucopurulent discharge; enlargement and hypersensitiveness of the uterus (expe-

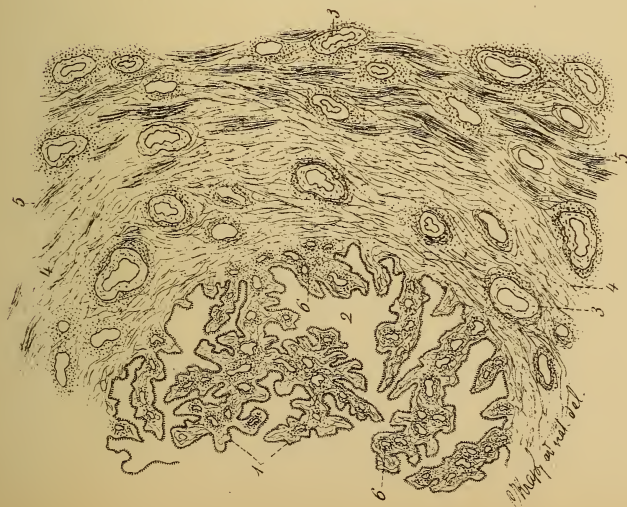


Fig. 1.



Fig. 2.

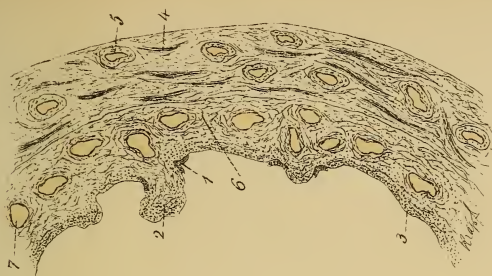

Fig. 3.



rienced by the patient as a dull pain in the pelvis, increased by movement, coughing, straining, etc.); strangury; diarrhea with violent tenesmus; fever (rarely, abscess formation).

The patients soon show evidences of a severe infection. They are pale and hollow-eyed; no appetite; meteorismus—pulse-rate and temperature increase; the abdomen becomes sensitive. These are all symptoms of beginning parametritis and perimetritis.

Vaginal examination (to be most gently carried out) reveals hypersensitiveness of the vaginal vault and resistance behind the uterus. Rectal examination shows a tumor behind or beside the uterus, the differentiation of the two being impossible by palpation. Anatomically, it may be a pyosalpinx, oophoritis, perimetrosalpingitis, perioophoritis, or parametritis.

The process may remain stationary at this point. The intestinal coils, which roof in the pouch of Douglas, become adherent and wall off the exudate from the general peritoneal cavity—peritonitis exsudativa saccata. The inflammatory products may undergo absorption, may perforate into the rectum, or, rarely, may perforate into the vagina. Chills are present. Permanent resistance beside the uterus may be demonstrated.

As sequels may be mentioned dysmenorrhea, sterility, and deviations of the uterus, the intra-uterine treatment of which, as well as the periodic congestions, may produce febrile exacerbations.

If the inflammation proceeds, a general peritonitis occurs with marked meteorismus, great abdominal pain (which may be absent or intense only at times), compression of the rectum, hindered passage of flatus, threatening symptoms of obstruction, vomiting (even fecal), and sometimes profuse fetid diarrheas. The pulse is rapid, small, and irregular.

The patient may die, the fever being no more pronounced than the anatomic changes. The patient may



recover slowly, the pus being absorbed ; or rapidly, the pus emptying externally or into some hollow viscus.

**Diagnosis.**—Ulcers of the vulva, vagina, and cervix are seen most frequently in the puerperium, occurring elsewhere only in children and in severe acute infectious diseases, such as croupous diphtheria and gangrenous vulvitis. The diagnosis is made by the fetid discharge, pain, slight elevation of temperature, and the gray, green, or yellowish covering of the wound. Ulcers situated near the perineum may be due to injuries or ulcerative processes of the rectum ; or to inflammations of the glands of Bartholin, which in rare cases are not of a gonorrheal nature.

Acute colpitis and endometritis, with their concomitants, myocolpitis and myometritis, may be brought about not only by gonorrhea and puerperal infection, but also by a cold followed by menstrual suppression, by septic operative measures, or by acute infectious diseases (influenza and others).

The main symptoms are fever, purulent secretion, hemorrhages, and pain in the interior of the uterus. The cervix is swollen, and the external os is ulcerated, eroded, and covered with purulent ovula Nabothi. (Plate 37, Fig. 2.)

The deeper the process penetrates into the perivascular and interstitial connective tissue of the muscularis, the more violent will be the febrile invasion. This is accompanied by chills, by hypersensitiveness of the enlarged, hyperemic, softened uterus, by dull pelvic pain, and by vesical and rectal pain and tenesmus. If abscesses form later, their presence is detected by fluctuation.

Parametritis seems, to the touch, like a lateral extension of the uterus. In the beginning it has a doughy consistency. The inflammation has invaded the connective tissue surrounding the uterus, and may spread anteriorly alongside of the bladder to the extraperitoneal connective tissue, and even to the connective tissue of the thigh. It may extend



laterally between the layers of the broad ligament to the hollow of the sacrum; or it may go posteriorly, pushing up the serosa of Douglas' pouch and ascending behind the peritoneum, on the iliopsoas muscles, to the renal region.

The tumor is found in some one of the foregoing positions. It is an exudate in the pelvic connective tissue (phlegmon of the pelvis, pelvicellulitis, parametritis of Virchow), and consists of a mucoid swelling and round-cell infiltration of the connective tissue. (Plate 59, Fig. 1; 61, 2; 41, 2.) The exudate is usually absorbed, but scar tissue is left behind, which later binds down and displaces the uterus.

If abscesses form, the pus may burrow its way into the rectum, into the vagina, into the bladder, through the sciatic foramen, along the inguinal canal, or, lastly, through the abdominal wall, pointing above Poupart's ligament.

The overlying peritoneum is usually in a condition of irritation, as is indicated by greater pain, meteorism, diarrhea, and vomiting. The consequent adhesions of the pelvic organs cause sterility. If the peritoneum allows the exudate to escape, a fatal perforative peritonitis will follow. (Plate 39.)

In circumscribed parametritis there may be localized abdominal pain (from the irritation of the serosa), but the violent general pains, the tympanites, and the intraperitoneal exudate are absent. The space of Douglas also remains free. Alongside of the uterus there is at first a hypersensitiveness, then increased resistance, and finally a parametritic tumor of doughy consistency.

For the differential diagnosis from tumors of the pouch of Douglas see § 35.

The diagnosis of peritonitis is based upon the demonstration of an exudate. (Plate 58, Fig. 1.) As long as the process is limited to the pouch of Douglas and is walled off by adhesions at the pelvic inlet (a pelveoperitonitis), the prognosis is far more favorable than when the entire peritoneal cavity is involved.

## PLATE 41.

**FIG. 1.—Acute Purulent Parenchymatous and Interstitial Salpingitis.** Not only the papillæ are proliferated, but also their stroma (1) and the connective tissue of the submucosa (3), and the muscularis (4 and 5) is infiltrated with round cells. The epithelium is partly swollen and partly cast off, the excoriated papillæ adhering and forming small cysts (2). (Original drawing from a specimen.)

**FIG. 2.—Parametritis Acuta of the Broad Ligament.** Both the connective-tissue fibers and the areolar tissue are infiltrated with round cells. This first stage of swelling and suppuration passes later into the second stage—the transformation into scar tissue. Contraction occurs. (Original drawing from a specimen.)

**FIG. 3.—Chronic Oophoritis with Oligocystic Degeneration.** (See Plate 45 and Fig. 35.) The inflammatory disturbances lead to a thickening of the tunica albuginea, producing a cystic swelling of the follicles (1 and 2); the follicular epithelial cells desquamate (10) and the ova die. The older corpora lutea become transformed into corpora fibrosa (8) (or candicantia). Recent hemorrhages and older ones with blood pigment (9) are found in the stroma (13). The tortuosity (5) of the vessels (4) is a physiologic peculiarity of the ovary; in places perivascular round-cell accumulations can be seen (6). The follicles are surrounded by the tunica fibrosa (7); the surface of the ovary is covered with cuboid germinal epithelium (3). (Original drawing from a specimen.)

---

As an intermediate stage we sometimes observe acute oophoritis or salpingitis in the shape of swollen, exquisitely sensitive adnexa, in the bimanual palpation of which the greatest gentleness must be exercised in order to avoid the rupture of an abscess or the destruction of an existing encapsulation. (Plates 39, 44, 59, Fig. 3.)

General peritonitis may follow an acute or a chronic course; the latter is designated as peritonitis pyofibrinosa, and has a more favorable prognosis.

The onset of the inflammation is marked by a protracted chill, and is followed by diffuse abdominal pain. The abdomen may be so tympanitic and distended that

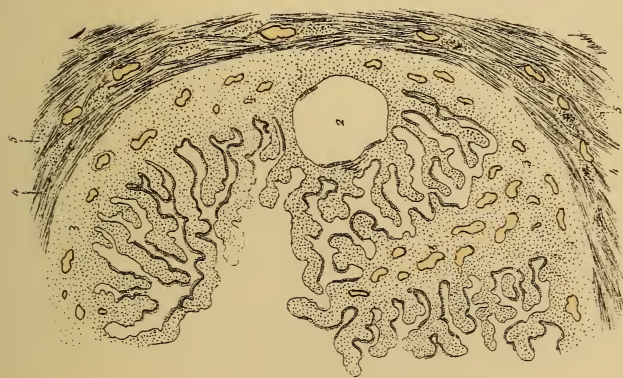


Fig. 1.

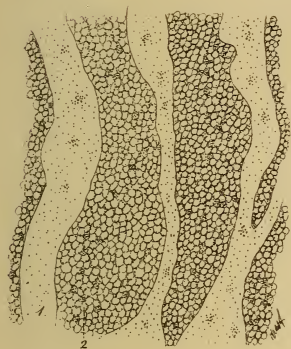

Fig. 2.

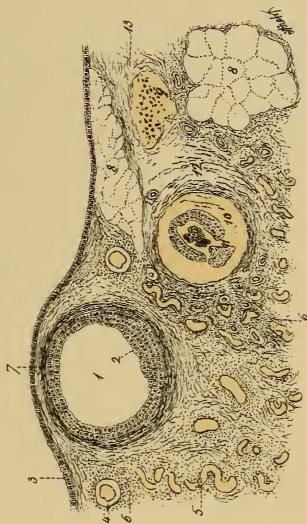

Fig. 3.



dyspnea is caused by the pushing-up of the diaphragm. Vomiting and constipation are present, giving place to a profuse fetid diarrhea. Euphoria, together with a rapid rise of the respiratory and pulse-rates (not always of the temperature, however), is always suspicious.

**Treatment.**—All disturbances of menstruation are to be avoided. Absolute asepsis is to be observed in all operative measures—therapeutic manipulations (sounds) and in the care of pessaries. The lighting-up of old inflammatory residues by exploratory procedures is particularly to be avoided.

Ulcers of the vulva are to be cauterized (formalin) and treated with iodoform, airol, nosophen, or iodoformogen, or protected by compresses soaked in oil of turpentine. The inflammatory edema is to be treated by moist applications (solution of aluminum acetate).

Ulcerations of the cervix are to be cauterized with formalin and treated with irrigations of aluminum acetate, corrosive sublimate, or lysol. Dry powders may be employed to disinfect the parts, although this method is more troublesome, because of the necessity of daily repetition.

In acute endometritis and myometritis the patients, and especially the genital organs, should not be disturbed. The treatment consists of rest in bed, mild laxatives, warm fomentations, warm vaginal irrigations with potassium permanganate, weak solutions of lysol (0.25%), normal saline solution, or mucilaginous decoctions, using about a liter of fluid, carrying the tube high up (gently), and not elevating the douche bag very much.

If the inflammation increases, the fomentations are to be replaced by frequently repeated cold applications or by the ice-bag or ice-coil.

Abscesses should be opened only when they are easily accessible. They are usually situated in the parametric tissues.

Acute parametritis is to be treated with the ice-bag, calomel, and blue ointment (1.0 applied every two hours



## PLATE 42.

**Double Pyohydrosalpinx, Chronic Adhesive Perimetritis and Oophoritis.** Both tubes are almost filled with pus; the fimbriated ends, walled off both from the isthmus and from the peritoneal cavity, are transformed into cysts. (Original drawing from a specimen of Professor Beck's.)

to the point of salivation), followed by warm fomentations and enemata.

In acute peritonitis several ice-bags upon the abdomen and laxatives in the stage of constipation (infusion of senna; calomel—at first 0.2 to 0.5, later 0.05 to 0.1, at a dose). The diet should be liquid and nutritious. Stimulants, which should contain more alcohol when the patients are accustomed to wine or beer. As soon as free evacuations occur opium is given, or inunctions of blue ointment together with calomel in small doses. Free diaphoresis is excited, and the activity of the skin is increased by cool sponging. [Cases of acute peritonitis should be carefully watched in order not to neglect operative measures. Localized peritonitis with abscess formation always indicates, and promptly responds to, surgical treatment. Acute diffuse peritonitis, however, will usually prove fatal, but that fact warrants early surgical treatment, although most cases succumb.—Ed.]

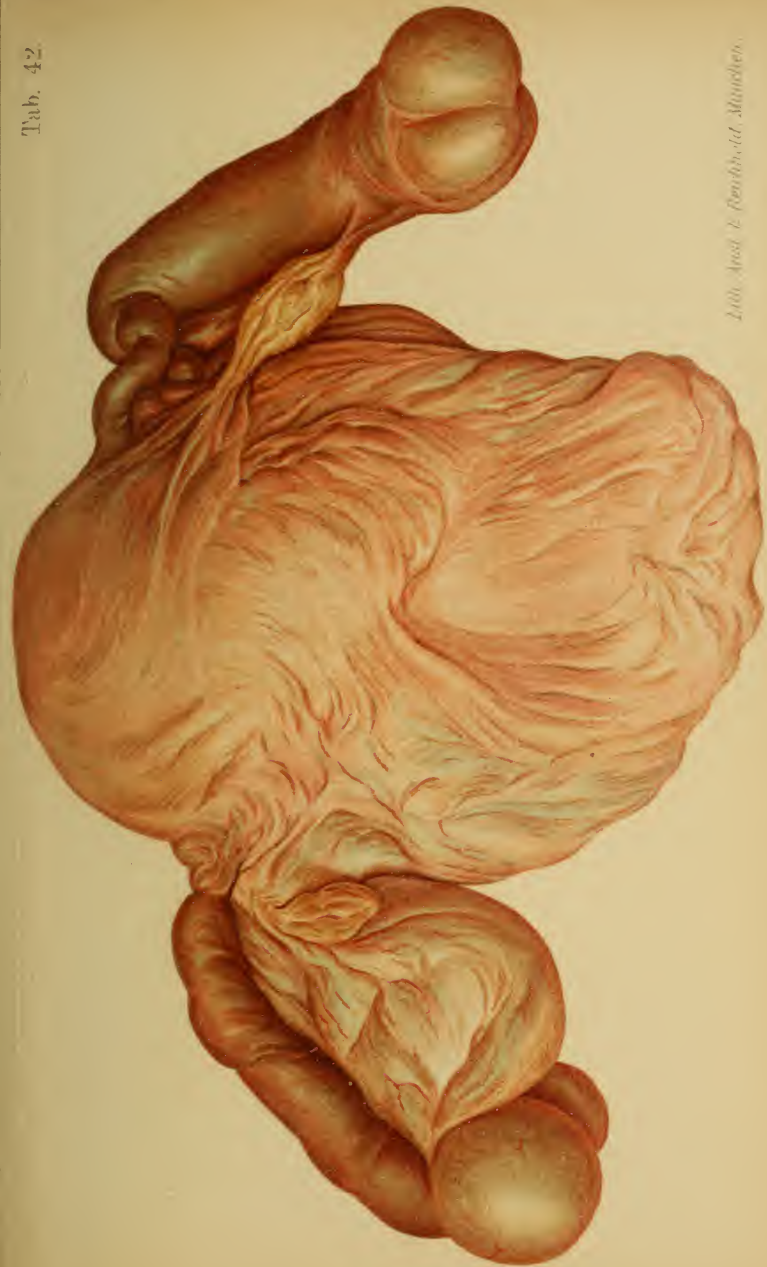### § 16. CHRONIC SALPINGITIS.

**Etiology.**—For definition and anatomy see explanations to Plates 40–43, 44, 46, 59 (Fig. 3), and 74. The most frequent causes are puerperal and gonorrheal inflammations; in every case of endometritis the tubes are not necessarily involved.

**(a) Parenchymatous Catarrh of the Tubes (Plate 40, Fig. 1), with Atresia of the Ostia: Hydrosalpinx.**

The secretion accumulates in the abdominal portion, flattens the papillæ of the mucous membrane and their cylindric epithelium, sepa-







rates the muscle-fibers, and in this way thins and stretches the tubal wall. The tube is held by the serous duplicature of the broad ligament, and presents a spiral appearance with multiple constrictions, as shown in plates 42 and 44. Sometimes the hydrops tubæ (profluens) empties itself periodically into the uterus.

**Symptoms.**—There are no characteristic symptoms worthy of mention, except anomalies of menstruation, sterility (since the disease is usually bilateral), pressure effects, and perisalpingitic pain.

**Diagnosis.**—As long as pelvic exudates are absent, bimanual palpation reveals a round, fluctuating, trumpet-shaped tumor, peripherally swollen, extending from an angle of the uterus, and not rarely lying in the vesico-uterine space. The exclusion of a tumor of the ovary is important. (Plate 74.)

**Treatment.**—In an extreme degree of swelling, celio-salpingotomy, for the purpose of removing the tubal sac; or salpingostomy: *i. e.*, restoration of the lumen of the tube by opening the ostium abdominale and stitching the serosa to the mucosa.

**(b) Parenchymatous and Interstitial Purulent Inflammation of the Tubes** (Plate 41, Fig. 1), **with Atresia of the Ostia: Pyosalpinx.** (Plate 40, Fig. 3; Plates 42 and 44; Plate 59, Fig. 3; Plate 74.)

The tube is bluish-red and thickened, not only from a passive dilatation, but also not rarely from proliferation of the muscularis. The inflammatory process passes either through the abdominal ostium or through the tubal wall to the peritoneal covering, and thence to the pelvic peritoneum and ovary. It always remains circumscribed, the organs contracting adhesions that often contain purulent deposits. The gonorrheal inflammation is usually bilateral.

We differentiate histologically:

1. *Acute catarrhal parenchymatous salpingitis* with proliferation of the epithelium.

2. *Acute purulent parenchymatous and interstitial salpingitis* with partial desquamation of the epithelium and inflammatory infiltration of the stroma.

## PLATE 43.

**Chronic Adhesive Perimetritis and Salpingitis with Uterine Myomata.** A cross-section shows the marked thickening of the tubal wall and exposes to view the unopened ovarian abscess, which is adherent to the tube. (Original water-color.)

---

3. *Chronic interstitial salpingitis*, contraction from the connective tissue that replaces the muscularis. The tube loses its elasticity.

From agglutination of the tubal ostia the first class of cases gives rise to hydrosalpinx; the second and third, to hematosalpinx and pyosalpinx.

**Symptoms.**—Pain at the side of the uterus, becoming worse at the menstrual epoch and when the intra-abdominal tension is increased. Sterility, from the usual combination with oophoritis. Fever (in gonorrhea, only after exertion or excitement).

**Prognosis.**—Conception is impossible. The patient is always threatened with peritonitis from perforation. Gonorrheal pyosalpinx does not rupture easily; the septic form does.

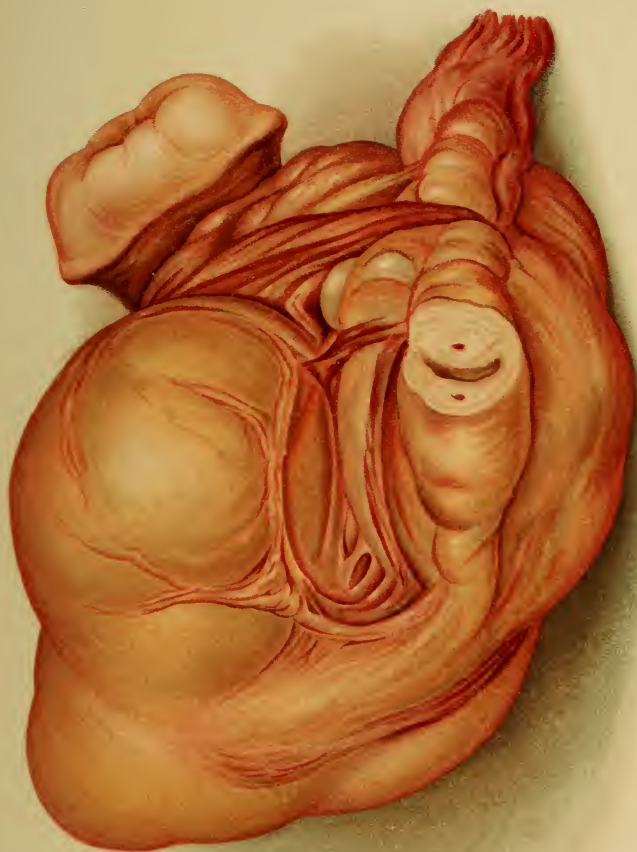**Diagnosis.**—By bimanual palpation. (See the differential diagnosis of the retro-uterine tumors under Ovarian Cystomata, and Plate 74, Figs. 1 and 2, and Plate 59, Fig. 3.)

**Treatment.**—Celiosalpingectomy, stitching the pus sac to the abdominal wall (Hegar, Kaltenbach) and pressing up the uterus from the vagina (Gusserow) are indicated. If the pyosalpinx is not adherent, its rupture can usually be avoided.

If there is distinct fluctuation in the vagina or abdominal wall, free incisions should be made and iodoform gauze drainage established. (See Chronic Pelveoperitonitis.)

## § 17. CHRONIC OOPHORITIS.

**Etiology.**—Suppurative oophoritis, due to lymphatic







absorption from the uterus and tubes, and caused by traumatic or operative septic infection, has been mentioned in connection with peritonitis in a preceding section.

Ovarian abscesses, however, usually follow purulent

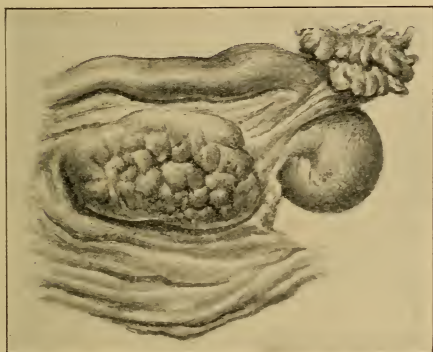

Fig. 34.—Senile cirrhotic atrophy of the ovary.

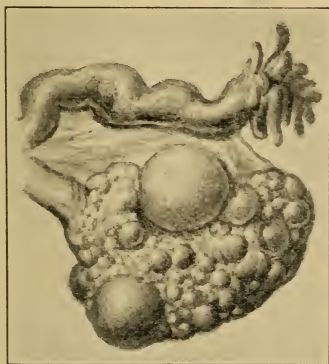


Fig. 35.—Oligocystic degeneration of the ovary.

inflammations of the tubes. (Fig. 36.) This oophoro-salpingitis is combined with perimetrosalpingitis, perimetro-oophoritis, and pyosalpinx, forming, together with encapsulated ovarian and peritoneal pus sacs, a large ag-

## PLATE 44.

**Pelvic Peritonitis, Perioophoritis, Perisalpingitis and Right-sided Pyosalpinx.** View of the pouch of Douglas. Pseudoligaments fix the uterus and its adnexa to the sigmoid flexure. The left tube is bent at an angle, the right tube shows inflammatory redness, and is transformed into a pyosalpinx by the agglutination of the abdominal ostium. The globular divisions of the tumor are characteristic. (See Plates 40, 42, 59, 74.) (Original water-color.)

---

glutinated tumor (pyo-oophorosalphinx). As in purulent salpingitis, the cause is to be found in a septic or gonorrheal mixed infection.

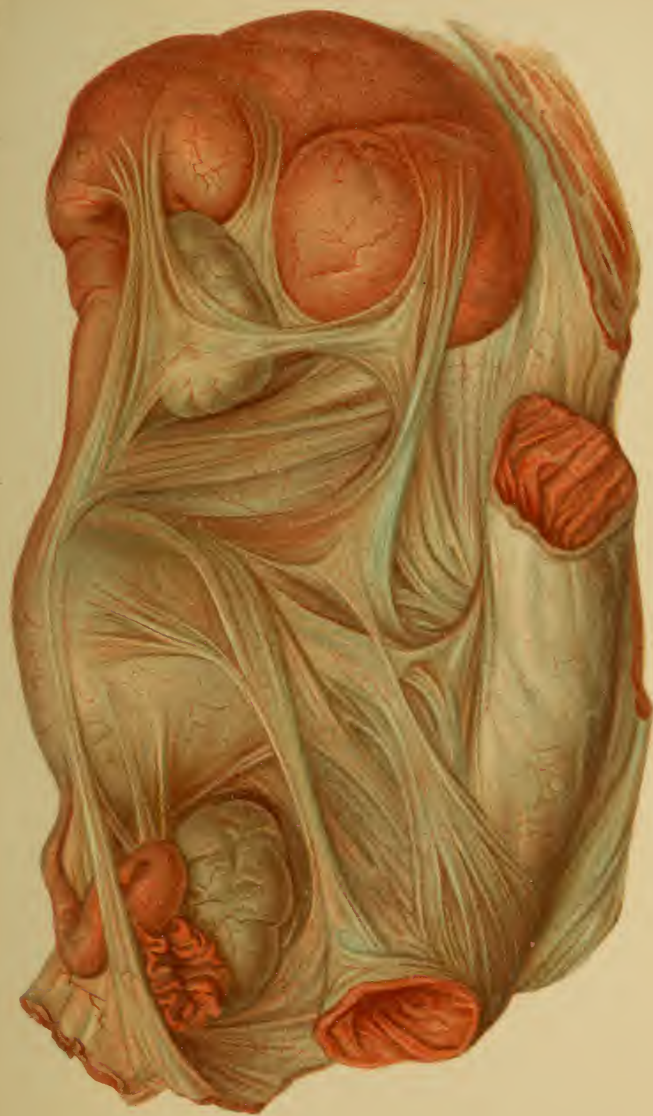Sclerotic oligocystic ovarian degeneration (Plate 45 ; Plate 41, Fig. 3 ; and Fig. 35), may occur alone, leading to destruction of all the follicles, so that the organ becomes hypertrophic, cicatrized, and dense from the formation of chronic inflammatory connective tissue. (Plate 44 and Fig. 34.)

**Symptoms.**—These are due partly to the uterine phenomena of dysmenorrhea and partly to hysteria.

The predominant symptom is pain, felt in the lumbar and pelvic regions and radiating to the groins and thighs. This pain increases at the menstrual periods, which are very irregular, sometimes oligomenorrhea or amenorrhea, sometimes menorrhagia, being present. It occurs far less often as intermenstrual pain. It is increased by exertion and constipation, and may present itself as a tubal colic.

**Diagnosis.**—A hypersensitiveness of the adnexa may be found by bimanual examination ; the tube is swollen, and the ovary is enlarged. These organs should be carefully palpated by the methods demonstrated in Plates 21–23. The ovary is frequently dislocated and bound down behind and below the uterus. (Plate 19, Fig. 1.)

One must not be misled by tenderness of the overlying parts. In lumbo-abdominal neuralgias the belly wall is hypersensitive ; certain hysteric affections (“ ovarie ” of





Charcot) may give rise to pain in a healthy ovary, or in the neighboring portions of the broad ligament or vaginal vault.

In perimetrosalpingitic processes the individual organs can not be differentiated.

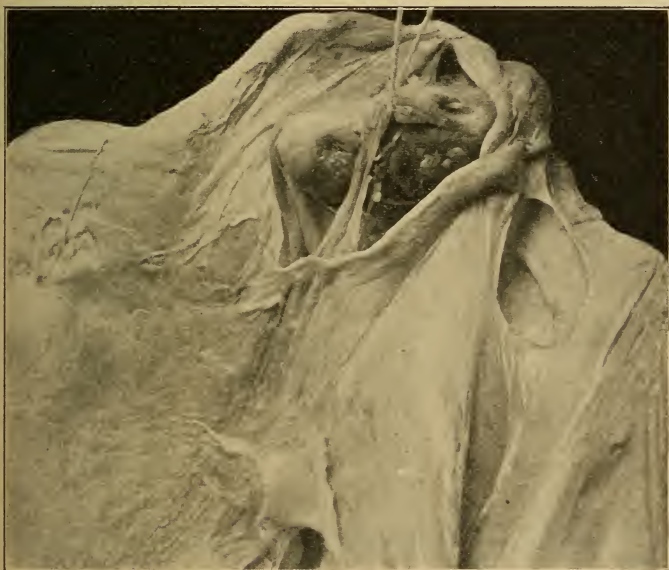

Fig. 36.—Adhesive perioophorometrosalpingitis. The entire posterior peritoneal surface of the uterus and the broad ligaments is covered by adhesions. They form a pocket in which the ovary was completely concealed. It was only by holding up the ovary by means of a thread that it was rendered visible in the illustration. The fimbriated end of the tube is completely occluded and destroyed by the flap-shaped adhesions. An analogous case is described in the "*Mon. f. Geb.*," 1898, in which the ovary was still more freely movable, and could be distinctly palpated as it slipped in and out of a similar pocket. (Photograph from an autopsy at the Heidelberg Path. Inst.)

**Treatment.**—Avoid injurious congestions by absolute rest in bed, by sexual continence, and by securing regular evacuations of the bowels and bladder.



## PLATE 45.

**FIG. 1.—Pelvic Peritonitis.** The uterus is displaced anteriorly and to the left. Adhesions bind it to the bladder and intestine and fix the tubes and ovaries. The left ovary is enlarged, and shows oligocystic degeneration: *i. e.*, all the follicles become cystic, with desquamation of the germinal epithelium and destruction of the ova. (See Plate 41, Fig. 3, and Fig. 35.) The other ovary is not enlarged, and has a scarred surface from frequent ovulation. (Fig. 34.) These plastic inflammations are due to gonorrheal salpingitis, or to metritis or parametritis from puerperal or operative lesions of the genital mucous membrane. They may start in other organs and sink down into the pouch of Douglas, which is the lowest space in the abdomen.

**FIG. 2.—Left-sided Dermoid Cyst Perforating into the Rectum.** (Original drawing made from the data obtained in palpating a case in the Munich Frauenklinik.) The hair contained in the tumor passes into the rectum through the perforation. Dermoid cysts occur most frequently in the ovary, and contain sebaceous matter, hair, teeth, or even complicated organic structures (brain and nerve masses, portions of the eye, mandible with teeth, etc). (See Plate 79, Fig. 4.)

---

Removal of the original cause: Treatment of the uterine inflammation, vaginal irrigations, but no intra-uterine treatment.

For the pain: Rest in bed; the ice-bag, which may be subsequently replaced by warm fomentations and baths. In certain cases hot vaginal irrigations ( $117^{\circ}$  to  $122^{\circ}$  F.) or hot sand-baths are of value. If the patient is up and about, the organs are to be supported by Mayer's ring (the lever-pessaries press upon the diseased adnexa), or vaginal tamponade (the fornix especially) with iodoform gauze, or depletives, such as potassium iodid, ichthyol, or glycerin, in vaginal suppositories or upon tampons.

If the pain is unbearable or if frequent elevations of temperature occur: Removal of one or both ovaries, usually with the corresponding tube. When the pelvic organs are completely agglutinated, the adhesions consisting of rigid scar tissue, the uterus also is to be re-



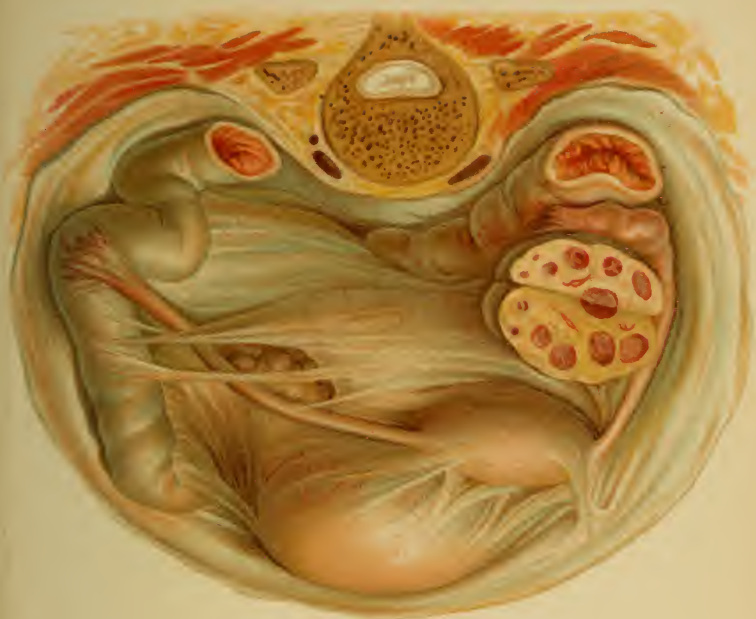

Fig. 1.

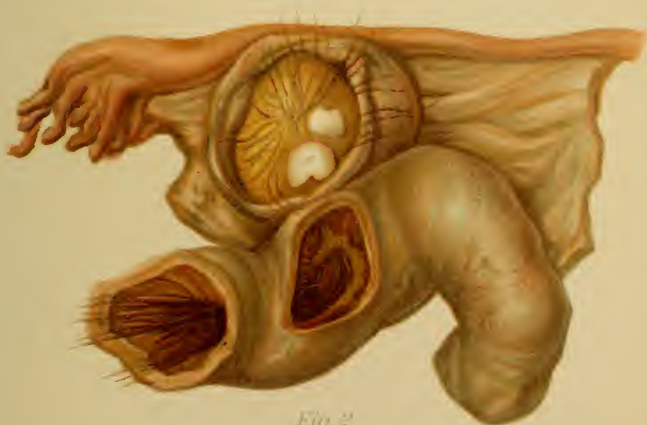

Fig. 2.



moved. Ovariectomy is indicated only when persistent treatment for years has failed.

If all the subacute phenomena have disappeared (occasional chilliness, great pain), massage and compression are useful.

#### § 18. CHRONIC PERIMETRITIS, OOPHORITIS, AND SALPINGITIS. CHRONIC PELVIC PERITONITIS.

**Anatomy.**—See explanations to Plates 40-45 ; 59, Fig. 3 ; 74, and Diagnosis of Pyosalpinx.

**Etiology.**—In chronic pelveoperitonitis the tube is by far the most frequent avenue of infection (mostly gonorrheal) ; small quantities of serum, mucus, or pus escape from the ostium abdominale. The infection may also occur through the lymphatics. Genital tuberculosis is a not infrequent cause.

Catarrhal salpingitis gives rise to perimetrosalpingitis serosa ; purulent salpingitis, to purulent pelveoperitonitis saccata. Suppurating tumors (dermoids) furnish an occasional source of infection.

**Symptoms and Prognosis.**—Sudden violent pelvic pain (from the escape of pus into the abdominal cavity), with chill, vomiting, tympanites, small pulse, and drawn features. The temperature rises and assumes a remittent character. There are rectal and vesical disturbances, pericystitis, and periproctitis. If an abscess breaks through into the bladder, sharp pain and purulent cystitis result.

The fever declines as the exudate becomes encapsulated ; the chills reappear, however, as soon as the perforation of a hollow viscus is threatened.

The premonitory symptoms are intestinal tenesmus, vesical pain, and foul-smelling feces and urine.

When perforation has occurred, the process has by no means terminated ; from now on there are periods of euphoria, alternating with chills and purulent discharges, the patient becoming gradually weaker—"hectic fever."

## PLATE 46.

**Genital Tuberculosis of Both Tubes (the Right One Cut Open), of Both Ovaries, and of the Pouch of Douglas.** (Original water-color from a specimen.)

---

Perforation into the peritoneal cavity is rarely followed by immediate death.

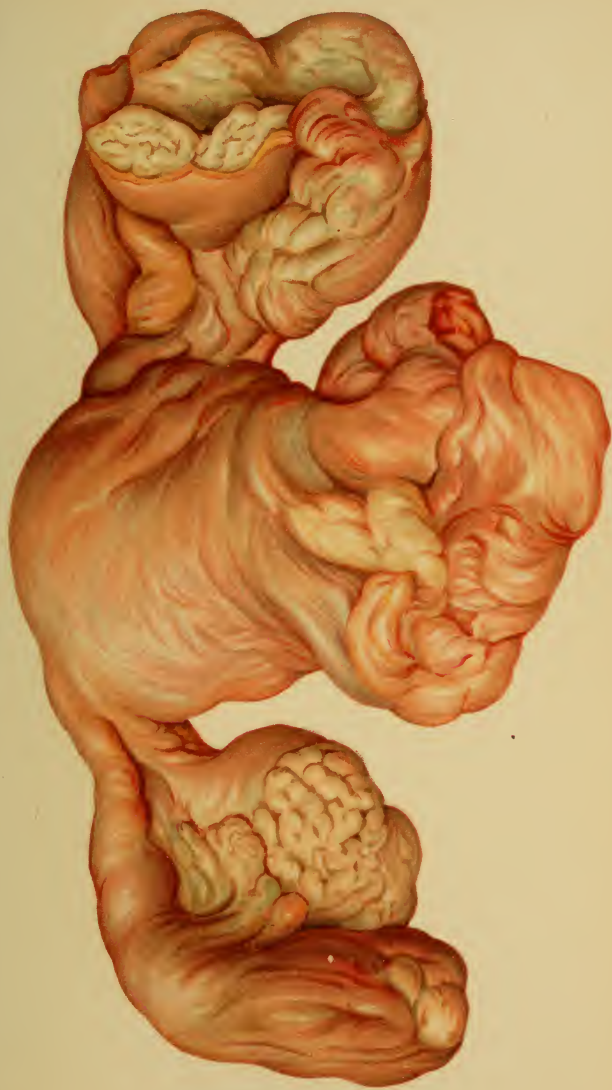In relatively favorable cases the encapsulated exudate becomes absorbed (*peritonitis indurata*), but from the numerous adhesions, and consequent organic displacements and irritations, there remain serious permanent disturbances of health—sterility (abortion, extra-uterine pregnancy), hysteria, menstrual colic, menorrhagia, and profuse discharge. The gonorrheal inflammation is especially liable to recur.

**Diagnosis.**—In addition to the hypersensitiveness of the abdomen and of the vaginal vault, bimanual examination causes marked pain, especially on moving the uterus.

The adhesions are recognized from the fact that the uterus has lost its range of motion, being bound down in some pathologic position. (See *Displacements of the Uterus* and accompanying plates.)

Exudates never exist without peritoneal pain, fever, etc. They are usually found in the pouch of Douglas, and may be palpated from the rectum or from the posterior vaginal vault. The adnexa are embedded in the exudate. (See *Retro-uterine Tumors under Ovarian Cystomata*.) If the pouch of Douglas is obliterated, the exudate occurs above the pelvic inlet—in the iliac fossæ. In other cases the mass may reach as high as the umbilicus.

**Treatment.**—The acute form is discussed in § 16. In the chronic form every therapeutic manipulation of the genitalia is contraindicated. This includes the introduction of pessaries and of the intra-uterine sound, scarification of the cervix, prolonged bimanual examination, etc.







Uterine catarrh is to be disregarded ; abscesses are to be opened only when perforation is threatened.

Frequent rest, sexual abstinence, and rather liquid stools are to be secured. For the pain and fever : horizontal position, warm fomentations, lukewarm vaginal injections of mucilaginous or narcotic solutions, introduction of vaginal suppositories containing anodynes (cocain, extract of belladonna, morphin). Later, warm sitz-baths ( $99^{\circ}$  F. and gradually cooler).

To stimulate absorption : Compression, hot vaginal injections ( $117^{\circ}$  to  $126^{\circ}$  F.). Absorbents, such as potassium iodid, ichthyol, iodoform, glycerin tampons, mud baths, salt baths (Kreuznach, Nauheim, Oeynhaus, Tölz). Adhesions may be stretched at first by rectal injections (as recommended by Hegar, gradually increasing amount and decreasing temperature) ; later, if the parts are absolutely painless, massage. (See Plates 21–23.)

In tubercular peritonitis : Simple celiotomy, with or without applying iodoform to the serosa. The opening of the abdominal cavity by posterior colpotomy has proved of value (Löhlein).

In gonorrheal peritonitis : Removal of pyosalpinx and diseased ovaries, as far as enucleation is possible. If pelvic abscesses cause an increasing impairment of the general health, they must be enucleated or freely drained.

The parts may be best surveyed after a celiotomy. A conclusion may then be drawn as to whether it is better to open and drain the abscess from the vagina, or through the abdominal wall.

The posterior vaginal vault may be directly incised, and the thickened peritoneum stitched to the vaginal mucosa. There is danger of infection from putrefactive organisms from the rectum.

If perforation into the bladder occurs, it may be necessary to establish a vesical fistula, either suprapubic or vaginal.

If the abscess, with or without vaginal fistula, has old,

## PLATE 47.

**Cystitis; Ureteritis (Pyonephrosis) as a Result of Lithiasis; Metritis with Endometritis Fungosa; Cervicitis with Marked Dilatation of the Cervical Canal; Vaginitis.** The bladder is dissected away and displaced to the left; its hyperemic mucous membrane and thickened walls are exposed to view. On the right may be seen the ureter, cut across near its insertion into the bladder. It shows inflammatory redness at this point, while just above there is an ulceration from which an impacted phosphatic calculus (depicted below) was removed at autopsy. The ureter was markedly dilated above this point, as a result of the obstruction and of the congestive narrowing of the canal at its entrance into the bladder. The endometrium shows marked proliferation and edema; the mucous glands and the uterine cavity are filled with mucus. In the cervical canal a tough mucous plug has been left in position, covering the narrow external os. The internal os is also quite narrow. The vaginal mucous membrane is inflamed. (Original water-color from a specimen at the Heidelberg Path. Inst.)

---

hardened walls difficult of removal through an abdominal wound, vaginal hysterectomy (Landau, Péan); drainage.

‡ 19. **CHRONIC PARAMETRITIS (PHLEGMON OF THE BROAD LIGAMENTS) AND PARACOLPITIS.**

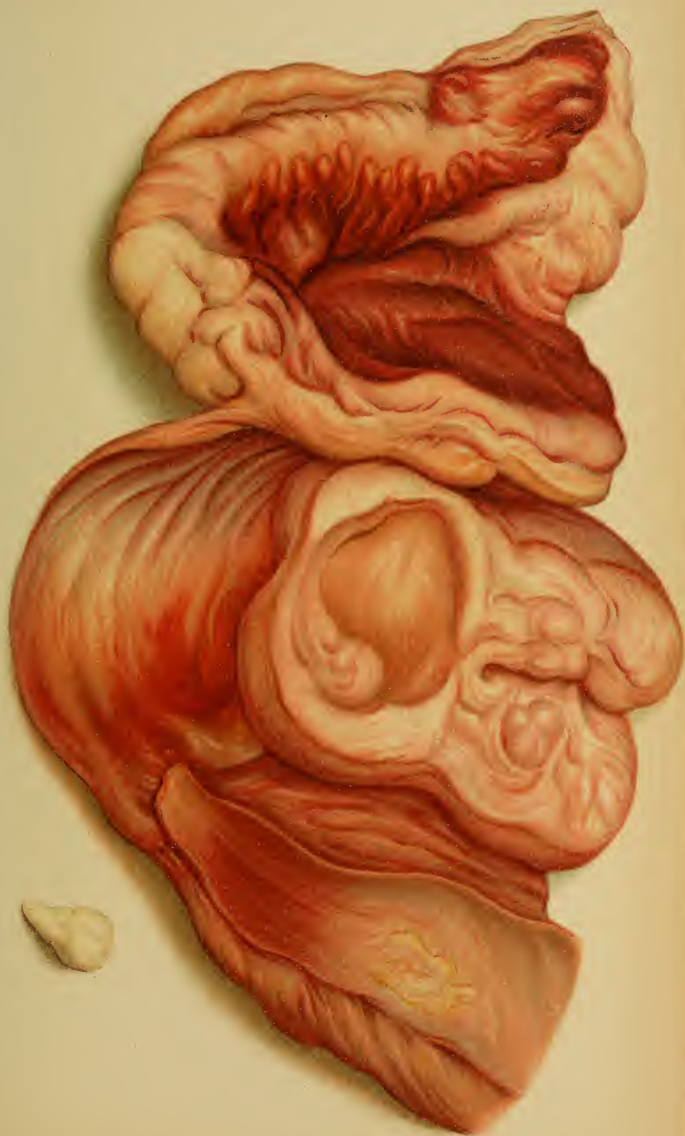There are two forms:


(a) A chronic process, arising from the acute parametritis just described.

(b) Atrophic chronic parametritis (Freund).

**Etiology.**—(a) See § 15. (b) Overstimulation of the genital nerves by prolonged and profuse secretion (frequently repeated pregnancies, with lactation during the intervals, sexual excesses). Following upon periphlebitic processes, a connective-tissue change resembling cicatricial atrophy commences in the base of the broad ligament and gradually involves the entire genital tract.

**Symptoms and Diagnosis.**—(a) An acute parametritis





that has become chronic may take one of the following courses: The exudate may become thick, remaining for months or years; it may perforate, and, as it has not entirely undergone suppuration, it may discharge from time to time; or, more frequently, it may undergo absorption and cicatricial contraction. These contractions may also follow scars from noninfected interstitial lesions during delivery. They result in displacements and distortions of the uterus and its adnexa. (See §§ 9 to 11 and Plates 23; 41, 2; 55, 1; 59; 62.) These masses of scar tissue are less sensitive than those due to perimetritis. They may be found about the vaginal fornices or alongside of the uterus; the sacro-uterine ligaments may be shortened, limiting range of motion of the uterus.

(b) *Symptoms of parametritis chronica atrophicans*: Spontaneous pelvic pain and tenderness of the bladder and rectum if their surrounding connective tissue is involved in the process. Abrogation of the sexual functions: oligomenorrhea and dysmenorrhea. Nervous irritability, depression, hysteria, and disturbances of general nutrition.

It is difficult to move the organs about in the sensitive and firm connective tissue.

**Treatment.**—(a) *Chronic septic parametritis*: Abscesses are to be incised only when they give rise to fluctuation beneath the skin or mucous membrane, as in chronic pelveoperitonitis. Absorption is to be stimulated by potassium iodid, glycerin, ichthyol, iodoform, hot vaginal injections, Hegar's enemata, mud-baths, and hot sand-baths. Massage is indicated in some cases. Elastic traction on the cervix by means of a bullet-forceps is occasionally of some benefit. No intra-uterine operations should be performed. Secure easy and regular evacuations of the bowels.

(b) *Parametritis atrophicans*: Hot vaginal douches and sitz-baths; massage; repeated mechanical intra-uterine stimulation and mild intra-uterine irrigations (soda, Fritsch) are measures to be employed.



## PLATE 48.

**Chronic Cystitis with Acute Exacerbations.** Mucous membrane atrophic, partly necrotic, and thrown into plump, rigid folds by the marked thickening of the bladder-wall. (Original water-color from an autopsy at the Heidelberg Path. Inst.)

---

## § 20. GENITAL TUBERCULOSIS.

**Definition and Etiology.**—The infection with the tubercle bacillus may be primary or secondary; the latter is the more frequent. On the whole, genital tuberculosis is rare. Gonorrheal, septic, and mixed infections favor its development.

*Primary infection* may result from cohabitation with a man who has genital tuberculosis, from an infecting digital examination, from infected linen, etc.

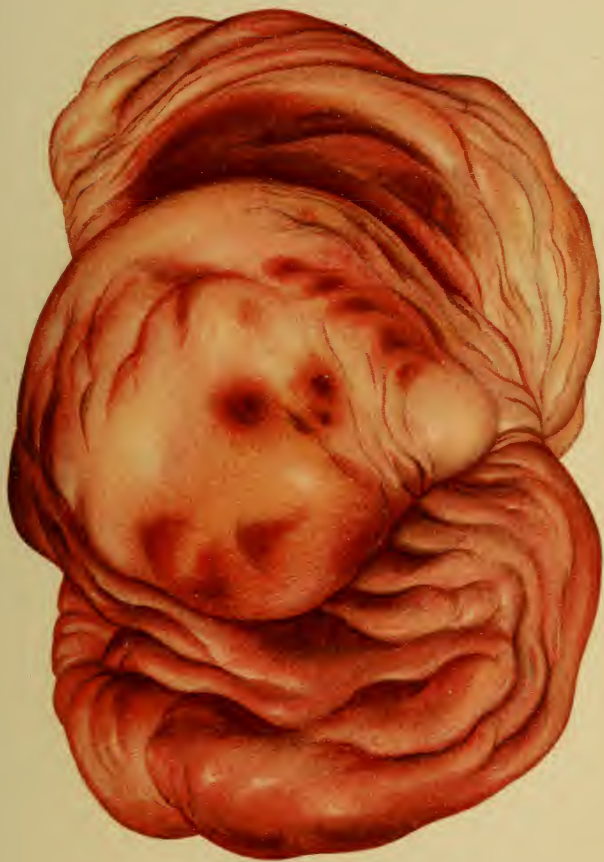
*Secondary infection* may occur by metastasis from the intestines or from the lung, by infection of the tube from the peritoneum (the most frequent cause), or from the adhesion of a tubercular loop of intestine.

The mucous membrane of the tube is by far the most easily infected; the process readily extends from here to the ovaries (by way of the peritoneum, according to Schottländer), or, less rarely, to the uterine mucous membrane, the menstrual changes evidently interfering with the deposit of the bacilli. The cervical and the vaginal mucosa are very rarely affected, the former being protected by its secretion, the latter by its dense epithelium. Here, as in the vulva, fissures form the sole avenues of entrance for the primary invasion of the bacilli.

Tuberculosis of the vesical mucosa, following a general or a genital tuberculosis, is not of more frequent occurrence.

**Anatomy.**—(1) General peritoneal tuberculosis, which also affects the genital serosa; (2) tuberculosis of the tubes, ovaries, or corpus uteri; (3) the very rare affections of the cervical and vaginal mucosa; (4) the lupous forms seen on the vulva.







Subacute and chronic inflammatory phenomena (ascites, serofibrinous exudate, formation of pseudoligaments) occur, and the peritoneum becomes covered with tubercles. The tubes are fixed in the pouch of Douglas and their ostia are agglutinated. As the caseous secretion can not be discharged, a pyosalpinx is formed. The walls are reddened, thickened, and infiltrated with yellow tubercular granulations. Caseous areas, very rarely miliary tubercles, are found in the ovaries; they seem to arise most frequently in the stroma. Schottländer also found follicular tuberculosis experimentally; he further found microscopic tubercular changes in the apparently healthy ovaries of tubercular women.

The cylindric epithelium is at first well preserved, only a few cells showing mucoid and granular degeneration. The epithelial layer, however, is finally replaced by a caseous coating, and the muscularis is infiltrated with granulation tissue containing giant cells. The vessels show chronic inflammatory and hyaline changes. Koch's bacilli may be demonstrated, although sparingly present.

In uterine tuberculosis the wall is thickened by the edema of the muscularis; the mucous membrane is totally destroyed and is transformed into a caseous mass; scattered tubercles may be seen. The ulcerative process is sharply limited at the internal os.

Tuberculosis of the vagina and cervix likewise presents irregular ulcerations surrounded by tubercles and a dirty yellow exudate.

Lupus vulvæ usually commences on the labia as small, flat, reddish tumors, which ulcerate. Although they infiltrate more diffusely, they do not extend so rapidly nor secrete so profusely as do syphilitic ulcers. The scars are reddish-violet. The microscope shows no hypertrophy of the papillæ and skin, but a small-cell infiltration about the vessels.

Tuberculosis of the bladder occurs as tubercular infiltration or in the form of ulceration.

The **symptoms** and **diagnosis** of the tubal affections are the same as those of salpingitis or pyosalpinx.

Uterine tuberculosis produces the same phenomena as ordinary metritis, but the organ enlarges more quickly and to a greater degree. The discharge is caseous. The differential diagnosis, from corporeal carcinoma especially, may be aided by curetment, but it is by no means easy: giant cells, tubercles, demonstration of bacilli, or inoculation of the peritoneal cavity of a rabbit with the uterine secretion. An accompanying tubal affection is strong corroborative evidence.

In the beginning of the disease there is amenorrhea, interrupted by blood-tinged or mucopurulent discharges, and a sensation of weight and pressure in the pelvis.

## PLATE 49.

FIG. 1.—**Syphilitic Ulcer of the Vaginal Cervix.** Lardaceous exudate; swollen, markedly and sharply cut edges. General inflammatory hyperemia of the cervix. (From Mraček.)

FIG. 2.—**Syphilitic Ulcers of the Vaginal Mucosa.** Typical **[-]-form**, the vaginal walls coming in contact. (From Mraček.)

---

In vulvar, vaginal, and cervical tuberculosis the bacilli are to be demonstrated, the microscopic changes in excised pieces studied, and the general condition of the patient taken into consideration.

*Peritonitis.*—Ascitic fluid of a high specific gravity, straw-yellow color—exploratory laparotomy shows confluent tubercles. It must, nevertheless, be remembered that some forms of chronic peritonitis of nontubercular origin show confluent nodules.

**Prognosis.**—Grave, just as in tuberculosis of the uro-poietic apparatus. If an organ is primarily affected, it may be extirpated. We are not yet sufficiently acquainted with the ultimate results from these operations.

**Treatment.**—Extirpation with a good result is possible (Hegar, Werth, Péan) if the disease is limited to the tubes and uterus; if there are no tubercular peritoneal pseudomembranes; and if the general condition, of the lungs especially, will allow of the operation.

If only the tubes are diseased, they are to be removed, together with the ovaries, by celiotomy. The peritoneal cavity is protected from infection by bringing the tumor outside of the abdominal wound and using elastic ligatures. If the hemorrhage is uncontrollable, incise the posterior vaginal vault and pack Douglas' pouch with iodoform gauze (Wiedow).

If the uterus is affected as well, and is not too voluminous, removal per vaginam should be practised.

If contraindications exist, the pyosalpinx is to be opened from the vagina and drained with iodoform gauze;

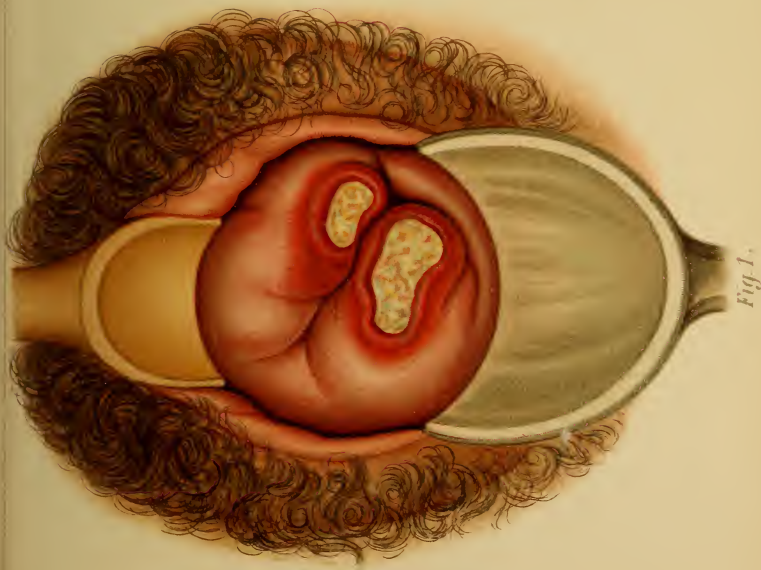



Fig. 1.

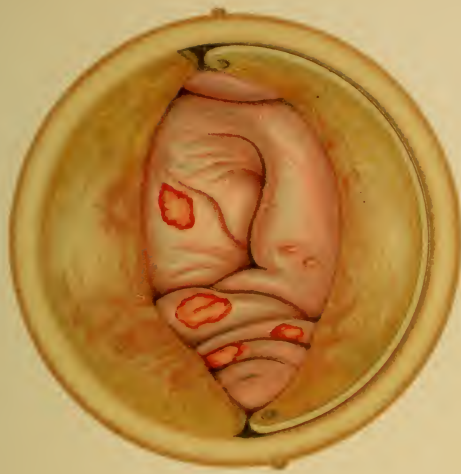

Fig. 2.

Lith. Anst. v. Reichhold München





the uterus is to be cureted and the raw surface covered with iodoform (iodoform-blower).

Vaginal ulcers and vulvar lupus are to be excised or cauterized with the hot iron, fuming nitric acid, or caustic potash, and dusted with iodoform.

Tuberculosis of the peritoneum is treated by celiotomy.

Ulcers of the bladder: First determine the condition of the kidneys. A suprapubic cystotomy is performed, the ulcers are excised, and the wound is packed with iodoform gauze until it closes spontaneously. [The facility with which circumscribed areas of ulceration may be treated through the endoscope renders cystotomy less frequently necessary.—ED.]

## § 21. VENEREAL DISEASES.

### 1. *Ulcus Molle* (Soft Chancre).

**Diagnosis.**—These round, multiple, sharply circumscribed ulcers occur in from one to four days after exposure, and usually affect the vulva, occurring at the position of a small tear or herpetic ulceration. They are rare in the vagina and upon the cervix. The ulcer is bathed in pus; its edges are undermined, soft, and reddened. It may be the seat of diphtheric inflammation or of a rapid destructive ulceration—*ulcus gangrænosum*. It may heal at the point of infection (as usual with a scar), yet spread further by serpiginous ulceration.

The infection is a local one, stopping at the inguinal glands, which undergo suppuration (chancroidal bubo) and are very sensitive.

**Treatment.**—Cauterize the ulcer with fuming nitric acid or chromic acid and treat it antiseptically. Buboec are either to be freely incised or enucleated, and dusted with iodoform.

### 2. *Ulcus Durum* (Hard Chancre); Syphilis.

**Diagnosis.**—The first lesion is a small, single ulcer, in which a papule develops three or four weeks after exposure. Its characteristic peculiarity is that it neither heals nor grows larger, but becomes surrounded by a hard infiltration. Its most frequent situation is upon the posterior commissure, and, next in order, upon the cervix, but it also occurs in the vagina. (Plate 49.)

As a secondary affection, multiple, indolent, inguinal buboes appear, which do not suppurate (differential point from the nonsyphilitic buboes). The infection spreads from here to the abdominal glands. Flat condylomata appear on and about the vulva, extending to the

## PLATE 50.

**Papular Gummata of the Vulva, of the Anus, and of the Inner Side of the Thigh.** Some of them show areas of central necrosis. (From Mraček.)

---

thighs and anus. These are secondary proliferations (Plate 50), having the same structure as the primary papule (dense alveolar infiltration of the cutis with cells rich in nuclei; chronic inflammatory thickening of the vessel-wall, with narrowing of the lumen).

Tertiary syphilides rarely occur; gummata are usually situated in the vagina and beside the cervix. They disintegrate rapidly, and strongly resemble the flat ulcerating vaginal epithelioma. (Plate 50.)

The differential diagnosis has been given to insure clinical recognition. The treatment properly belongs to the domain of syphilography.

## § 22. CATARRH OF THE BLADDER AND CYSTITIS.

**Anatomy.**—Vesical catarrh occurs in an acute and in a chronic form. The latter arises either from the former or from a chronic hyperemia, which produces ecchymosis in the mucous membrane or hemorrhages into the bladder.

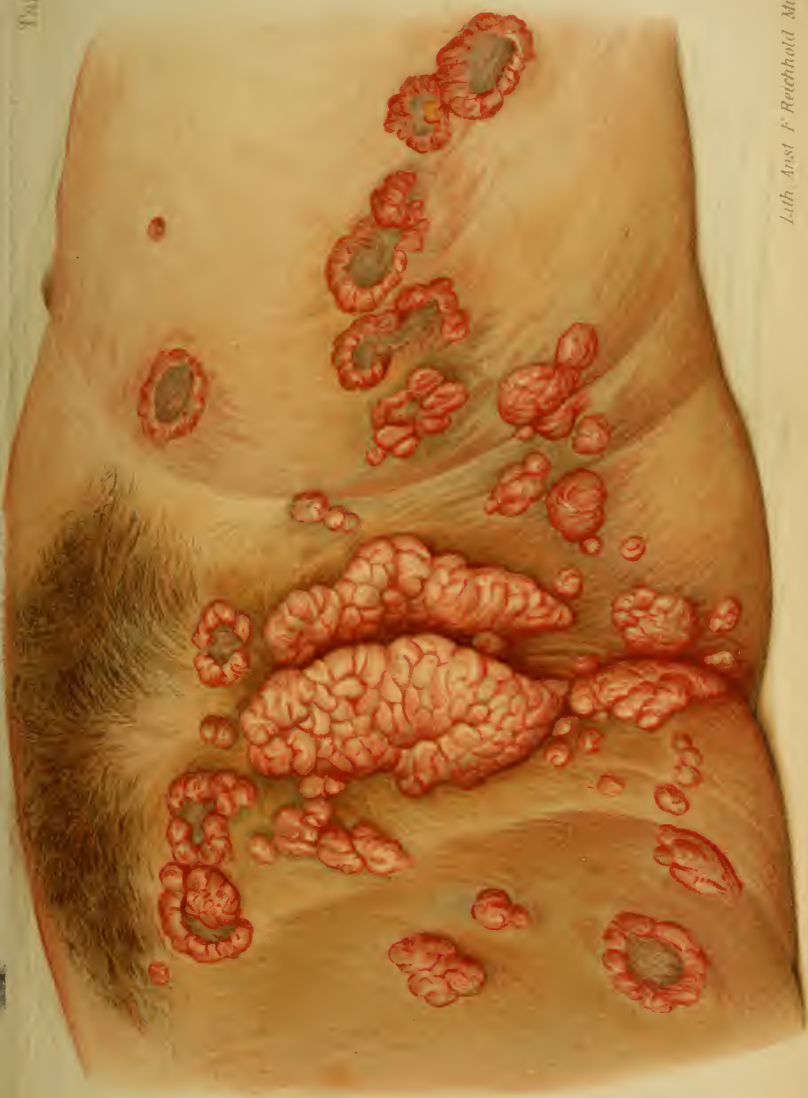In acute catarrh the organ is contracted; the mucosa is reddened, and shows areas that have lost their epithelium. Epithelial debris and emigrated red and white blood-corpuscles may be found between the folds of the wrinkled mucous membrane.


If the inflammation has become chronic, there is a reddening of the entire mucous membrane, or an insular hyperemia (often about the internal urethral orifice, associated with small ecchymoses). Great numbers of leukocytes pass out through the dilated vessels; the mucosa secretes quantities of mucus and casts off its superficial (squamous) epithelium.

If the catarrh decreases, the leukocytes continue to migrate for a long time; in other cases permanent excoriations are established, which are converted into ulcers (most frequently in the trigonum or at the urethral orifice) by the action of bacteria. The muscularis is finally affected.

The original infiltration of the muscularis leads either to an acute extension of the inflammation, to cystitis, and even pericystitis (*i. e.*, inflammation of the vesical subserosa and serosa), or to a chronic parenchymatous hypertrophy of the muscularis. The entire bladder-wall is thick and rigid. (Plate 48.)

The serosa reacts in a like manner and protects the peritoneal cavity from the urine; if it does not, the most acute peritonitis sets in and





death follows. Such pernicious extension is brought about by progressive gangrene. If the necrosis is limited to the mucous membrane, it leads to casting-off of the same *in toto* or in shreds—cystitis diphtheritica.

**Etiology.**—The manner of origin differs in many respects from that in the male. The shortness of the urethra allows the infective material to penetrate into the bladder more easily, and yet the same peculiarity prevents the urethritis from becoming chronic and going on to the formation of strictures. Concretions as large as a cherry may pass the urethra, and still larger ones may be removed through it by operative means. The female has no prostate, the hypertrophy of which leads to stasis and decomposition of the urine. The puerperal process gives rise to a series of injurious influences, partly direct pressure effects and partly inflammations. The latter are due either to direct extension from a parametritis or perimetritis, or to the perforation of an exudate or an extra-uterine gestation sac. An analogous predisposition is seen in perforating tumors of the female genitalia (carcinoma, see Plates 85, 86, 88, 89; dermoid cysts).

Retention of urine is another cause of catarrh of the bladder. It may be due to incarceration of a retroflexed gravid uterus, to an impacted retro-uterine tumor, or to an inversion of the vagina, with cystocele. The cause may be found in the bladder itself—tumors of the wall or vesical tuberculosis.

The two most frequent causes, however, are direct infection from a dirty catheter and gonorrheal urethritis.

Bacteria are concerned in all vesical catarrhs; they injure the bladder-wall and cause decomposition of the urine, which irritates the mucous membrane. The catarrh is maintained by irritating urinary ingredients, such as alcohol and cantharides.

**Symptoms and Diagnosis.**—Increased frequency of micturition, ardor urinæ, vesical tenesmus; the urine is sometimes bloody and always contains more or less mucus



(marked nubecula) or mucopus (thick, white sediment). It is cloudy and has a pungent ammoniacal odor. Slight fever is present.

The microscope shows red and white blood-corpuscles, desquamated epithelium, and, if alkaline fermentation exists, crystals of triple phosphate and acid urate of ammonium.

Diphtheric cystitis is recognized by the great vesical pain, the fever, and the shedding of membranes or shreds. The last-named symptom may render catheterization difficult. If these membranes produce marked ischuria, symptoms of urinary retention (beginning uremia) appear—dyspepsia, nausea, vomiting, alternating constipation and diarrhea, and cerebral congestion.

Hypertrophy of the bladder gradually leads to considerable vesical dilatation from the rigidity of the walls; even the *empty* bladder may be felt above the symphysis. After the muscular hypertrophy disappears the walls of the senile bladder may become almost as thin as paper—atrophy of the bladder. Both forms may be demonstrated by the catheter.

The presence of a cystitis being established, its cause must be diagnosed. The vesical causes are ulcers, tumors (see under Tumors), concretions, and foreign bodies. Vice versâ a whole series of troubles spring from inflammatory irritation, especially of the urethra. The same is true of ulcers (tubercular and others) and fissures at the neck of the bladder, especially those situated at the internal orifice of the urethra and in the urethra itself. These are extremely sensitive, and often arise from catheterization (even with the elastic catheter). These fissures and the catarrh and many of its causes lead to the—



### Sequels of Cystitis.

1. Vesical spasm.
2. Paralysis of the bladder—paralysis vesicæ (ischuria, incontinence, ischuria paradoxa, incontinence of retention).

1. **Vesical spasm** is a neuralgia, and occurs in nervous women, either as a result of vesical catarrh, pericystitis, and all irritations of the bladder (foreign bodies; concretions; hemorrhoids; ulcerations and fissures, especially at the vesical neck and in the urethra; tumors), or as a primary neuralgia from the influence of severe irritations upon an easily excited nervous system. It reminds one of vaginismus, and the two conditions may be associated. It is possible that irritations of the internal genitalia may act as causal factors. Such irritations are overindulgence in sexual intercourse, onanism, interrupted coitus, strong emotions, probably, and colds with subsequent chronic hyperemia. When such primary conditions exist, irritating foods and drinks may bring on an attack. Hysteria also plays its rôle.

**Symptoms and Diagnosis.**—Violent attacks of pain, lasting from a few minutes to several hours, which radiate from the neck of the bladder, and sometimes assume an extremely painful spasmodic character, especially at the beginning of urination. This spasm may be so violent that the urine can not be voided (ischuria spastica).

If a complicating vesical catarrh exists, the urine is cloudy, containing red and white blood-corpuscles, and mucus. In a pure neurosis it is as clear as water (urina spastica), but is frequently rich in urates and of such a peculiar offensive odor that some abnormal metabolic process (autointoxication) must be considered. The urine is sometimes passed in drops, sometimes in large amounts. The act excites radiating pain in all directions, as well as intestinal tenesmus, nausea, subsequent dyspepsia, ill humor, and sleeplessness, so that the general condition

finally suffers. The paroxysms frequently appear irregularly; the affection may persist for years.

**Diagnosis.**—All causes must be excluded. Bimanual exploration (palpation between the vagina and the symphysis) reveals the presence of calculi, tumors, and vesical hypertrophy. The sound, combined with the palpating vaginal finger, demonstrates sensitive areas (fissures) or small diverticula, the sacculations of which can not be emptied by the catheter, and thus continually reinfect the urine. The interior of the bladder may be digitally explored. Cystoscopy (with or without dilatation of the urethra by means of Simon's specula) allows of inspection of the parts, showing the presence of tumors, ulcers, circumscribed ecchymoses, small foreign bodies, and encysted calculi, and renders catheterization of the ureters possible. The latter procedure is of value in determining the source of pus that does not come from the bladder.

Cystoscopy, as it has been perfected by the instruments of Casper, Nitze, Pawlick-Kelly, and Rose, is the newest aid to diagnosis. In difficult cases it is indispensable. The various methods of its application must be practically learned. The pelvis of the patient is elevated, the urethra is somewhat dilated (previous injection of a few centimeters of a 5% solution of cocain), and a speculum with a beveled end is introduced. The bladder fills with air, and its walls, together with the urethral orifices, may be seen.

In another method of cystoscopy at least 50 c.c. of a boric acid solution are injected into the bladder, and a catheter (not exceeding  $\frac{1}{2}$  of a cm. in diameter), armed with a small incandescent lamp, is introduced. By moving the instrument about, the numerous recesses of the female bladder, the interureteric fold, and the trigonum are exposed to view. By means of the operative cystoscope minor operations, such as catheterization of the ureters, may be performed. This method is particularly applicable to determine definitely the source of pus in unilateral pyonephrosis.

It should be mentioned that it is also possible, in the female, to separate the urines from the ureters by means of a double catheter, the dividing partition of which extends to a position between the two ureteral orifices, and is pressed firmly against the bladder-wall.

The ureteral orifices are seen as fine linear fissures, either upon the apex or at the sides of small elevations of the mucosa.

Tubercular ulcers, developing tumors, threatened rupture of a parametritic or pericystic abscess, and encysted foreign bodies (vesical calculi) may be surely diagnosed, and to a certain extent treated, by means of the cystoscope.

**2. Paralysis of the bladder** may be of a twofold character: paralysis of the longitudinal and oblique muscular fibers—ischuria, retention of urine; or paralysis of the circular fibers (sphincter vesicæ)—incontinentia paralytica. Both forms may be combined: *i. e.*, the urine dribbles and can not be retained (incontinence) after the desire to urinate has already been lost (ischuria).

If paralysis of the sphincter is not present, in addition to the retention the bladder becomes immoderately distended (without strangury), gradually overcoming the resistance of the sphincter and emptying its urine drop by drop. The bladder suffers no decrease in size, however, and the patient has no suspicion of its dilated condition (ischuria paradoxa, incontinence of retention).

All these conditions (ischuria and incontinence) may follow the puerperal process, from displacements of the bladder, angulation of the urethra, swellings in the urethral region after delivery, or from inflammation of any portion of the genital tract or its serous covering. They may be due to changes in the elasticity of the muscularis (fatty degeneration, atrophy) from cystitis, habitual overdistention of the bladder, advanced age, and acute infectious diseases. They are caused by decreased innervation, as seen in diseases of the spinal cord and other central disturbances, such as apoplexy, neurasthenia, and hysteria (after easy

finally suffers. The paroxysms frequently appear irregularly; the affection may persist for years.

**Diagnosis.**—All causes must be excluded. Bimanual exploration (palpation between the vagina and the symphysis) reveals the presence of calculi, tumors, and vesical hypertrophy. The sound, combined with the palpating vaginal finger, demonstrates sensitive areas (fissures) or small diverticula, the sacculations of which can not be emptied by the catheter, and thus continually reinfect the urine. The interior of the bladder may be digitally explored. Cystoscopy (with or without dilatation of the urethra by means of Simon's specula) allows of inspection of the parts, showing the presence of tumors, ulcers, circumscribed ecchymoses, small foreign bodies, and encysted calculi, and renders catheterization of the ureters possible. The latter procedure is of value in determining the source of pus that does not come from the bladder.

Cystoscopy, as it has been perfected by the instruments of Casper, Nitze, Pawlick-Kelly, and Rose, is the newest aid to diagnosis. In difficult cases it is indispensable. The various methods of its application must be practically learned. The pelvis of the patient is elevated, the urethra is somewhat dilated (previous injection of a few centimeters of a 5% solution of cocain), and a speculum with a beveled end is introduced. The bladder fills with air, and its walls, together with the urethral orifices, may be seen.

In another method of cystoscopy at least 50 c.c. of a boric acid solution are injected into the bladder, and a catheter (not exceeding  $\frac{1}{2}$  of a cm. in diameter), armed with a small incandescent lamp, is introduced. By moving the instrument about, the numerous recesses of the female bladder, the interureteric fold, and the trigonum are exposed to view. By means of the operative cystoscope minor operations, such as catheterization of the ureters, may be performed. This method is particularly applicable to determine definitely the source of pus in unilateral pyonephrosis.



It should be mentioned that it is also possible, in the female, to separate the urines from the ureters by means of a double catheter, the dividing partition of which extends to a position between the two ureteral orifices, and is pressed firmly against the bladder-wall.

The ureteral orifices are seen as fine linear fissures, either upon the apex or at the sides of small elevations of the mucosa.

Tubercular ulcers, developing tumors, threatened rupture of a parametritic or pericystic abscess, and encysted foreign bodies (vesical calculi) may be surely diagnosed, and to a certain extent treated, by means of the cystoscope.

**2. Paralysis of the bladder** may be of a twofold character: paralysis of the longitudinal and oblique muscular fibers—ischuria, retention of urine; or paralysis of the circular fibers (sphincter vesicæ)—incontinentia paralytica. Both forms may be combined: *i. e.*, the urine dribbles and can not be retained (incontinence) after the desire to urinate has already been lost (ischuria).

If paralysis of the sphincter is not present, in addition to the retention the bladder becomes immoderately distended (without strangury), gradually overcoming the resistance of the sphincter and emptying its urine drop by drop. The bladder suffers no decrease in size, however, and the patient has no suspicion of its dilated condition (ischuria paradoxa, incontinence of retention).

All these conditions (ischuria and incontinence) may follow the puerperal process, from displacements of the bladder, angulation of the urethra, swellings in the urethral region after delivery, or from inflammation of any portion of the genital tract or its serous covering. They may be due to changes in the elasticity of the muscularis (fatty degeneration, atrophy) from cystitis, habitual overdistention of the bladder, advanced age, and acute infectious diseases. They are caused by decreased innervation, as seen in diseases of the spinal cord and other central disturbances, such as apoplexy, neurasthenia, and hysteria (after easy

labors, simple operations that do not even involve the vesical region or anterior vaginal wall, emotion, ingestion of irritating foods, new wine and beer, asparagus, strong tea, etc.). Finally, they are seen in weak individuals, in the form of enuresis nocturna, and associated with intoxications.

**Symptoms and Diagnosis.**—Ischuria paralytica manifests itself by the difficulty of urination, excessive demands being made upon the abdominal muscles to aid in the expulsion of the urine. The cause must, nevertheless, be accurately determined, and the possible existence of urethral tumors especially should be considered. When dribbling is present, the catheter is to be employed in order to exclude ischuria paradoxa and foreign bodies.

#### **Treatment of Cystitis.**

Recent gonorrheal urethritis and cystitis are treated as indicated in §12.

In simple acute vesical catarrh (without fever) the bladder is not to be disturbed; the urine is to be rendered mild and unirritating; above all, an abundance of tea and milk (add 25.0 of lime-water to  $\frac{1}{2}$  of a liter of milk if it is not well borne). Abstinence from all irritating foods, especially alcohol. The diet should be bland, including egg-albumen, milk of almonds, bouillon, and rare meat. The bowels should be regulated by injections and mild laxatives.

Instead of prescribing balsams, as was formerly the custom, urotropin (0.5, three times daily), potassium chlorate, or a solution of sodium salicylate (5 : 150) are given.

The tenesmus is best controlled by rest in bed, warm fomentations, narcotics in vaginal or rectal suppositories (chloral, tincture of opium, morphin, extract of belladonna), or chloral or opium by the mouth. The vesical mucous membrane itself absorbs nothing. Warm baths.

In chronic cystitis due to infection irrigation of the bladder is to be added to the foregoing measures : physio-



logic NaCl solution, 1–2 % boric acid,  $\frac{1}{3}$  % salicylic acid, 0.5–1 : 1000 nitrate of silver. To alleviate the irritation of the stronger solution, subsequent irrigations of 0.25 % cocain are employed. After solutions of nitrate of silver stronger than 6 : 1000, NaCl solution to precipitate the silver. If the mucous membrane is very sensitive, NaCl or mucilaginous solutions (starch, oatmeal).

The irrigations are carried out with a catheter, or with Küstner's funnel (which I prefer to use, because of the easy formation of a fissure by the catheter) to which a tube and a glass funnel (Hegar's) are attached. The latter should hold from  $\frac{1}{4}$  to  $\frac{1}{2}$  of a liter. The apparatus must be rigidly aseptic, and no air-bubbles are to enter the bladder. The funnel is to be filled several times in succession. The temperature should be from 95° to 100° F. The pressure should not be too great, especially with a paralyzed detrusor urinæ. The irrigations are made from one to four times daily ; if high fever is present, every two hours.

The quickest results are obtained by permanent drainage of the bladder, which is always to be employed if fissures and severe cystitis are present. As recommended by Fritsch, a rubber tube, 15 cm. long and 0.6 or 0.7 cm. in diameter, is introduced and is held in position by adhesive plaster (or Unna's zinc plaster) or by a suture through the nymphæ. The tube should only be introduced far enough to allow the urine to flow out. The instrument must be changed every three days on account of the incrustation.

Diphtheric membranes must be removed ; their presence may be diagnosed from the numerous small incrustated shreds and from the bloody, decomposing urine. The urethra must be dilated by means of Simon's specula. The first three numbers are to be successively introduced, and the irrigation is to be carried out with No. 3. If hemorrhage occurs : Ferripyrin solution (1 : 5), solution of sesquichlorid of iron (1 : 800), or iodoform-ferripyrin-

gauze tamponade through the speculum. The after-treatment consists of a bland diet and carbonated waters (such as Wildunger, Vichy) or mild infusions.

Hypertrophy and contraction of the bladder are treated by regular catheterization and lukewarm irrigations, the amount being increased daily (to distend the bladder), cold baths, douches, and vaginal irrigations.

For spasm of the bladder: Removal of the cause (foreign bodies, etc.), bearing in mind fissures at the neck of the bladder or in the urethra; if these are present, Fritsch's permanent catheter or dilatation of the urethra. Avoid all congestions: injections and mild cathartics; forbid sexual intercourse; hot foot-baths; bland diet without alcohol. For the nervous excitability: Potassium bromid, mild hydrotherapy. During the attack: Chloral internally, by the vagina or rectum; injections of morphin directly into the bladder, or irrigation with a cocain solution; or the measures employed for tenesmus.

In paralysis of the bladder the exercise of the will plays an important rôle as far as the sphincter is concerned—enuresis nocturna, for example (wake the patient several times during the night and have her empty her bladder); hydrotherapy; roborants.

Ischuria (detrusor paralysis) is treated by frequent catheterization, cool applications, and abdominal massage.

If the muscularis is already paretic or paralytic (incontinentia paradoxa paralytica), electricity is to be employed. It is also of value in uncontrollable enuresis nocturna. One well-insulated pole is introduced into the bladder, which has been filled with water, and the other pole is applied to the symphysis, lumbar region, or perineum. Ergot is also employed. The treatment of the catarrh—catheterization and lukewarm irrigations—is usually of value in alleviating this condition.

## CHAPTER II.

### **DISTURBANCES OF NUTRITION AND CIRCULATION.** (**Exanthemata, Phlebectasia, Neuroses.**)

Since the female genitalia, and particularly the vulva, are unusually rich in nerves, glands, blood-vessels, and lymphatics in the shape of cavernous tissue, the affections of one set of structures easily spread to the others, and cause the most varied changes, which usually give rise to a typical symptom-complex : pruritus vulvæ, vaginismus, dysmenorrhea, hysteria.

#### **§ 23. DISTURBANCES OF NUTRITION AND CIRCULATION.** (a) **Of the External Genitalia.**

By vulvitis pruriginosa we understand an inflammation of the external genitalia, associated with intense itching (pruritus). The parts are dry, fissured, and slate-gray in color.

There are different varieties of vulvitis : simple reddening—dermatitis simplex ; if the corium and subcutaneous tissue are diffusely involved—phlegmone vulvæ with abscess formation ; if partial—furunculosis ; if the sebaceous glands are inflamed (small yellowish projections like acne)—folliculitis ; if an inflammation of the connective-tissue papillæ (small red prominences) also exists—papillary vulvitis. There is a vulvitis diabetica. Bartholinitis has been mentioned in §12.

Cutaneous exanthemata (eczema, herpes, prurigo, miliaria) rarely occur.

**Treatment.**—*Simple inflammation* : Washings with warm soda solutions and the subsequent application of lead-water, solution of

aluminum acetate, zinc ointment, 20% boric-vaselin, 10% carbolized oil, sitz-baths, dusting-powders (bismuth-talcum).

*Severer inflammation*: Soda solutions, then apply 5-10% solution of silver nitrate, and lead-water compresses.

*Abscesses*: Incision. In furunculosis: Shave off the pubic hair; Unna's mercurial plaster in the beginning; later, warm sitz-baths, soap plaster, emollient cataplasms.

*Diabetic vulvitis*: Constitutional treatment, meat diet, laxatives (sal carolinum).

*Folliculitis*: Remove the grease from the skin by means of solutions of potassium carbonate (a piece the size of a walnut is dissolved in the wash-water) and immediate application of 5-10% solution of nitrate of silver. If pruritus is present, excision of the part, 5% menthol-alcohol, or menthol-lanolin.

*Pruritus*: Washings with soda solution; application of 10% solution of nitrate of silver and subsequent 10% carbolic acid compresses; applications of ice-water, compresses of 6% menthol-alcohol, or  $\frac{1}{3}$ -1:1000 corrosive sublimate, or salicylic acid; warm sitz-baths with  $\frac{3}{4}$  of a pound of wheat bran, oak-bark decoctions, or other astringents (alum, formalin, tannin). Anodynes: cocain (expensive!), eucain B, chloroform, morphin, and belladonna act temporarily in cases having a neurasthenic basis and not rarely appearing after some acute exciting cause (fright).

### (b) Of the Internal Genitalia.

By vaginismus we understand a reflex spasmodic contraction of the introitus vaginæ from contact with the marked hyperesthetic, usually thickened and chronically inflamed, hymen, or carunculæ myrtiformes. It is a symptom-complex similar to pruritus, but it also affects the motor elements. The two affections may coexist. Central or hysteric processes are also responsible, as is demonstrated by the fact that the lightest touch with a smooth instrument-handle produces the same result as the impetus cœundi or the introduction of a speculum.

I had a patient in whom the introduction of an irrigation tube was easy and painless when carried out by herself, but accompanied by intense pain when done by any one else. If her attention was engaged, a tampon could be introduced. The thought of a remarriage, with subsequent coitus, also brought on an attack.

There is one form of vaginismus, however, without pain, as is shown by the symptom of the "penis captivus." There are also neuroses of the vagina situated higher up—



painful areas, especially in the posterior vaginal vault and not associated with parametritic processes.

**Treatment.**—Careful excision of the entire hymen, including the urethral orifice with its caruncles. In the case mentioned the nymphæ (folliculitis) were also removed, on account of pruritus. The patient married, conceived, had an easy delivery, and has now been a mother and wife for four years; in her first marriage, lasting for some years, she was an unhappy, and finally a divorced, woman.

If the hypersensitiveness still remains, the sphincter vaginae should be forcibly stretched. The actual anesthesia of the parts is now demonstrated to the patient by palpation. Regular coitus and the speedy occurrence of impregnation remove the last vestiges of the trouble.

In other cases conditions of pronounced nervous irritation, and finally nervous depression, or even psychoses, occur.

Masturbation is a frequent cause. In such cases the time of the patient should be completely occupied by absorbing and fatiguing duties, and all irritations of the senses should be removed (lectures, balls, theater, etc.). Other causes are fissures, arising from a resistant hymen, and impotentia coeundi on the part of the male. (See § 5.)

A disturbance of nutrition of the aged, colpitis vetularum (Ruge), leads, as colpitis ulcerosa adhesiva (irregular areas of round-cell infiltration with desquamated epithelium), to adhesions, scars, and bridges of new tissue.

Examples of vasomotor anomalies of innervation are furnished by phlebectasia of the vulva (Plate 51) and varicocele parovarialis (Plate 53); the latter may give rise to intraperitoneal hematocele or hematoma of the broad ligament.

The disturbances of innervation of the arterial system are usually associated with similar affections of all the contractile elements of the genitalia and their supporting ligaments. This deficient "tonus" is a frequent occur-

## PLATE 51.

**FIG. 1.—Elephantiasis Vulvæ Originating in the Labium Majus Dextrum and Polypoid Excrescences of the Mucous Membrane at the Urethral Orifice.** The elephantiasis starts in the deeper connective tissue and consists of proliferated lymph-capillaries (see Plate 29, Fig. 1), partly neuromatous (Czerny) and partly from stasis. The tumors may resemble external papillomata, but their excrescences are usually larger and flatter. (See Plate 24.) Sometimes the tumors grow out from the entire vulva. Their growth is always slow and is characterized by great variations in size.

Polyps of the urethral mucous membrane are seen at the external orifice or at the neck of the bladder. They consist of connective tissue, and rarely contain small retention cysts, arising from atresia of the excretory ducts of Skene's glands (in Fig. 20 the fine orifices of these glands are seen in the urethral wall). Other urethral tumors arise as varices, as vascular proliferations (angioma), as sarcoma and epithelioma. (Original water-color; case in Munich Frauenklinik.)

**FIG. 2.—Phlebectasia of the Labia Majora, of the Clitoris, and of the Nymphæ; the Right Labium Majus Contains a Hematoma (Thrombus Vulvæ); and Hemorrhoids.** This condition is most frequently found in parturient or puerperal women, the varices being due to venous stasis; the extravasation, to subcutaneous injuries of the vessels during delivery. Hematoma may also occur in nonpregnant women as a result of trauma.

---

rence, and leads to descent and prolapse of the uterus, of the vaginal walls with the bladder and the rectum, and to retroversion and retroflexion of the uterus. It produces a chronic hyperemia of these organs, which becomes the noninfectious starting-point of an inflammation.

These affections have been considered in §§ 7–11 and in §§ 13, 14, and 17. The foregoing common etiologic factor must be borne in mind, as it is of far-reaching importance.

The partly uterine, partly ovarian symptom-complex of dysmenorrhea is described in § 4, under 8.

The hysteric symptom-complex (see § 11, under Symptoms, and § 17, under Diagnosis) represents a disease of the entire nervous sys-



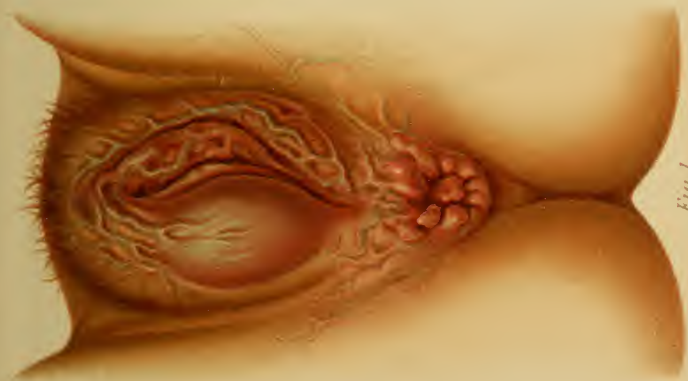


Fig. 1.

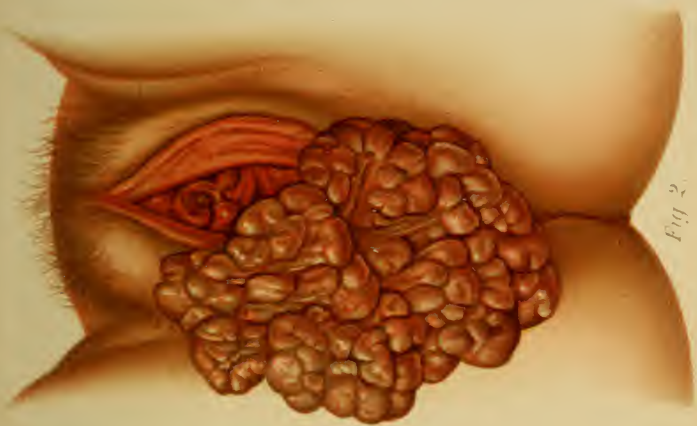

Fig. 2.



tem, with a cerebral origin, and the evolution of certain phenomena, A predisposition either may preexist or may be induced by a too indulgent education. This disease arises from marked sensual or emotional excitement, which individuals with healthy nerves bear without injury, or from a permanent feeling of self-dissatisfaction.

In addition to congenital traits, a general predisposition is furnished by our city life, with its early manifold sensory impressions, its disproportionate mental activity, its luxuries and pleasures, and with its absence of actual invigorating labor, and of precise duties and corresponding strengthening of the will. These pernicious factors must be excluded in youth; amends must be made for them in later years.

Diseases of the genitalia may bring on the disease, but they do not always produce hysteria, nor are they the only exciting causes. As such may be mentioned puerperal diseases, with their infectious irritations and weakening hemorrhages; chronic painful oophoritis and salpingitis; pelveoperitonitic adhesions; retroflexio uteri fixati; spasmodic angulation of a retroverted uterus; inflammations of the uterus; intramural myomata projecting from the os uteri; traction from polyps, etc.

**Symptoms.**—Ill humor, hypersensitiveness, weakness of will.

Epileptiform spasms and contractions, usually clonic, sometimes tonic, with perfect consciousness and reflex excitability (pupils); of the muscles of the extremities and trunk (Charcot's arch), with accelerated respiration, and, according to the state of mind, paroxysms of shrieking, crying, laughing; of the laryngeal and esophageal muscular, spasm of the glottis (barking cough), spasm of the esophagus (globus hystericus). Singultus hystericus.

Paralyses: of the extremities, unilateral and bilateral; of the vocal cords, hysteric hoarseness and aphonia (as in a case with retroflexion of the uterus at the Heidelberg clinic).

General and partial hyperesthesias and anesthasias: Tussis uterina, emesis et vomitus, clavus hystericus, spinal irritation, "ovaric" (Charcot).

Vasomotor and trophic symptoms: Palpitation, stenocardia, nervous dyspepsia, meteorismus; anomalies of secretion of the skin (hyperidrosis, anhidrosis), of the kidneys (polyuria, oliguria or temporary anuria, ischuria); nervous diarrhæa, etc.

**Diagnosis** is made from the rapidly changing character of the symptoms. These do not form a clinical picture corresponding to pathologic changes in any definite organ.

**Treatment.**—*Prophylactic* (see Treatment of Vaginismus).—Psychic influence and education; above all, never criticize the patient's view of her ailment, but demonstrate to her its general nervous character, and change the manner of living, the diet, etc. Regulate the functions as indicated in § 4, under 7. Restricted and bland diet or a more liberal one, as the case may be. Treatment of a genital disease, if present.

Lukewarm baths to render the patient more hardy; gradually lower the temperature from 88° to 72° F., fifteen minutes. Electric baths.

*Symptomatic.*—Potassium bromid (with heart disease, sodium

## PLATE 52.

**Edema of the Nymphæ from a Moribund Patient with a Cardiac Lesion.** (Original water-color from nature.)

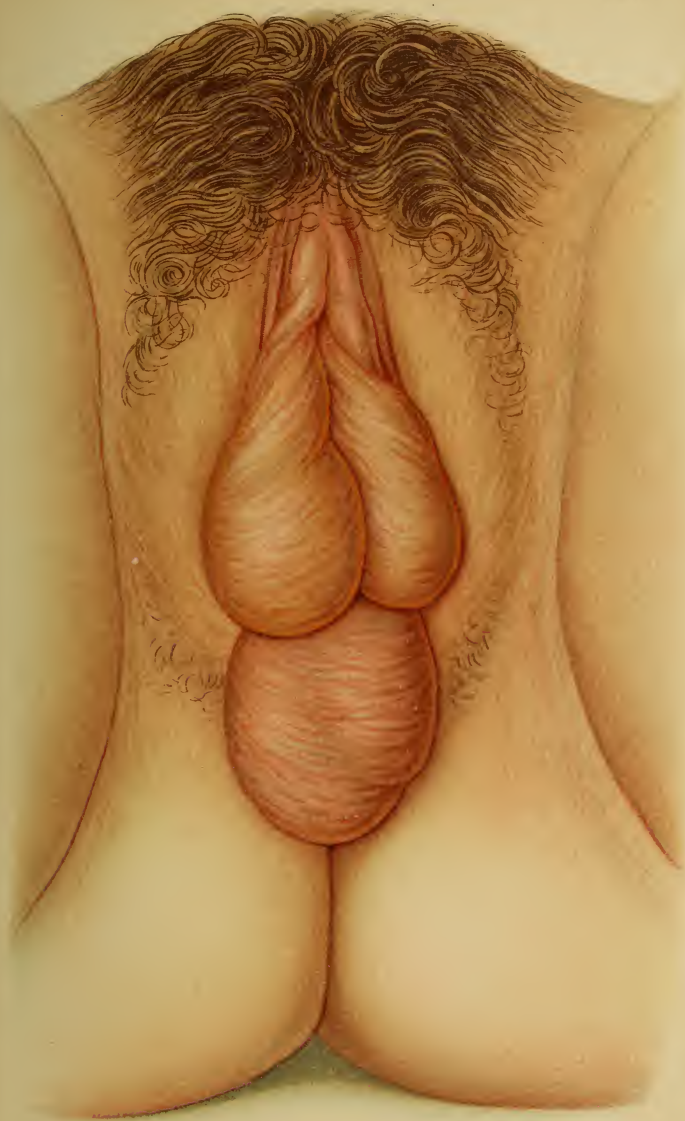
bromid) and monobromated camphor for the excitement, irritation, and palpitation; phenacetin, lactophenin, heroin, sulphonal, trional, menthol, valerian. Chloroform, morphin, atropin, chloral, and extract of belladonna (by the mouth, by the rectum, or hypodermically) are all used for the neuralgias and as sedatives or hypnotics. They usually do more harm than good. For the paralyses, faradization or massage; for the spasms and convulsions, cold water in every form known to hydrotherapy.

Charcot's so-called "Ovarie" has been mentioned in § 17, under Diagnosis. In the great majority of cases it has nothing to do with the ovaries or even with the adjacent nerve plexuses. It is generally either a neuralgia of the nerves passing through the abdominal recti muscles toward the hypogastrium, or neuralgia of the posterior vaginal vault, of the pouch of Douglas, and of the contiguous portion of the rectum. The latter cases are usually associated with vasomotor and motor disturbances of innervation of the parts. (See the author's paper in the "*Mon. f. Geb.*," January, 1898.)

Coccygodynia is a local hyperesthesia of the plexus coccygeus.

**Treatment.**—Hydrotherapy, or, in extreme cases, extirpation of the os coccygeus.

Sometimes confusion may arise from a pain, which is experienced in the coccygeo-anal region, but the location of which may be shown to be considerably higher—in the posterior vaginal fornix or about the pouch of Douglas; not rarely varicoceles in the broad ligament and hemorrhoids high up in the rectum may be demonstrated. In the puerperium, immediately after delivery, and sometimes even occasionally during pregnancy, an analogous pain is experienced, which is falsely ascribed to the coccyx, to pressure on its plexus, to periosteitis, to luxations, etc. Careful palpation from the rectum and externally excludes these conditions.







## GROUP IV.

### INJURIES AND THEIR CONSEQUENCES.

---

#### CHAPTER I.

##### DEFECTS WITH CICATRICIAL CHANGES.

All varieties of genital lesions arise by far most frequently during delivery. The effect they produce is dependent upon their location. Cicatrices in the vulva rarely cause atresia; on the contrary, they produce a gaping. Lacerations of the external os may heal with ectropion; nevertheless, here, as in the vagina and cervix, stenosis and atresias are more likely to occur.

#### § 24. INJURIES OF THE VULVA (INCLUDING FISSURES) AND PERINEAL DEFECTS, INCONTINENTIA VULVÆ.

**Definition.**—The solutions of continuity, which are now to be considered, have the character of incised, of lacerated, and of lacerated and contused wounds. A natural division, based upon the depth of the injury, is as follows:

1. Fissures: Slight linear solutions of continuity of the surface, occurring at the frænulum perinæi and productive of specific results when involving the hymen, the neck of the bladder, or the urethra. (See §§ 22 and 23.)

2. Lacerations of the perineum of the first degree: Tears of the frænulum perinæi and of the mucous membrane of the vestibule.

## PLATE 53.

**Phlebectasia with Phleboliths of the Ligmenta Lata Corresponding to the Ovarian Vessels and the Pampiniform Plexus.** The venous stasis in the remaining portions of the broad ligaments is also apparent. (Original water-color from an autopsy at the Heidelberg Path. Inst.)

---

3. Tears of the mucosa of the fossa navicularis, the skin surface of the perineum being intact, but undermined. This important and easily overlooked variety is not rarely produced by the posterior shoulder.

4. Lacerations of the perineum of the second degree: Tears extending to the sphincter ani.

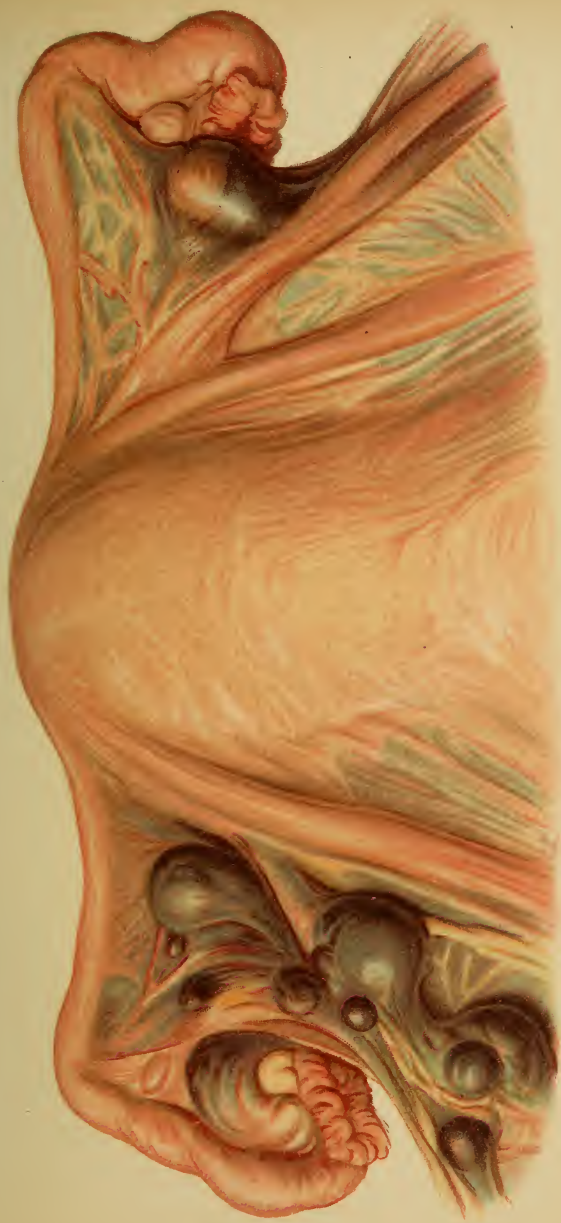5. Perforations of the perineum (rare): Canal-like lacerations, which pass from the vagina through the middle of the perineum, sometimes involving the anus, the anterior portion of the frænulum perinæi being left intact.


6. Lacerations of the perineum of the third degree, or complete lacerations: the tear extends into the rectum.

While all these tears are brought about, almost without exception, by incidents of the sexual life (cohabitation, delivery, and the puerperium—urethral fissures from catheterization), the parts of the vulva are also exposed to other traumatisms. These are followed by serious results, especially if occurring during pregnancy, when the parts are very vascular. The region of the clitoris is the most exposed to wounds, which are usually caused by falling astride of some object. It is also the most dangerous region, as patients have bled to death in a short time from hemorrhage from the corpus cavernosum.

Hemorrhages and injuries of this character must be treated immediately by suture.

Lacerations and perforations of the nymphæ are not productive of further consequences.





**Symptoms and Consequences of Perineal Lacerations.**—If primary union is not obtained by immediate suture after delivery, these wounds heal by granulation, the lower portions of the labia being drawn apart and distorted.

Fissures cause only a burning, and may induce infectious ulceration; they may nevertheless be produced in a perineal cicatrix as rhagades (after coitus, difficult defecation).

In perineal lacerations of the first degree (Plate 54, Fig. 3) the tuberculum vaginæ loses the covering and support of the frænulum perinæi. This portion of the anterior vaginal wall prolapses; the urethral orifice gapes;<sup>1</sup> there is a predisposition to urethritis and vesical catarrh.

In perineal lacerations of the second degree the posterior vaginal wall prolapses from above the scar (see Plate 27); and if the entire pelvic suspensory apparatus, including the pelvic fascia and the levatores ani muscles, has lost its "tonus," all those downward displacements described in §§ 7 and 8 and their appurtenant plates may occur. In addition, uterine and vaginal catarrh, cystocele, and rectocele, and their sequels, are produced.

In perineal lacerations of the third degree—the complete variety (Plates 7, 1; 54, 2 and 4; Fig. 26)—fecal incontinence is present, because the voluntary external sphincter muscle is torn. In extreme cases the internal sphincter is also involved.

As is shown in the sagittal section of the perineum (Plate 54, Fig. 1), the transversely striated external sphincter forms a rounded body about the anal pouch (see the corresponding outline of the shading), while the internal sphincter passes vertically upward from it as an elongated mass of fibers. Both sphincters are absent in figures 2 and 4; in figure 3 they are both present. The whole perineum may be destroyed, and yet a portion of the external sphincter may remain intact.

<sup>1</sup> In Heidelberg I saw such a case in a peasant's wife. The impetus cœundi had been directed against the prolapsed tuberculum vaginæ and, in this manner, had so dilated the urethra that the finger could be readily introduced. (Plate 19, 2.)



## PLATE 54.

FIG. 1.—The normal perineum is a physiologic support for the vaginal walls, and indirectly for the uterus. The intact perineum forms the lowest part of the vulva, being at a lower level than the end of the anterior vaginal wall. It resembles a triangle placed beneath the vaginal ostium and supporting the tuberculum vaginæ. It also supports the entire posterior vaginal wall, which, in its turn, holds up the upper half of the anterior one. The normal cervix looks backward, resting against the posterior vaginal fornix, and the corpus uteri derives its support from the anterior vaginal wall.

FIG. 2.—**Perineal Laceration of the Third Degree (into the Rectum).** Inversion of the anterior vaginal wall with beginning cystocele ; descensus uteri from flattening of the anterior vaginal vault.

FIG. 3.—**Perineal Laceration of the Second Degree.** The loss of support of the anterior vaginal wall is clearly shown.

FIG. 4.—**Perineal Laceration of the Third Degree.** Inversion and prolapse of the posterior vaginal wall ; beginning retroversion of the uterus.

---

There are cases, however, in which solid, and even liquid, stools can be voluntarily controlled. This is due either to an intact portion of the external sphincter, the tear not extending  $1\frac{1}{2}$  cm. into the rectum, or to the fact that the lowest portion of the rectum has undergone cicatricial contraction. Such cases are not easy to diagnose, because these rectal scars become pigmented and covered with epidermoid tissue.

The scars may be the seat of neuralgias or pruritus. If fissures form, burning and tenesmus are present. The continual moisture of the prolapsed vaginal walls, with or without discharge or intertrigo, is a constant source of annoyance ; there arises a dragging sensation, as if the internal organs would fall out. The deficient closure of the vulva, which increases with the senile atrophy of fatty tissues, allows air to enter the vagina ; any increase of the abdominal tension will force this air out in an audible manner—*garrulitas vulvæ*.



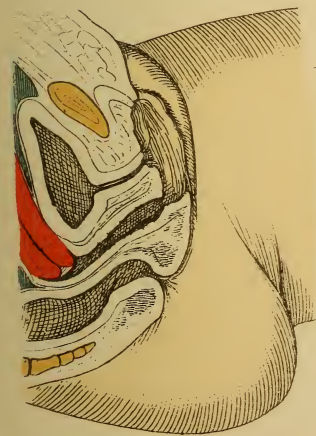


Fig 1.

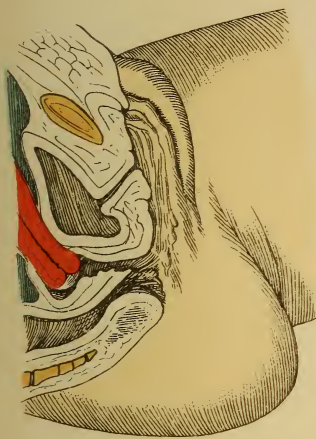

Fig. 2.

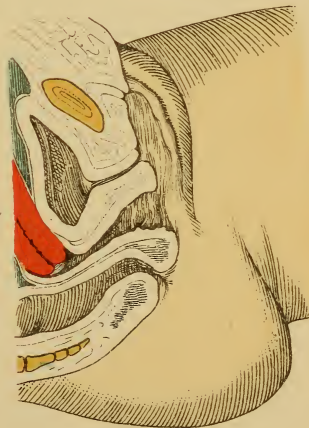

Fig.3.

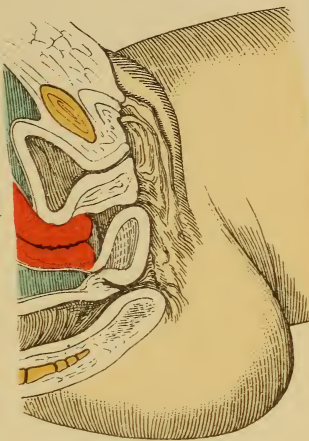


Fig. 4.



**Treatment.**—These serious symptoms are best treated by plastic operations, as mentioned in § 8. The success of the operation depends partly upon the preparation of the patient: disinfection of the vagina and cervix by sponging and irrigation, emptying of the bladder, and especially of the rectum (two or three days before the operation). Narcosis. Cotton tampon in the rectum.

The operation may be performed soon after the completion of the puerperium. Not only must the cutaneous bridge between the lower ends of the labia be restored, but the new septum, with its anterior edge (corresponding to the frenulum), must also cover the tuberculum vaginæ and support the anterior vaginal wall.

This new perineal septum must, further, have the same size and shape (triangular in sagittal section) as the normal perineal body, so that a new fossa navicularis will be formed.

The outline of the denudation will vary according to the nature of the defect; if the vagina is injured and deeper, it is hat-shaped (Hildebrandt and Freund); if the chief lacerations are in the lateral portions of the vagina, it is shaped like the wings of a butterfly (Simon and Hegar). In the latter case the area is denuded in that manner so as to form a perineal body resembling the original one. Fritsch pursues the same course, excising the scars in the vagina, with their lateral extensions, and inserting stitches toward the vagina, toward the perineum, and toward the rectum.

Hildebrandt, Freund, and Martin cut one or two or more triangular flaps from the vagina: *i. e.*, either avoid or remove the columnæ rugarum posterior.

Bischoff, v. Winckel, and Küstner (episioplasty) procure a median vaginal flap or two lateral vulvar flaps of corresponding shape to the outline of the scar, the principal portions of which are rarely in the middle line. This is known as flap-perineorrhaphy.

Simpson, Lawson Tait, Sänger, Zweifel, and v. Winckel perform perineoplasty in as conservative a manner as pos-

sible : *i. e.*, without the removal of tissue. This method has been improperly defined as flap-perineorrhaphy. A transverse incision is made in the rectovaginal septum, and its edges are drawn upward and downward by means of tenacula. The original transverse wound is now closed by a vertical row of sutures (deep and superficial), drawing the tissues together in the median line. [In America the importance of repairing ruptures of the pelvic fascia and of the levatores ani muscles is so thoroughly appreciated that Emmet's plan of operating for so-called perineal lacerations has largely superseded all others.—ED.]

The complete perineal lacerations (third degree) are operated upon according to the same principles ; here the edges of the rectal tear must also be freshened and must be united by sutures.

**After-treatment.**—It is best to leave the wound uncovered ; it should be frequently irrigated, and the most rigid cleanliness should be maintained. The knees are to be bandaged together. The sutures are allowed to remain as long as possible (from ten to twenty days) ; the best materials are silver wire and silkworm-gut.

On the third day, or soon thereafter, the bowels should be moved by castor oil in capsules ; high injections may be used, if necessary. In most cases opium is unnecessary for the production of an artificial coprostasis if the intestinal tract has been previously thoroughly evacuated and the patient is kept upon a nutritious liquid diet. If individual sutures cut through, they are to be removed. Should a rectovaginal fistula occur, the entire septum is to be divided, all granulation tissue removed, and the wound surfaces united as before.

The patient is to be kept in bed for two or three weeks.

## § 25. LACERATIONS OF THE VAGINA AND CERVIX.

(a) **Simple injuries of the vagina** (*i. e.*, without opening neighboring organs) occur most frequently during delivery. They are also the result of accidental trauma or of unskilled or rough manipulations,

such as forced coitus, especially in elderly women or where the disproportion between the size of the genitals is great; rape; clumsy operative procedures or examinations; the introduction of specula that are too large; attempts at abortion; and cauterizations.

**Symptoms.**—Often union per primam; sometimes severe hemorrhages or septic infection. The author observed, two hours after a tear of the fornix with most profuse hemorrhage (illegitimate coitus of an English woman forty-nine years of age, who had had a child twelve years before, and who suffered from vaginismus), a temperature of 101.3° F., a pulse of 120, and an acute urticaria covering the entire body, which lasted twelve hours.

**Treatment.**—Disinfection, removal of necrotic shreds, ligation or suture of vessels, coaptation of fresh wounds, tamponade with ferri-pyrin, alum-iron chlorid, iodoform, nosophen, or itrol gauze. Old vaginal scars producing stenosis or atresia are to be excised, stretched (manually or by tamponade), or treated by plastic operations. This will make the treatment tedious, and if conception has already occurred, complicated methods of delivery may be necessary.

(b) **Tears of the cervix** lead to commissural or to star-shaped defects (Plate 55), to scars of the os uteri, and, secondarily, to ectropion. (§ 13 and Plate 56.) If they extend into the vaginal vault and the paracervical connective tissue, they produce torsions and fixed displacements of the neck of the uterus. (See § 11 and Plate 55.)

These lacerations, instead of undergoing simple cicatrization, many persist for a considerable time as yellowish-gray, fissured ulcers with reddened edges. Both processes occur most frequently at the commissures of the os uteri, because these portions of the tissues heal poorly. The ulcers are immediately followed (even in the puerperium, see § 15) by endometritis, metritis and parametritis, and secondary ectropion; the scars cause direct ectropion and a secondary uterine catarrh.

The distortions produced by the scar tissue cause radiating pains in the lower extremities and nervous reflexes similar to the epileptic and epileptiform attacks associated with scars elsewhere.

**Treatment.**—Emmet first directed attention to these fissured ulcers and their consequences, and recommended their treatment by the following procedure: The lips of the ectropion are fixed with tenacula, the commissural scar



## PLATE 55.

**FIG. 1.—Torsion of the Cervix Produced by Scar Tissue.** It extends posteriorly from the commissure of the os uteri into the base of the left broad ligament.

**FIG. 2.—Star-shaped laceration of the external os,** resulting from difficult labor with a rigid cervix, or from an operative delivery before the external os is sufficiently dilated. Tears occur in the lips of the os uteri just as frequently as in their lateral commissures; while the former usually heal well, the cicatrization of the latter is affected by the poorer vascular supply of the sides of the cervix, and results in a greater degree of contraction. The lips of the os gape and the cervical mucosa gradually protrudes (ectropion).

tissue is excised, going into the vaginal vault if necessary (not too deeply, however, on account of the large vessels), and the surfaces of the wound are united. The Martin-Skutsch modification is described on page 89, and the excision of the proliferated mucous membrane in § 14. Sänger designed a hysterotrachelorrhaphy. By these methods the normal shape and size of the cervix are restored.

## ‡ 26. TRAUMATIC STENOSES AND ATRESIAS OF THE VULVA, OF THE VAGINA, AND OF THE UTERUS.

The congenital stenoses and atresias are described on pages 22 to 29, 33, and 36 to 38.

## PLATE 56.

**FIG. 1.—Laceration of the Left Commissure of the Os Uteri, with Marked Ectropion and Ovules of Naboth on the Projecting Hypertrophied Cervical Mucosa.** (See Plates 28; 29, 4; 30; 90, 3.)

**FIG. 2.—Old Ectropion and Congestion of the Cervix.** The mucosa becomes wrinkled from the minute cicatricial contractions of the newly formed connective-tissue fibers (endometritis interstitialis chronica, see Plate 31, Fig. 2).



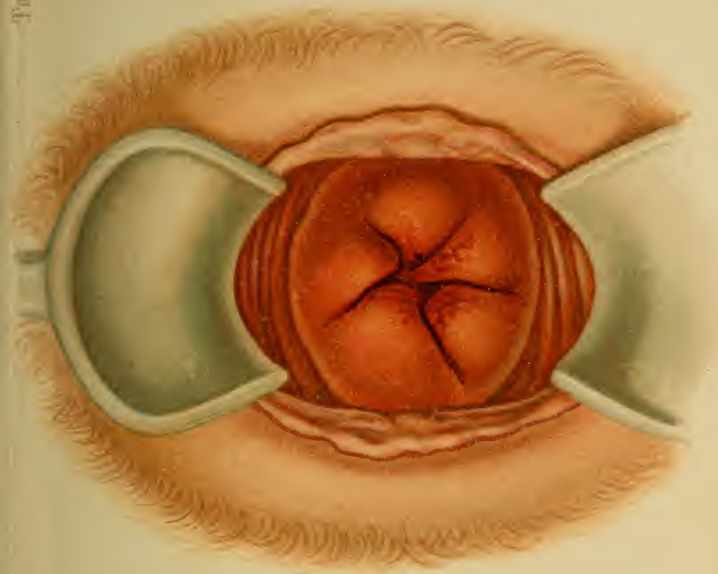


Fig. 2. *Lith. von L. Kochhold. München.*

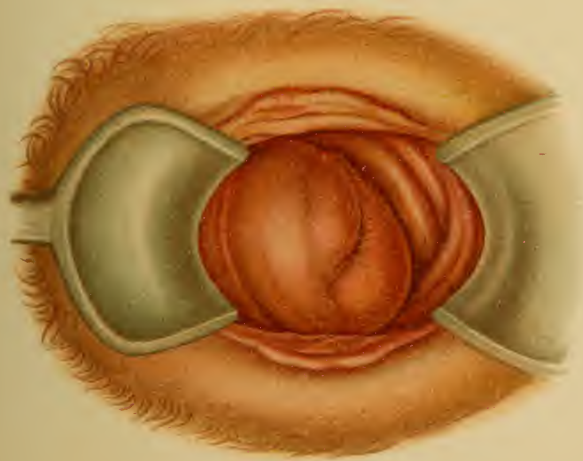


Fig. 1



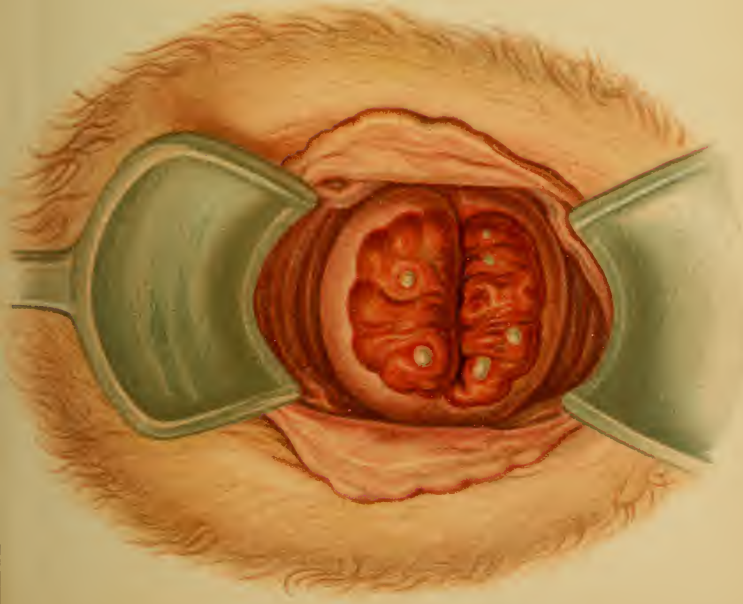


Fig. 4.

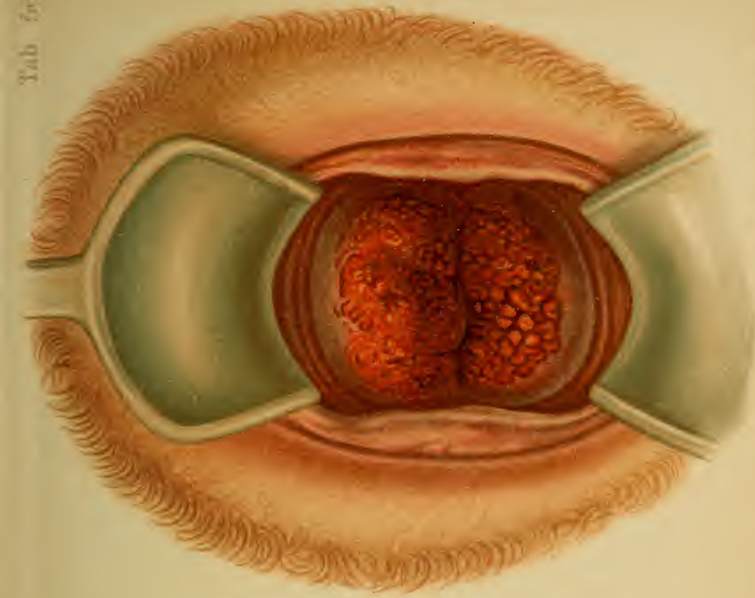


Fig. 3. Tab. 795. F. Reichhold, München.



**Anatomy and Etiology.**—Narrowings, and even cicatricial adhesions, are brought about by chronic inflammatory processes, circumscribing ulcers with marked contraction, too severe cauterizations, and injuries. They are seen in advanced life and in connection with acute infectious diseases.

The ulcerated labia become adherent; the urethral orifice even may be temporarily occluded. There is a retention of blood and of the secretions of the entire genital canal.

Actual obliteration occurs in the vagina, chiefly from cauterization and in advanced age.

The external os is the most frequent location for these agglutinations. It is either contracted to a small, round, cicatricial opening, or subdivided by a bridge of tissue, or retracted by scars into a funnel of mucous membrane. The stenosis may be short and circumscribed or long and tubular, leading, correspondingly, to a membranous or to a cord-like atresia. Atresias of the internal os from too severe cauterizations are rarer; those of the ostium tubæ are still more infrequent. For the anatomic changes see §1 (6).

**Symptoms and Diagnosis.**—Stenosis results in dysmenorrhea and sterility (see § 3), with primary or secondary inflammation. The stasis produces either tension and nausea or colic.

In atresias the more pronounced phenomena first become apparent at puberty (see § 1, 6–8 (*d*)). The diagnosis is made by examination with speculum and sound; in hematometra, hydrometra, pyometra, and lochiometra bimanual examination demonstrates a tense elastic tumor occupying the position of the uterus. In time, perimetritic changes take place.

**Treatment.**—To the operative enlargements by forced dilatation, and by incision of the commissures of the os uteri, described in § 3 (3, 4), may be added a variation of v. Winckel's, which is employed if thickening of the cervix is present. If the cervix is thickened and elon-

gated, it is removed by the elastic ligature ; if it is, however, only thickened and the os narrowed, the operation of Sims (p. 37) is performed, and then small wedges are cut out of the four wound surfaces produced by the commissural incisions. The wedge-shaped defects are sutured as in Sims' method. Lastly, excision of the cervix, according to Kaltenbach, may be performed.

The acquired atresia with hematometra is naturally much more dangerous (from septicemia) than the congenital form. A free incision must consequently be made as early as possible, the uterine cavity carefully washed out with a 2% carbolic solution, and drained by iodoform gauze or by a tube. (See p. 29.)

Hematosalpinx and hematometra with a uterus bicornis are to be removed by celiotomy.

Acquired atresia of the vulva is treated by dividing the adhesions and packing with iodoform gauze, or the raw surfaces may be separately sutured.



## CHAPTER II.

### FISTULAS.

Fistulas are most frequently the result of trauma during delivery. They may be the immediate result of lacerations, or they may arise secondarily from the sloughing of contused parts. Other fistulas are due to pessaries (especially the winged pessary of Zwanck), operations, foreign bodies, accidental traumatism, and perforating ulcerative processes—such as occur in malignant tumors (see Plates 85, 86, 88, 89), diphtheric inflammations of the puerperium, syphilis, vesical calculi, and to the perforation of a perimetritic or parametritic abscess, of a hematocele, or of an extra-uterine gestation sac.

Several fistulas may exist in the same case, as is shown in figures 40, 42, 43, and 48 to 51.

### § 27. CLASSIFICATION OF FISTULAS.

For a more exact study of the more recent works see the classic dissertation of Fritsch in Veit's "Handbook."

#### A. Fistulas of the Urinary Organs.

**Anatomy.**—According to the location of their orifices, these fistulas may be divided as follows:

1. *Urethrovaginal fistulas* (Fig. 37), opening below the tuberculum vaginae.

2. *Vesicovaginal fistulas* (Fig. 39), the most frequent. Every portion of the posterior<sup>1</sup> bladder-wall, as high up as the vertex, may be involved; they are more frequent as the vaginal vault is approached. If the fistula extends to the edge of the external os, it is designated as a:

3. *Superficial vesicocervicovaginal fistula*. (Fig. 38.) This form is of especial importance, because its cicatricial dragging upon the lips

<sup>1</sup> The original reads "anterior."—TRANSLATOR.

of the os uteri gives it a particular influence upon the uterocervical canal. If the os uteri is also torn, we have a :

4. *Deep vesicocervicovaginal fistula* with destruction of the anterior lip. (Fig. 40.) Both 3 and 4 are small, and are found in the median line, because they arise in contracted pelves, from contusion against the symphysis.

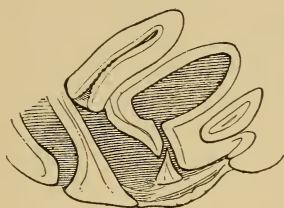


Fig. 37.—Urethrovaginal fistula.

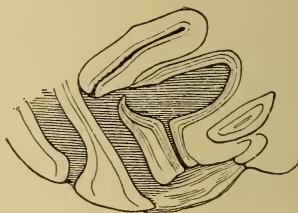


Fig. 38.—Superficial vesicocervicovaginal fistula.

5. *Vesicocervical fistulas*. (Fig. 41.) They represent narrow canals which, from the peculiar anatomic relations of the cervix and vaginal vault, may be combined with vesicovaginal fistulas, since the vesical end may fork (Fig. 42) or two fistulas may coexist.

The tear may be laterally placed, involving the vesical orifice of the ureter. If the other opening is in the vaginal wall, we have a :

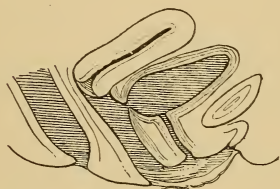


Fig. 39.—Vesicovaginal fistula.

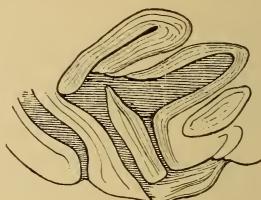


Fig. 40.—Deep vesicocervicovaginal fistula with a defect of the anterior lip of the os uteri.

6. *Vesico-ureterovaginal fistula*. (Fig. 43.) Such a fistula will be found laterally along the course of the ureter or posteriorly in the vaginal vault.

Simple ureteral fistulas arise when the injuries are situated high up; even then they may pass to the vaginal vault as :

7. *Ureterovaginal fistulas*. (Fig. 44.) As in all ureteral fistulas, the orifice is so minute that its recognition is difficult. Its position is

the same as in 6; they frequently empty, as does the urethra, upon a reddened prominence.

8. *Ureterocervical fistulas.* (Fig. 45.)

There are also uretero-intestinal and uretero-abdominal fistulas.

9. *Vesico-abdominal fistulas.* (Fig. 46.) These urinary fistulas are peculiar in their origin. They include different degrees and locations

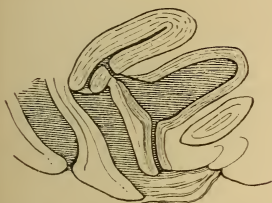


Fig. 41.—Vesicocervical fistula.

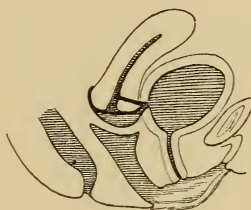


Fig. 42.—Vesicocervicovaginal fistula with colpocleisis.

of the defect. Their occurrence is very rare; they are usually of a congenital nature, rarely the result of perforation into an inflamed adherent bladder.

We designate as fissures:

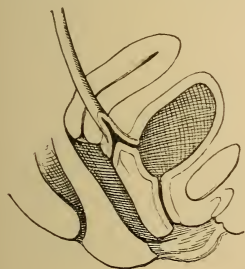


Fig. 43.—Vesico-ureterovaginal fistula.

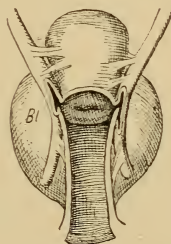


Fig. 44.—Ureterovaginal fistula—bilateral (inflammatory adhesions). *Bl*, bladder.

(a) The *fissura vesicæ inferior*—a cleft beneath the united symphysis, often combined with a fissured clitoris.

(b) The *fissura vesicæ superior*—a cleft above the normal symphysis.

(c) The *fistula vesico-umbilicalis*: *i. e.*, the persistent urachus. This is an actual fistulous tract.

(d) *Eversio* (exstrophia, ectopia) *vesicæ*—clefts of the bladder, with

or without a fissured symphysis. (See § 1.) These are extreme congenital defects.

10. *Ileovesical* or *ileo-ureterovesical fistulas*. (Fig. 51.) Of the communications between the bladder and intestine due to trauma and ulcerative perforations, that with the small intestine is the more fre-

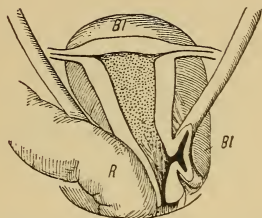


Fig. 45.—Right-sided uretero-cervical fistula: *R*, rectum; *Bl*, bladder.

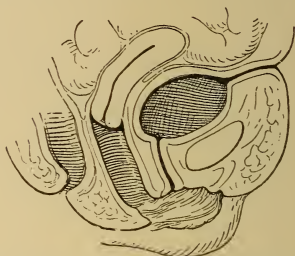

Fig. 46.—Vesico-abdominal fistula (persistent urachus).

quent. There are also fistulas connecting the bladder with the stomach.

11. *Rectovesical* or *recto-ureterovesical fistulas* (Fig. 50) arise from perforating pelvic abscesses.

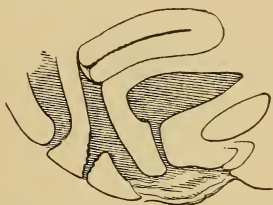


Fig. 47.—Central perforation of the perineum.

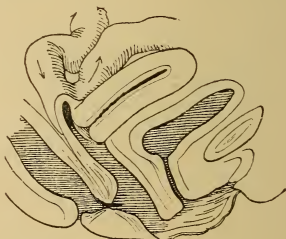


Fig. 48.—Ileovaginal fistula. Rectovaginal fistula (most frequent variety).

## B. Intestinal Fistulas.

1. *Rectovaginal fistulas* (Figs. 48 and 49), or *rectovestibular fistulas* (when outside of the hymen).

2. *Ileovaginal fistulas* (Fig. 48): an opening in the small intestine

empties (usually) into the vaginal vault in such a manner that the greater portion of the feces passes on through the intestinal canal. If the upper end of the ruptured bowel is united with the vagina throughout, complete defecation occurs through this canal. This communication is designated as an :

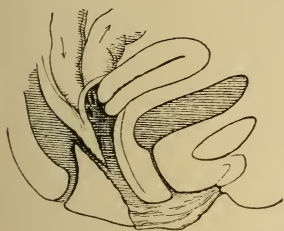


Fig. 49. — Ileovaginal preternatural anus. Rectovaginal fistula.

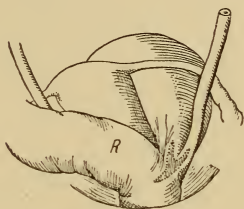


Fig. 50. — Vesico-ureterorectal fistula. Sinistropositio uteri. R, Rectum.

3. *Ileovaginal preternatural anus.* (Fig. 49.) Both varieties are very rare, occurring in both the anterior and posterior peritoneal pockets.

Fistulas vary greatly in shape and size. At first they are usually wide ; later, they undergo cicatricial contraction ; they may pursue a direct or a tortuous course.

Vesicovaginal and rectovaginal fistulas are the largest. The length is dependent upon the mode of origin ; they may be long and multiple, for example, when they follow the perforation of an abscess into two hollow viscera. If the tissue has undergone necrosis from contusion, the surrounding scar tissue is quite extensive ; a clean-cut fistula is surrounded by much healthier walls. In the beginning every fistula is characterized by secretion, and forms granulations.

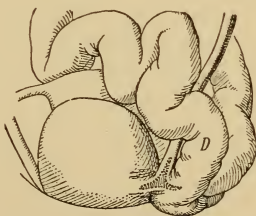


Fig. 51. — Ileo-ureterovesical fistula. D, Ileum in the vesico-uterine pouch.



The concomitant injuries may be so great that it is impossible to find the uterus in the cicatricial mass.

If the urine is constantly emptied through the fistulous tract, the normal passage becomes contracted—or even obliterated, in the case of the ureters and the urethra. In the larger vesicovaginal fistulas the bladder-wall becomes invaginated into the vaginal lumen, giving rise to slight catarrhal inflammations and polypoid proliferations, which may lead to dangerous inflammations of the kidneys. Further results are pericystic irritations and adhesions.

The genital mucous membranes and the vulva become inflamed and incrustated from the constant dribbling of the decomposing urine.

Inflammations of the rectum develop in a similar manner. In perforating ulcerations the fistula pursues an oblique course, the larger primary orifice being the higher. (Fig. 49.)

**Symptoms.**—Incontinence of urine, varying according to the nature of the fistula and the position of the patient; if the vulva is swollen, the urine may be retained in the vagina in the recumbent posture. This incontinence does not come on immediately after the injury, but follows the sloughing of the tissues from pressure necrosis.

1. In urethrovaginal fistulas the sphincter, and consequently the voluntary closure, may be maintained, but the direction taken by the stream of urine is different.

2. In vesicovaginal fistulas (with large orifices not occluded by cicatricial membranes or temporarily blocked by calculi, etc.) permanent incontinence is present.

3. In vesicovaginal fistulas emptying into the fornix and in vesico-uterine fistulas the patient, when erect, can hold her urine until the lower portion of the bladder has become filled; the uterus, in addition, may act as a lever or as a valve—the body drops forward, distorting and displacing the fistulous tract and the cervix may directly occlude it (in vesico-uretero-uterine or vesico-ureterovag-



inal fistulas). In the recumbent posture the urine trickles directly into the vagina.

4. In fistulas of the ureter the emptying of the bladder is voluntary, as only a small amount of urine can escape through the narrow canal; the lesion may be unilateral, only affecting the urine from one kidney. Some of the urine passes through the vagina during urination.

5. In the smaller rectovaginal fistulas only flatus and liquid stools escape involuntarily; in the larger ones there is incontinence of well-formed fecal masses.

The maceration of the tissues by the urine gives rise to a penetrating odor and to catarrhs of the genitalia with ulcerations of the vulva; sleeplessness and loss of appetite occur; the patient feels that her presence is annoying; she isolates herself, becomes unable to work, and falls into a melancholic state. The same is true of fecal fistulas. The general condition passes from bad to worse, and the patient finally succumbs after years of discomfort.

**Diagnosis.**—Fistulas situated in the anterior vaginal wall are the easiest to recognize. If they are as large as the finger-tip, simple digital examination may suffice. A sound or catheter may be passed through them from the bladder.

Small fistulas—especially lateral ones or those emptying into the cervical canal—may be demonstrated by the injection of colored liquids (milk, solution of potassium permanganate) into the bladder and careful inspection of the suspected location through the speculum. The suspicious area is fixed by tenacula and the course of the canal is determined by fine sounds. In vesico-uterine fistulas the external os must be everted, dilated, or incised; stenoses must also be previously removed.

If urine, but not the colored liquid, flows through the genitalia, we have to do with a fistula of the ureter. The uretero-uterine fistula is differentiated from the corresponding vaginal one by the vagina remaining dry after firm tamponade of the os uteri. The exit of the fistula

may be more definitely fixed by giving the patient methylene-blue (0.1) several hours before the examination, and thus coloring the urine.

If doubt exists, the cystoscope may be employed or the urethra may be dilated with Simon's specula and the interior of the bladder palpated. This procedure also gives a clue to the existence of other varieties of vesical fistula (ileovesical, etc.). As a last resort, Trendelenburg performs a suprapubic cystotomy.

In intestinal fistulas conclusions may be drawn from the nature of the fecal mass (ileum or colon-rectum).

**Treatment.**—Operative closure of the fistula is made possible by modern advanced technic. Minute exactness is of even more importance than in colporrhaphy or perineoplasty.

If stenosis of the urethra exists, it must be dilated before the fistula is closed.

Cervical fistulas are operated upon after incising the lips of the os uteri. Ureteral fistulas are closed by means of oval flaps, which are sutured over a catheter introduced into the ureter (after an artificial vaginal fistula has been made—colpocystotomy, to allow of the introduction of the ureteral catheter) (Simon, Schede). The free ureteral end with its surrounding mucous membrane may be excised and implanted into the bladder (Mackenrodt). If the operation is not possible through the vagina, a lateral abdominal section may be made, the peritoneum stripped up, the ureter dissected out along the linea terminalis and sutured into the bladder. The intraperitoneal operation is hazardous.

If the typical operations fail to close the fistula, transverse obliteration of the vagina (colpocleisis, Simon) may be performed: *i. e.*, the vaginal cavity is converted into a reservoir connected with the bladder, an artificial atresia being produced in its upper portion; the lips of the os uteri may be freshened and united by suture (hysteroceleisis). Vesicocervicovaginal fistulas may be closed in an analogous way, either by the lips of the os or by the body of the

extremely anteflexed uterus. The condition brought about by colpocleisis is not very promising; in some cases catarrhs, incrustations, and the like demand the removal of the obliteration. In such a case, nevertheless, the fistula was subsequently permanently closed by v. Winckel.

**After-treatment.**—Antiseptic irrigation of the bladder immediately after the operation (test the completeness of the closure by milk or potassium permanganate). Later, it is necessary to catheterize only if voluntary urination is impossible. A catheter may be introduced and permanently retained. Rest in bed for several days only. Silk sutures are removed on the fifth, silkworm-gut on the eighth, day. Vaginal irrigation only when a fetid discharge exists. If subsequent operations are necessary, they may be performed four weeks later.

Rectovaginal fistulas are in most cases also to be operated upon either by circumscribing them by an oval incision, and uniting their edges by deep sutures, or by the use of vaginal flaps. Very small fistulas, or those combined with anal defects or following perineoplasty, are closed by means of division of the entire rectovaginal septum. Laxatives are previously given for several days; both organs are thoroughly irrigated with antiseptic solutions. During the operation the upper margin of the fistula is drawn down by tenacula and the upper portion of the rectum is plugged with cotton. Subsequent liquid diet and mild cathartics on the third or fifth day are indicated.

In an ileovaginal fistula the spur must first be destroyed by clamp-forceps, so that the fecal contents may pursue their normal course after the plastic closure of the fistulous tract.

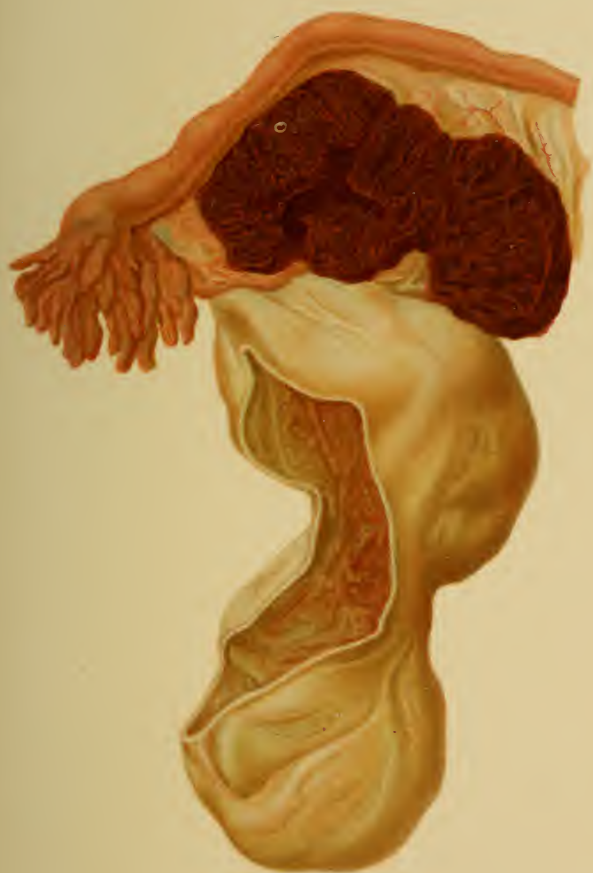Cauterizations by means of fuming nitric or sulphuric acids, chlorid of zinc, Vienna paste, caustic potash, nitrate of silver, the hot iron, or zestocausis are uncertain; they are slow in producing results, and as they render the edges of the fistula hard and nonvascular, the tissues are in an unfavorable condition for later operations. They are of

## PLATE 57.

**Recto-uterine Hematocele in Combination with an Extra-uterine Gestation Sac.** In this mass I found an embryo of three weeks (above and to the left, near to the tube). (Original water-color from a specimen removed at the Heidelberg Frauenklinik.)

---

value in long, narrow fistulas with healthy granulations. Their use may be combined with the retained catheter of Fritsch. (See § 22.)







## CHAPTER III.

### TRAUMATIC EFFUSIONS OF BLOOD.

Traumatic effusions of blood may take place in the connective tissue surrounding the genitalia (hematoma) or into the peritoneal cavity (intraperitoneal hemocele).

#### § 28. HEMATOMA: (a) VULVAR; (b) EXTRAPERITONEAL HEMATOMA (RETRO-UTERINE, PERI-UTERINE, OR ANTE-UTERINE).

(a) **Vulvar hematoma** (see Plate 51, Fig. 1) arises suddenly, with irritation and pain, and forms a tense, elastic, fluctuating, bluish tumor in the labia.

**Treatment.**—Ice-bag and compression; if the skin shows a tendency to break down, incise and pack with iodoform gauze; recovery is slow.

(b) **Extraperitoneal, retro-uterine, peri-uterine, and ante-uterine hematoma** (Plate 58, Fig. 3), especially in the broad ligament and gravitating alongside of the vagina to the pelvic floor. These come on after trauma (such as a fall), with signs of concealed hemorrhage, violent pelvic pain, and disturbances of the bladder and rectum. Fever and peritoneal irritation are absent, unless the broad ligament ruptures and an intraperitoneal hemocele of Douglas' pouch is secondarily formed.

Bimanual palpation shows the pouch of Douglas to be empty; the posterior vaginal vault is pushed down, or a tense elastic tumor may be felt at the side of the uterus.

The internal ligaments may be so slightly lacerated that the effusion of blood can not be discovered by palpation; it may, nevertheless, lead to retroversion and prolapse of the internal genitalia as a result of the acute

stretching of the suspensory apparatus. I have frequently observed such cases in weak individuals after very heavy lifting and falling backward. The first symptoms are pain (lasting for days or weeks), discharge, and menstrual disturbances; they may vanish, if the individual takes proper care of herself, to recur during the menses or after colds. Such cases offer a point of diminished resistance for puerperal or operative infections.

**Treatment.**—The treatment consists of rest in the horizontal position with the head low. Restoratives (ammonia, ether) should be administered. Vaginal tamponade and a sand-bag upon the abdomen are recommended. Incision may be necessary.

## § 29. INTRAPERITONEAL RETRO-UTERINE HEMATOCELE.

**Definition and Etiology.**—Intraperitoneal retro-uterine hematocele comes on suddenly without fever, usually following nonappearance of the menses, as a tense, elastic tumor, which bulges the recto-uterine pouch into the vagina and lies in close contact with the uterus. Elevations of temperature may occur later, and brownish masses of blood are sometimes discharged from the uterus. The abdominal end of the tube not rarely projects into the effusion. The mass of blood is surrounded by layers of fibrin,—probably the result of successive hemorrhages,—and is walled off from the intestines by pseudomembranes. Extra-uterine pregnancy is the usual, if not the only, cause (J. Veit); not rarely villi, or even an embryo, may be demonstrated. In a specimen extirpated at the Heidelberg Frauenklinik I was fortunate to find an embryo at most only three weeks old. (See Plate 57.) The uterus is displaced anteriorly.

The hemorrhage is rarely profuse enough to pass over the broad ligaments into the vesico-uterine pouch.

Other causes are hematosalpinx (in hematometra from

atresia), ruptured varicocele or phlebectasia of the uterine adnexa, rupture of abdominal organs, and hemorrhagic pelvic pachyperitonitis (perimetritis).

**Symptoms.**—Sudden appearance of symptoms of concealed hemorrhage, and pain, resulting from the peritoneal irritation. If the extravasted blood is not infected from the bowel, from the tube, or from the parametrium, absorption proceeds, with apyrexia ; infection produces violent peritoneal pain and fever.

From the uterus : continued discharge of changed blood (conducted to the uterus through the tube, according to v. Winckel).

From pressure upon neighboring organs : neuralgia and dysmenorrhea (ovaries, see § 23 ; from the sciatic plexus into the thigh), disturbances of bladder and rectum.

From further hemorrhage (as is especially the case after a previous perimetritis) : repeated sudden changes for the worse, until absorption occurs or rupture takes place into one of the hollow viscera (most frequently the rectum) with danger of septic infection. After absorption takes place a scar remains.

**Diagnosis.**—Bimanual palpation should be most cautious, in order to avoid exciting further hemorrhage, rupturing the fibrin capsule, or pressing infectious material out of the tubes. The posterior vaginal vault is very sensitive to the touch. All manipulations involving the use of the sound or calling for incision are to be avoided.

The uterus is displaced anteriorly ; the posterior vaginal vault is pushed down by a tense elastic tumor. The space of Douglas is filled out in such a manner that the contour of the tumor is continuous with the uterine fundus ; consequently, confusion with a retroflexed gravid uterus may occur, especially if perimetritis coexists. (For differential diagnosis see Ovarian Cystomata.) The anamnesis and the foregoing symptoms are also to be borne in mind. If the tumor becomes smaller and nodular, with apyrexia, it speaks for hemocele.

## PLATE 58.

**FIG. 1.—Free Ascites in the Upright Position.** In the dorsal position the fluid (serous or bloody) gravitates toward the spinal column. The anterior border of the dullness on percussion is consequently lower. The border passes back in a line concave toward the chest (while tumors have an almost constant area of dullness, which is convex above). In the lateral position the border again shifts; the fluid seeks the lowest side, and the highest portion of the abdomen is tympanitic (where dullness formerly existed). A wave of fluctuation may be obtained.

Ascites occurs in malignant tumors (malignant papillary ovarian cystomata, cancer of the ovary, of the intestine, etc.), peritoneal tuberculosis, and exudative peritonitis (in addition to the obstructive diseases of the heart, lungs, kidneys, liver, portal circulation, etc.).

If the fluid is an exudate (from an inflammatory process—tuberculosis, for example), it contains red and white blood-corpuscles, cells of various sizes with fatty granules (individual cholesterol crystals), much fibrin and albumin,<sup>1</sup> and coagulates quickly; the specific gravity<sup>2</sup> may exceed 1018—a sign of its inflammatory nature. If the fluid is a transudate from stasis, it contains a few blood-corpuscles, flat endothelium from the serosa, no fibrin, and does not coagulate.

**FIG. 2.—Intraperitoneal Retro-uterine Hematocele.** (See Plate 57.)

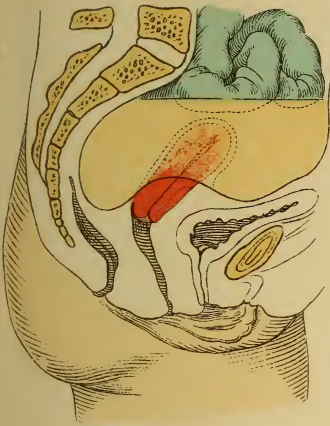
**FIG. 3.—Extraperitoneal Retro-uterine Hematoma.** Uterus retroverted and retroflexed. Douglas' pouch is free, but, like the vagina and rectum, it is bulged out by a fluctuating tumor, which can also be designated as a subperitoneal pelvic hematoma. This tumor is due to the tearing of vessels or organs or to the rupture of a phlebectasia.

**FIG. 4.—Large Subserous Posterior Myoma of the Uterus Simulating a Retroflexion.** (Diagnosis made by sound!) This is given for comparison with the other three retro-uterine tumors occupy-

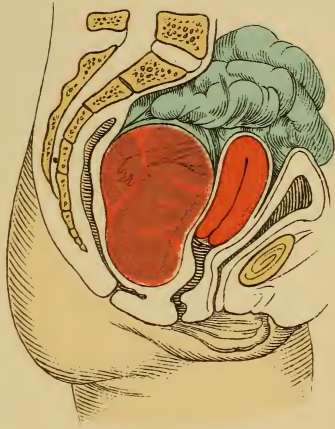
<sup>1</sup> Determination of the amount of albumin: From 10 to 50 c.c. of fluid are diluted with ten volumes of water; heat to the boiling-point and add diluted acetic acid until reaction is slightly acid; the precipitate is washed with water, ether, and alcohol; it is then dried and weighed.

<sup>2</sup> The specific gravity is to be measured at room-temperature. If over 1018, inflammatory exudate, because it contains more albumin.

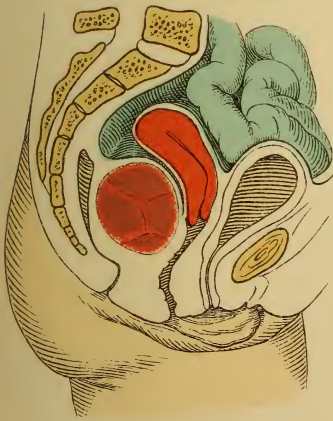




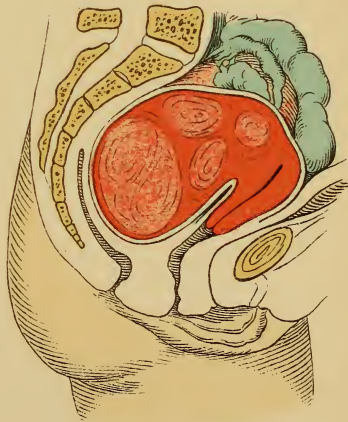
*Fig. 1.*



*Fig. 2.*



*Fig. 3.*



*Fig. 4.*





ing the pouch of Douglas. Anterior position of the uterus. Bulging of the vaginal vault into the rectum by a firm tumor, which grew gradually without fever. The tumor moves with the uterus; bimanual examination demonstrates the connection.

---

**Treatment.**—Absolute rest in bed and the avoidance of all internal therapeutic examinations and procedures. Ice-bag; enemata of opium, morphin, or chloral (to decrease the heart's action). If the collapse continues and there are sufficient grounds for the supposition of an extra-uterine pregnancy (see “Atlas of Obstetric Diagnosis and Treatment”), celiotomy.

If perforation threatens, or if violent pains and elevations of temperature are present, and the tumor remains the same, the most prominent portion is incised through the vagina; the sac is drained and is irrigated daily under low pressure. Ice-bag, bland diet, enemata, mild laxatives. If perforation into the rectum occurs, no examination should be made, on account of the danger of septic infection.

Absorption is to be aided by the measures indicated in § 18. Rest during subsequent menstruations, when fresh hemorrhages easily occur.

**Prognosis.**—The earlier and more appropriate the treatment, the more favorable will be the prognosis for a complete absorption in several weeks or months. In perforation it is dependent upon the degree of antisepsis that can be maintained; rupture into the rectum is the most favorable.

## CHAPTER IV.

### FOREIGN BODIES IN THE GENITAL CANAL AND IN THE BLADDER.

Foreign bodies in these organs may exert an injurious influence either from the injury attendant upon their entrance or from the inflammation produced by their retention in the viscera.

#### § 30. FOREIGN BODIES

owe their introduction into the bladder, vagina, or uterus to a great variety of causes.

(a) Retained instruments—pieces of vaginal nozles, glass specula, incrustated pessaries, needles, tampons, laminaria, retained silk sutures, incrustated pieces of catheter (especially the elastic ones).

(b) Masturbation, perverse or criminal manipulations: hair-pins, needle-cases, candles, lead-pencils, fir cones, pomade boxes, spools; tampons, sponges, and occlusive pessaries (to avoid conception); knitting-needles and other pointed instruments (to produce abortion).

(c) Falls—upon a pointed fence, for example.

(d) Causes originating in the body: perforating tumors, such as dermoid cysts (teeth, hair, analogous to Plate 45, 2, into the rectum), extra-uterine gestation sacs, echinococcus-cysts, fistulas from other hollow viscera. Portions of the ovum remaining in the uterus are also to be classed under this heading. Vesical calculi.

The consequences are depicted in §§ 22, 24, and 25; they are mostly inflammations, ulcerations, and fistulas.

**Treatment.**—The removal of incrustated pessaries is described on page 87.

The genital canal should always be disinfected by irrigation before any foreign body is removed (partly on account of the existing inflammation and fetid discharge, partly on account of the ease with which the mucosa may be injured).

Foreign bodies are to be cautiously extracted with the fingers. If this is not successful, instruments (bullet-forceps or polyp-forceps, tenacula) are to be employed, carefully protecting the vagina from any sharp points. If the foreign body is a long one, it is to be grasped at one end. If this also fails, the object must be made smaller or the parts must be incised. In such cases deep narcosis is necessary.

Foreign bodies in the bladder are diagnosed by the metal catheter, by bimanual palpation, by the cystoscope, or after urethral dilatation.

(See § 22.) The latter procedure is also necessary for their removal : bullet-forceps are introduced alongside of the palpating finger, and the foreign body is seized by one end, if possible, in order to prevent its becoming wedged transversely during extraction. The foreign body may be directly viewed through the speculum. It is sometimes advantageous to fill the bladder with a boric acid solution. If the object is too large, it must be made smaller ; otherwise, colpocystotomy ; in children, suprapubic cystotomy.

From an etiologic, symptomatic, and therapeutic standpoint vesical calculi differentiate themselves not only from other foreign bodies, but also from the same affection in the male. This difference is shown even in childhood. The shortness and the greater width of the female urethra allow concretions the size of a cherry-stone to pass, so that they are rarely able to become calculi by the continued accumulation of uric acid salts.

**Etiology and Symptoms.**—All foreign bodies, including tumors and particles of mucus and pus in vesical catarrh, become incrustated with deposits of salts of uric, phosphoric, and oxalic acids as well as with cystin. All vesical catarrhs and other affections producing complete or partial retention of urine (vesical paralysis, cystocele, diverticula) are also causes of the formation of calculi. Calculi produce vesical catarrh, so that the symptoms of the latter are components of the clinical picture.

The stone irritates the bladder ; hyperemia, hypersecretion, hemorrhages, pain (local and radiating into the genitalia, sacrolumbar region, lower extremities), spasm. The local rubbing leads to ulceration, to perforating abscesses, and to the formation of fistulas. The urine contains clouds of mucus, pus, blood, and squamous epithelium.

**Diagnosis.**—This is made by bimanual examination, introduction of the catheter, cystoscopy, or direct inspection through the speculum, the urethra being more or less dilated and the pelvis raised (Rose's procedure). (See § 22.) The presence of a stone in a cystocele or in a diverticulum may be demonstrated by the cystoscope, or

## PLATE 59.

**FIG. 1.—Left-sided and Posterior Parametritis.** An inflammation of the parametrium (or paravaginal tissues—paracolpitis) arises from puerperal or operative infection (laminaria, intra-uterine pessaries), and extends into the broad and sacro-uterine ligaments. A yellowish, doughy, inflammatory exudate is formed (see Plate 61, 2, and Plate 40, 2), which displaces the uterus. Later, cicatricial contraction occurs, causing further displacement and angulation of the uterus as end-results of the process. Contraction of the sacro-uterine ligaments leads to ante flexion of the uterus; of the septum between the bladder and uterine neck, to retroversion or retroflexion. Other deviations arise if perimetritic adhesions are associated with the parametritis.

Another termination may occur: The inflammation spreads behind the uterus into the pelvic connective tissue and beside the bladder. Abscesses are formed, which rupture into the vagina, rectum, or bladder. They may perforate the abdominal wall above Poupart's ligament or gravitate to the thigh, to the pelvic floor, or through the sciatic foramen, appearing beneath the gluteal muscles.

The acute wound infection may have a fatal termination from severe septicemia.

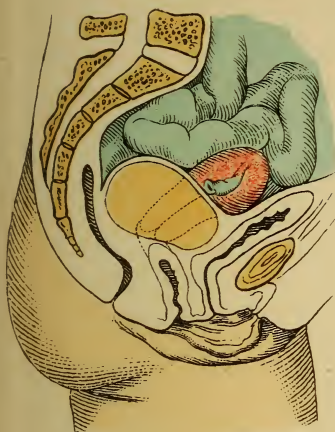
**FIG. 2.—Intraligamentous and Retroperitoneal Multilocular Glandular Mucoid Cyst of the Left Ovary.** This consists of a proliferation of the germinal epithelium of the Graafian follicle<sup>1</sup> or of the superficial cuboid epithelium of the ovary, together with proliferation of the vascular and supporting connective tissue (see Plate 72)—cysto-adenoma.

**FIG. 3.—Left-sided Pyosalpinx.** (See Plates 18, 19, and 39.)

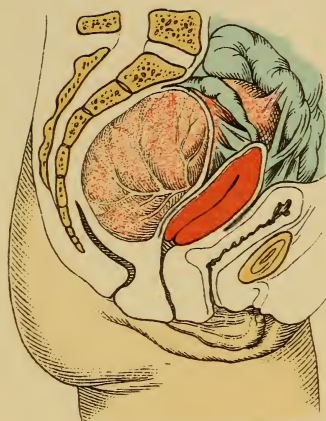
**FIG. 4.—Carcinomatous Cystadenoma of the Ovary.** (Diagrammatic drawing from a case in the Heidelberg Frauenklinik.) The uterus is ante flexed and displaced anteriorly by a myxocystoma. The tumor has become malignant; solid masses have grown into the floor of the recto-uterine pouch and have so surrounded the rectum that a rigid impermeable stricture exists. Ascites, numerous adhesions, and metastases to all organs are seen in such cases. In this case it was necessary to make an artificial anus.

<sup>1</sup> Steffek demonstrated ovula in the young cysts of cystadenomata.

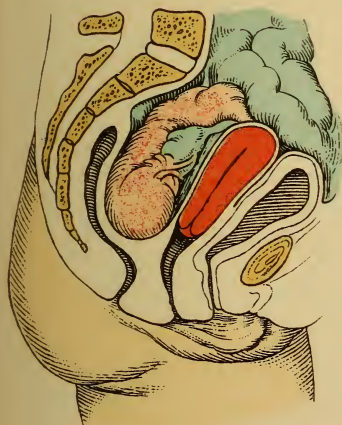




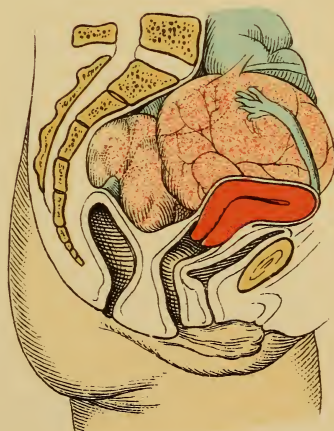
*Fig. 1.*



*Fig. 2.*



*Fig. 3.*



*Fig. 4.*





by means of catheters, after the bladder has been filled with 2% boric acid solution.

**Treatment.**—(a) **Prophylactic:** removal of causes, such as vesical catarrh, cystocele, foreign bodies, fistula.

(b) **Radical**—removal of the stones:

1. Through the urethra, after dilatation of the same. (See § 22.)

2. By colpocystotomy—opening the bladder by a T-shaped incision in the vagina, the upper transverse arm being situated in the vaginal vault close to the anterior lip of the os uteri. If the stone is too large or the genitalia too small:

3. Suprapubic cystotomy (*sectio alta*) is to be performed. The intestines are thoroughly evacuated, and 350 gm. of a warm 2% boric acid solution are introduced into the bladder in order to elevate it and its peritoneum above the symphysis. The incision commences at the symphysis and is from 5 to 7 cm. long, directly in the linea alba (or a transverse incision may be made—Trendelenburg). The fascia transversalis is to be divided for 1 or 2 cm. just above the symphysis. The catheter, already introduced into the bladder, is pressed toward the wound and the bladder-wall is incised. The edges of the vesical wound are to be firmly held.

In this manner the author removed a stone larger than a man's thumb, and bent upon itself at right angles, from a girl fourteen years of age. She had suffered from incontinence of urine for five years, and was not more developed than a child of ten. The incontinence originally was due to prolonged chilling of the lower extremities. The stone was adherent in a right-sided diverticulum. There was vesical catarrh, which caused a slight evening elevation of temperature and an increased pulse-rate. Several months after recovery the child had gained twelve pounds and presented a healthy appearance.

## GROUP V.

### NEW GROWTHS.

---

**Etiology.**—The origin of tumors of the female genitalia, like that of tumors in general, is shrouded in darkness. It is nevertheless striking that organs which undergo such active and variable changes in form, structure, and metabolism, and which are exposed to so many mechanical injuries, bacterial invasions, and nervous irritations, can consequently easily lose their equilibrium of structure : *i. e.*, the normal quantitative relation of the individual tissues.

We observe proliferations in specific infectious inflammations (see §§ 12, 20, and 21) and in chronic congestive inflammations in general. (See Group III, chap. I and § 22.) We are able, further, to observe that in such inflammatory proliferations the normal relation of the epithelial to the connective tissues is gradually lost; the new formation becomes atypical, and assumes a malignant character. (See Endometritis Fungosa and Erosio Papilloides, § 13 and Plate 30.) In the same manner benign proliferations—myxofibromata, for example—may become sarcomatous; pigmented nevi of the vulva have a great inclination to be suddenly transformed into the most malignant melanosarcomata. Repeated cauterizations, excocleations, and unfortunate subsequent infections have without doubt not infrequently furnished the starting-point for a malignant metamorphosis. As in other epitheliomata, the malignant tendency is particularly liable to appear at the time of the menopause.

A connection evidently exists between the origin of malignant epitheliomata and the liability of certain parts

to injury, as is shown both by the predilection of these tumors for the vulva and cervix uteri and by the frequency of their occurrence in multiparæ. This is analogous to the predisposition to mammary carcinoma furnished by the scars of mastitis—whether we suppose the cause to be in the scar itself or in the original infection.

The etiologies of the sarcomata and of the malignant cystomata are unknown; the former are even relatively frequent in childhood or occur congenitally. Dermoid cysts seem to represent a variety of intrafetation.

While the polyps of the mucous membrane are most frequently to be looked upon as circumscribed inflammatory proliferations (endometritis polyposa), there is no etiologic explanation for the proliferation of the muscularis uteri—for the myomata and fibromyomata; indeed, their occurrence is far more common in women who have borne few or no children. Sterility (in spite of regular sexual intercourse) or the causes of sterility are, perhaps, responsible for the tendency of the muscularis to proliferate; secondary proliferation of the mucosa exists often enough, and this may be the cause of the sterility.

It must be remembered that Ribbert and Weigert, and recently Lubarsch also, consider the cause of the proliferation to be a decreased resistance to growth in the surrounding tissues.

## CHAPTER I.

### BENIGN TUMORS.

By benign tumors, from an anatomic standpoint, we understand those that retain the typical structure of the tissue from which they arise, and that do not "eat up" all the surrounding tissues by a predominant proliferation, nor produce further destruction by metastasis. From a clinical standpoint, certain anatomically benign tumors may, nevertheless, be productive of pernicious results to the organism. This chapter treats only of the absolutely benign tumors.

#### § 31. BENIGN TUMORS OF THE MUCOUS MEMBRANES COVERED WITH SQUAMOUS EPITHELIUM (EPITHELIAL TUMORS OF THE BLADDER, VULVA, AND VAGINA, AND TUMORS OF THE STRUCTURES EMBEDDED IN THEM).

The mucous membrane, covered with squamous epithelium, lines the vagina, the vestibule, the bladder and urethra, and, in an extended sense, the vulva. It consists of stratified squamous epithelium resting upon a matrix of cuboid cells, of the connective tissue of the cutis, which forms variously shaped papillæ, and of adipose tissue. The embedded tissues are the lymph-vessels and lymph follicles; blood-vessels, which in the clitoris, the nymphæ, and in the neighborhood of the urethra form erectile cavernous bodies; sebaceous glands—the two glands of Bartholin, lined with cylindric epithelium (see Plates 25 and 26); the similarly clothed small glands and ducts of the urethra (Skene's glands, see Fig. 20) and of the bladder (exceptionally, the vagina has glandulæ aberrantes); and, lastly, muscle-fibers and nerves. The tumors now to be considered may arise in any one of these tissues. We accordingly differentiate:

1. *Papillomata and condylomata*, such as lupus of the vulva (see § 12 and § 20; Plates 29 and 50) and, rarely, of the vagina.
2. *Condylomata (caruncle) of the urethra*. (See Plate 51.)
3. *Papillomata of the bladder*.
4. *Fibromata, myxofibromata and fibromyomata of the vulva*.

5. *Fibromata, myxofibromata and fibromyomata of the vagina.*
6. *Polyps of the mucous membrane or papillary polypoid angiomata, fibromata, fibromyomata of the urethra.*
7. *Polyps of the mucous membrane, fibromata, fibromyomata of the bladder.*
8. *Lipomata of the vulva (usually with a pedicle) and of the vagina.*
9. *Elephantiasis lymphangiectatica vulvæ.* (See Plates 29 and 51.)
10. *Cysts of the vulva (of the glands of Bartholin; of the glands about the clitoris and urethra; occluded sebaceous glands of the nymphæ; hydrocele of the inguinal canal) and cysts of the vagina (which includes—the trimethylamin forming—colpolyhyperplasia cystica).*
11. *Cystic myxo-adenomata of the urethra.*
12. *Cysts of the vesical mucous membrane* (I found them once in the fetus, see v. Winckel's Ber. u. Stud., Munich).

**Diagnosis and Treatment.**—The new growths of the vulva usually become polypoid, and are consequently easily removed with scissors, the knife, or the galvanocautery (or Paquelin's cautery), the latter is particularly adapted for the removal of sessile or very vascular tumors.

**Fibromyomata of the vagina** are rare; they may become so large that they lift the uterus up above the pelvic inlet and disturb the sexual functions as much as similar tumors of the bladder and intestine. If they have a broad base, they are to be shelled out from the surrounding tissues. They sometimes show myxomatous degeneration. In every case it is to be carefully determined whether the tumor is really a vaginal one, or a myoma of the uterus which has been "delivered" into the vagina. The latter tumor may grow fast to the vaginal wall, lose its pedicle, and become a secondary vaginal myoma.

**Vaginal cysts** vary in size and constitution according to their place of origin. They may be the remains of a duct of Gärtner, having cylindric ciliated epithelium and serous contents; of a vagina septa (see Fig. 20); or of a hematoma which has undergone partial absorption leaving behind a more or less blood-stained fluid.

**Treatment.**—Enucleation. When that is impossible, a broad piece of the cyst-wall is excised and the cavity is packed.

The tumors of the urethra are very sensitive and



## PLATE 60.

FIG. 1.—Polyps of the mucous membrane are circumscribed proliferations of the endometrium, both of the body of the uterus and also of the cervical canal; they consist of connective tissue containing numerous glands, partly cystic, and dilated, thin-walled capillaries. (See Plate 71, 1.) They form a pedicle by traction (see Fig. 52) and bleed easily on account of their structure. In contrast to polypoid fibromyomata, they are soft. They are livid from the constriction of the os uteri.

FIG. 2.—**Simple Erosion with Ovules of Naboth.** Uterine fibroid on the point of dilating the os uteri: *i. e.*, about to be “delivered.” (See Plate 62, 2; Plate 90, 4; Fig. 55.)

bleed easily. The pain is often associated with itching, troublesome sexual excitement, or dysuria; it radiates to the surrounding tissues, and may bring on convulsive attacks. Urination is painful, infrequent, or interrupted. If the tumors become larger, they project from the urethral orifice; in other cases they may be drawn out with tenacula, after incision or dilatation of the urethra.

**Treatment.**—The latter procedures must be carried out preparatory to the removal of the tumors by ligation and Paquelin's cautery or the ecraseur (wire snare).

**Papillomata of the bladder** first make themselves

## PLATE 61.

FIG. 1.—**Subserous Polypoid Fibromyoma of the Uterus.** (Original drawing from a specimen in the Munich Frauenklinik.) The tumor is composed of masses of concentrically arranged lamellæ.

FIG. 2.—**Myomatosis Uteri.** Parametritic swelling about the neck of the uterus and vaginal vault. Intramural myomata of the fundus; submucous myoma of the fundus; submucous polypoid fibromyomata of the body of the uterus. The pedicle is elongated and twisted; the tumors have dilated the os and have a dark bluish-red color from the constriction. (Original drawing from a specimen in the Munich Frauenklinik.)

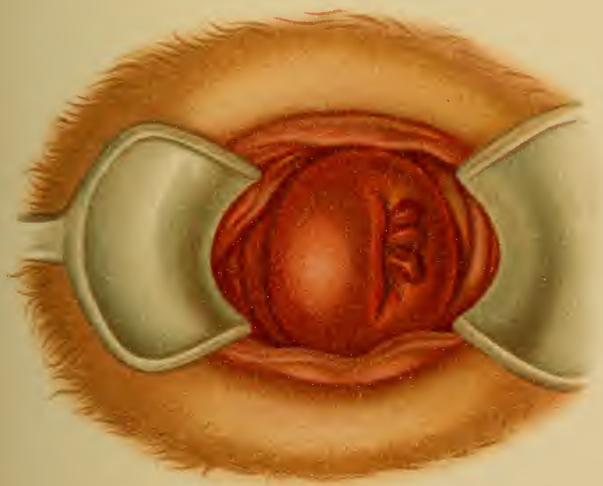


Fig. 1.

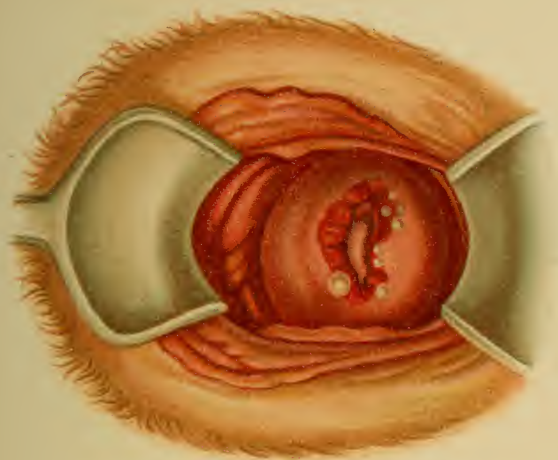
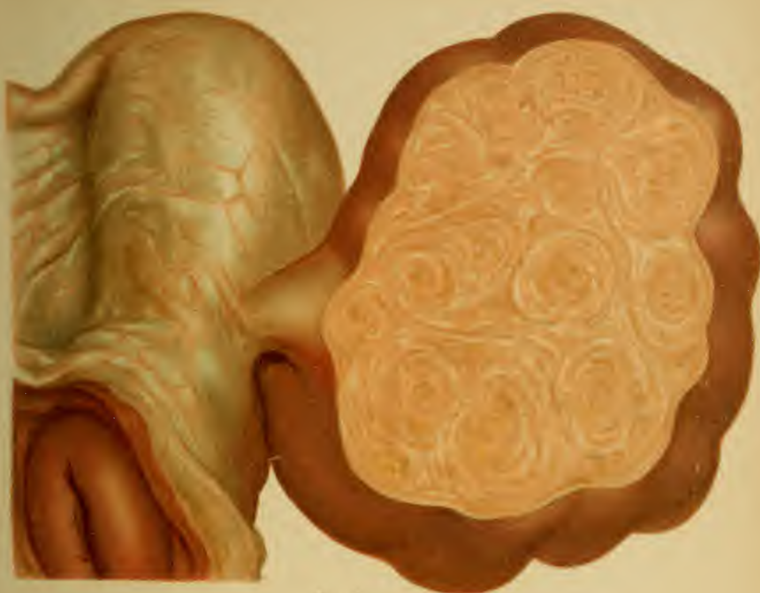


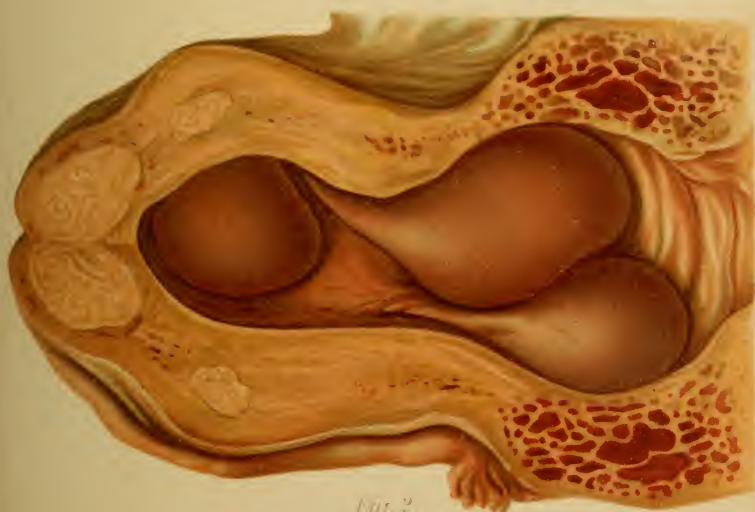Fig. 2.

*Letzt. Abt. F. Reichhold's Museum.*





*Fig. 1*



*Fig. 2*





known by an indefinite feeling of pressure in the vesical region and by early disturbances of urination (increased frequency, tenesmus, ischuria). Violent radiating pains subsequently appear. From the ease with which the surface of the tumor may be injured, frequent hemorrhages occur, producing a particularly striking symptom,—hematuria,—which may lead to a blocking of the urethra during urination by a mass of fibrin. The urine then undergoes decomposition and all the symptoms of vesical catarrh present themselves. Particles of the new growth may also occlude the urethra or cause the formation of calculi.

**Diagnosis.**—When such symptoms are present, cystoscopy or dilatation of the urethra and palpation of the interior of the bladder. Microscopic examination of particles removed by means of the cystoscope. If the tumor is intact, not disintegrated, it is probably a benign growth. Perforating tumors, such as dermoid cysts and extra-uterine gestation sacs, are to be considered.

**Treatment.**—The urethra is to be dilated; the left index-finger is then introduced into the bladder, and the tumor is removed by the wire *écraseur*. If the tumor is sessile or too large, it is either to be incised or crushed bimanually. The hemorrhage is to be controlled by applications of a solution of sesquichlorid of iron or of ferripyrrin, by injections of ice-water, by an ice-bag upon the hypogastrium, and by firm tamponade of the vagina. If these methods are inapplicable, colpocystotomy or suprapubic section. (See § 30.)

**Prognosis.**—The removal of tumors by modern methods is sure, without danger to life, and without permanent incontinence; the new growth easily returns, however, without showing a malignant structure, evidently because the bed of the tumor has not also been removed.

## § 32. BENIGN TUMORS OF THE UTERUS.

As far as their consequences and removal are concerned, the only *absolutely benign tumors* are the mucous polyps

## PLATE 62.

**Several Polypoid Myomata of the Fundus, Which Produced Uncontrollable Hemorrhage at the Time of the Menopause.** Chronic metritis. Congestive swelling of the ovaries. (Original water-color from a case of total extirpation.)

(i. e., the smaller circumscribed proliferations of the mucous membrane) and the stationary subserous, the smaller intramural, and the small slender pedunculated fibromyomata. Of the remaining varieties of myomata, at least 10 % of the *doubtful, often dangerous tumors* are made up of the flat proliferating polyps of the mucous membrane (molluscum), and the large and broad-based fibromyomata, especially the intramural and submucous varieties.

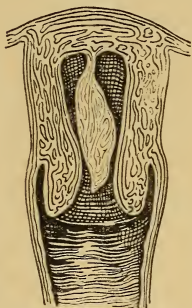


Fig. 52.—Polyp of the mucous membrane of the fundus uteri.

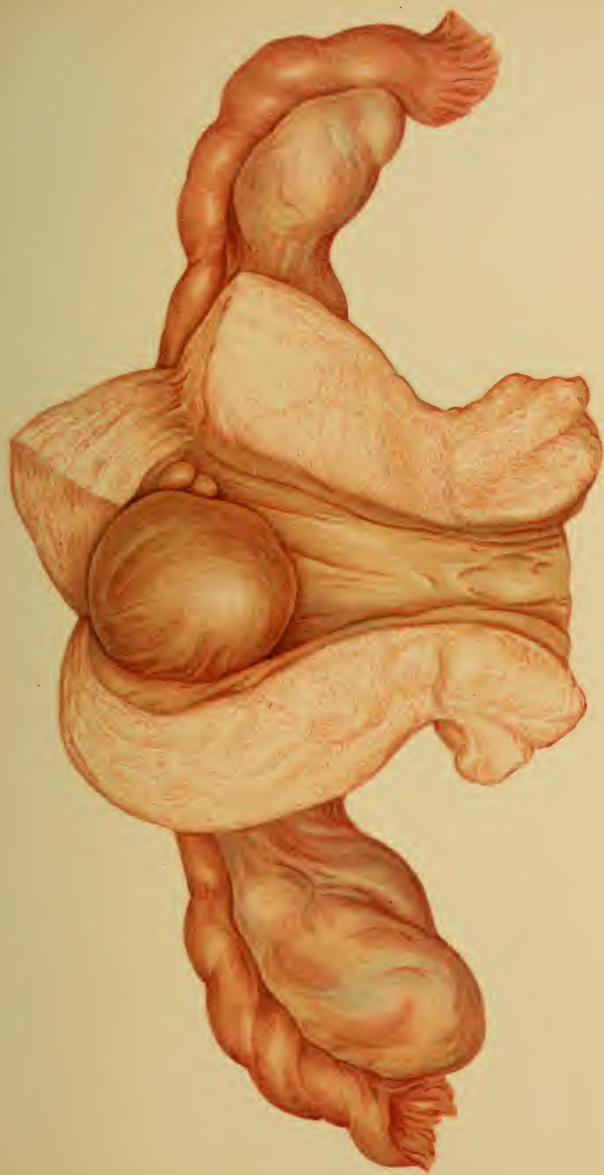The following are consequently benign :

1. **Mucous polyps (benign adenomata):** (a) of the lips of the os uteri; (b) of the cervical and corporeal mucosa. (For Anatomy and Histology see Plates 60, 1; 67; 71, 1; 90; Fig. 52.) They are frequent, usually multiple, often combined with fibromyomata

and projecting from them; they usually remain small.

**Symptoms and Diagnosis.**—Slight hemorrhages are frequent. Since many of these adenomata owe their origin to an endometritis fungosa or decidualis (deciduoma, Küstner), with or without the formation of cysts (ovules of Naboth) (see Plate 90), we have a combination with the symptoms of this disease—above all, anomalies of menstruation.

The adenomata of the lips of the os uteri represent glandular hypertrophies of these tissues, while those springing from the mucous membrane higher up hang





from the latter by a pedicle. Upon this is based the diagnosis by inspection. They are dark red, usually soft, and bleed very easily. As they are forced down against the os they produce a corresponding feeling of pressure and a reflex nausea. Frequently enough, however, such phenomena may be quite overlooked.

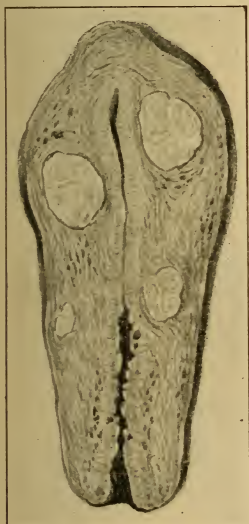

Fig. 53.—Intramural myomata. The myomata of the uterus arise (according to v. Winckel) without exception in the muscularis of the corpus uteri and grow in various directions. (See Fig. 54.) Cysts are seen in the proliferated cervical mucosa.

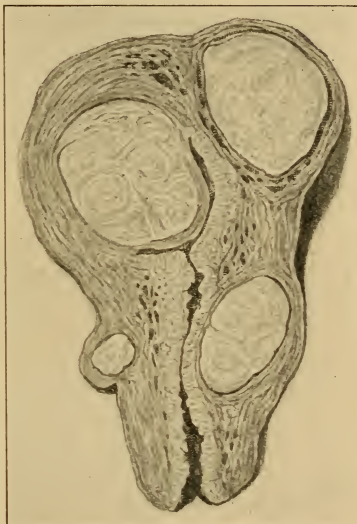


Fig. 54.—Intramural myomata arising in the corpus uteri grow out of the wall in different directions: subserous, submucous, and downward into the wall of the cervix. They are all still inserted by a broad base and surrounded by circularly arranged fibrous tissue with widely gaping vessels. The mucosa is thickened.

**Treatment.**—The easily accessible tumors with a pedicle are to be removed by the wire snare, or they may be ligated and then removed by means of scissors.

If the pedicle of the tumor is difficult of access (Fig. 52),



## PLATE 63.

**Intraperitoneal Surface of an Amputated Myomatous Uterus (Submucous Myoma).** (See Plate 66.) The two surfaces of the incised uterus are drawn apart by the strong elastic retraction of the tumor. The cut surface of the tumors projects above the surrounding tissues on all sides. The ovaries and tubes are covered with small cysts. (Original water-color from a specimen removed by celiotomy at the Heidelberg Frauenklinik.)

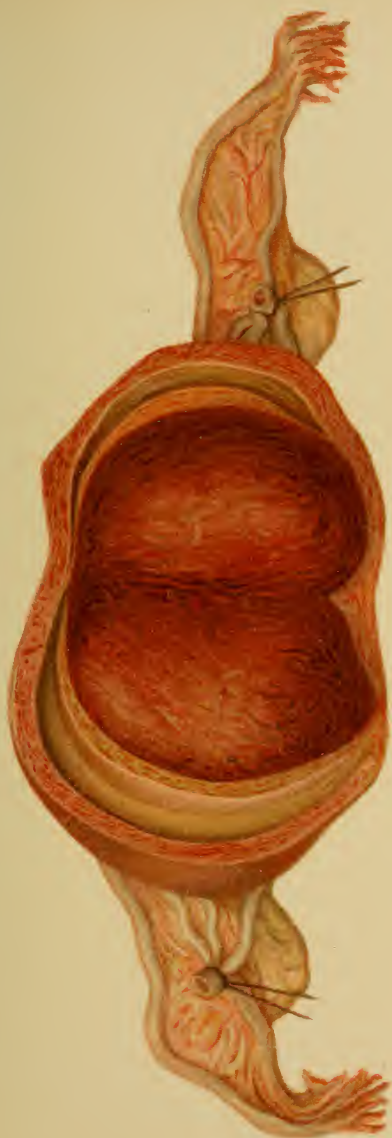dilate the os uteri with well-sterilized laminaria or incise the commissures and enlarge the internal os with metal dilators; then hold the lips of the os open with tenacula; profuse hemorrhage is controlled by suture, Paquelin cautery, or applications of solution of sesquichlorid of iron; firm tamponade with ferripyrin-nosophen gauze from twenty-four to forty-eight hours.

Flat tumors are to be cureted (see § 13 (b)); then the gauze tamponade, as previously; cysts are to be punctured. (Plate 90, 3.)

All these tumors must be carefully removed with their pedicles, or they will recur. If the inclination to return is great, the parts are cauterized repeatedly with chlorid of zinc or solution of sesquichlorid of iron after the removal of the tumor.

**2. Fibromyomata with an Absolutely Benign Course.**—Stationary intramural (parietal) myomata, small submucous or polypoid submucous fibromyomata, not causing marked hemorrhage, and small subserous or polypoid subserous fibromyomata. (See Fig. 53, and Plates 14; 15, 4; 18, 1 and 2; 67; 90, 4.)

**Anatomy and Histology.**—We differentiate histoid and organoid myomata. The histoid fibromyomata consist of nonstriated muscle-cells and of partly dense, partly areolar, connective tissue. (See Plate 71, 2.) They arise in the muscularis of the body of the uterus. They are at first intramural (intraparietal), and grow out in various





directions. (See Figs. 53–55.) They commence in the neighborhood of vessels, and their origin probably has some connection with vasomotor disturbances of growth.

The organoid myomata are the adenomyomata (v. Recklinghausen, 1896): *i. e.*, myomata with glandular and cystic inclusions, which v. Recklinghausen demonstrated

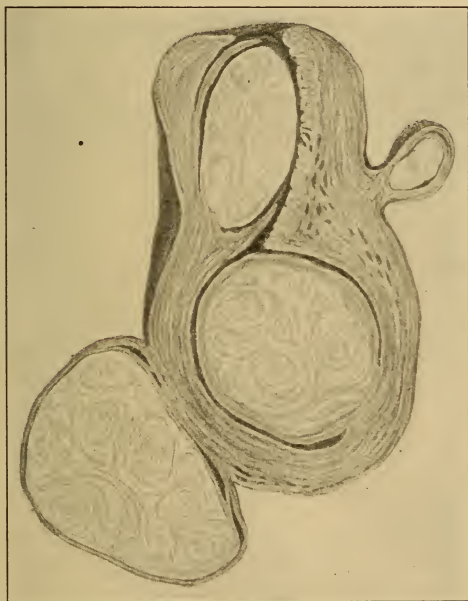


Fig. 55.—The tumors commence to become pedunculated as polypoid subserous and submucous fibromyomata. The myoma of the cervix, arising from gravitation, begins to shell itself out from its surroundings. Circular arrangement of fibers within the tumors.

to be partly postfetal from the epithelium of the uterine mucosa, consequently derived from the epithelium of the Müllerian ducts (adenomyomata of the mucous membrane), and partly remains of the Wolffian body (parophoritic adenomyomata). The adenomyomata are most

## PLATE 64.

**Several Bleeding Myomatous Polyps of the Fundus.**

(Original water-color from a specimen in the Path. Inst. at Munich—Bollinger.)

intimately connected and interwoven with the muscularis; they are not encapsulated, as are the histoid myomata.

The adenomyomata of the mucous membrane may also be due either to a general or local penetration of the mucosa into the uterine wall, or to isolated, misplaced, fetal rudiments of the uterine mucosa (Landau), in which case the presence of a cytogenetic connective-tissue capsule speaks for their origin from the Müllerian ducts.

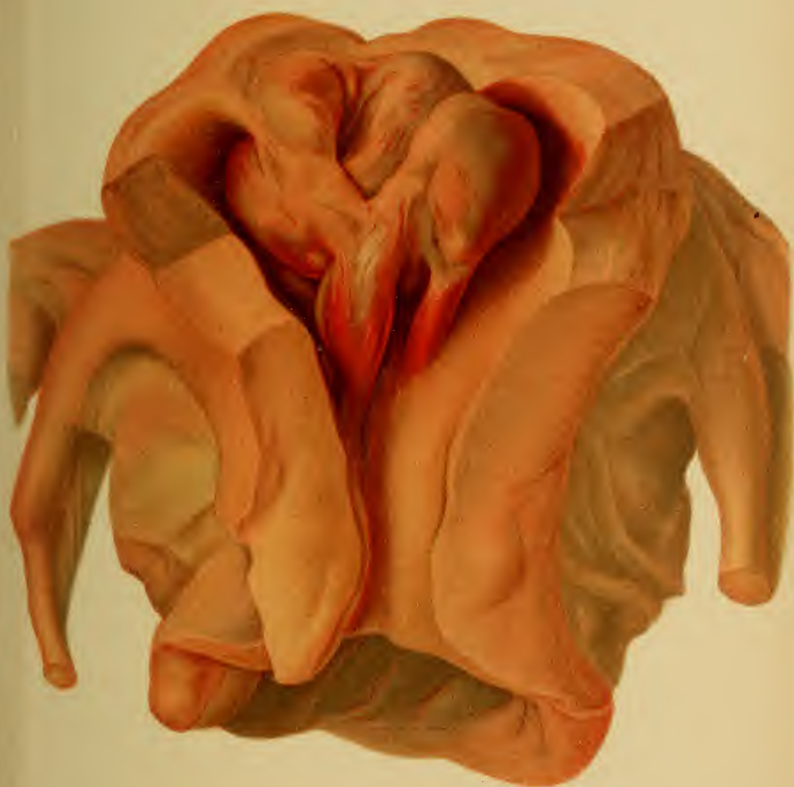According to location we differentiate :

1. *Intramural fibromyomata.* (Figs. 53, 57 to 59, and Plate 61, 2.)
2. *Submucous fibromyomata.* (Figs. 54, 55; Plates 63 and 66.) The tumor has a broad base and is still partly in the uterine wall.
3. *Polypoid submucous fibromyomata.* (Fig. 55 and Plates 61, 2; 62, 64.) The tumor has a pedicle and projects into the uterine lumen.
4. *Cervical fibromyomata.* (Figs. 54 and 55 and Plate 65.) The tumor (intraparietal) has gravitated into the cervical wall.
5. *Subserous fibromyomata* (Figs. 54 and 55 and Plates 43 and 65.) The tumor causes a projection of the peritoneum.
6. *Polypoid subserous fibromyomata.* (Fig. 55 and Plates 61, 1; 67.) The tumor is connected to the uterus by a pedicle and projects into the peritoneal cavity. It may form adhesions with neighboring organs and thus have two pedicles; if the primary pedicle becomes obliterated, the new growth seems to spring from the other viscus.
7. *Intraligamentous fibromyomata.* The tumor grows in between the layers of the broad ligament.
8. *Intercorporeal fibromyomata in a double uterus.* The tumor forms the septum.

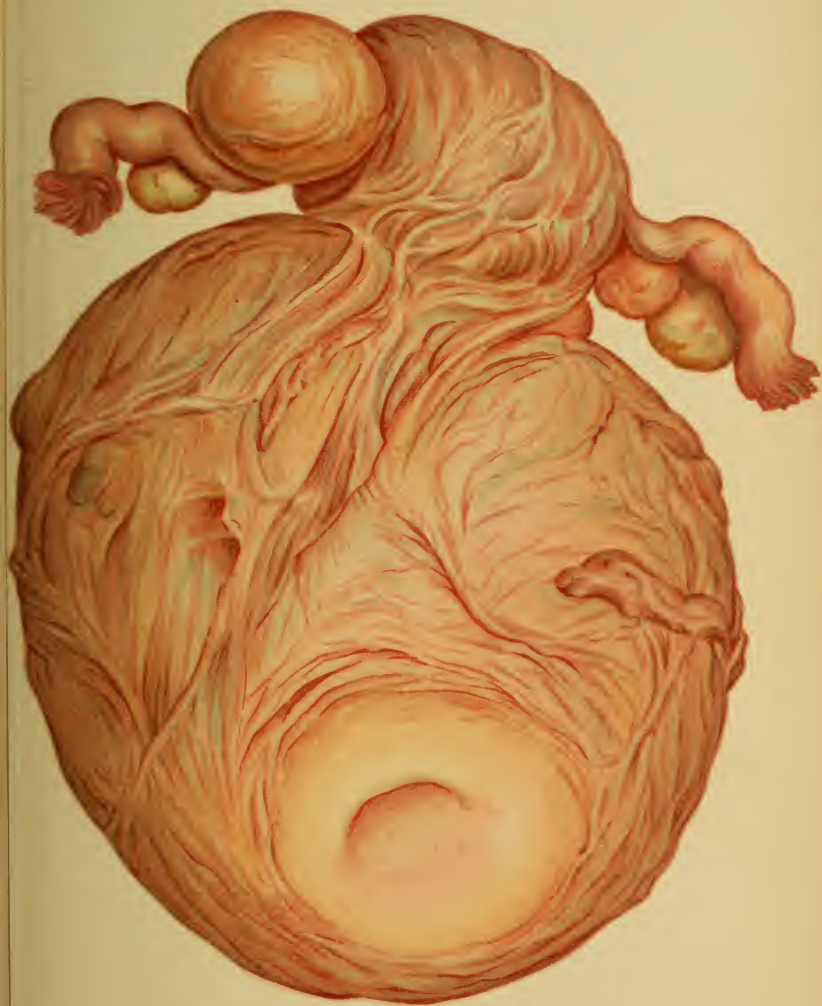## PLATE 65.

**Completely Extirpated Myomatous Uterus.** The posterior lip of the os uteri (very anemic from profuse hemorrhages), as well as its appurtenant cervical wall, is transformed into a myoma larger than a man's fist. Adenomyomata at the insertions of the tubes. (Original water-color from an operative specimen at the Heidelberg Frauenklinik.)











A special group of the paroophoritic adenomyomata is made up of the voluminous juxta-uterine and subserous varieties; for both, although they pass diffusely into the uterine muscularis, may be isolated from it (Landau); they may separate themselves spontaneously and be found as solitary tumors in the broad ligaments.

Isolated glandular and cystic deposits are found in histoid myomata as accidental embryonic displacements of the epithelium, or analogous to the frequent combination of submucous myomata and "mollusca" of the neighboring endometrium (Virchow), since the enveloping endometrium of submucous and polypoid myomata sometimes passes into the muscular tissue in a striated manner.

**Symptoms.**—As can be deduced from the foregoing statements, these tumors throughout can be looked upon as "absolutely benign" only as long as they are small. Their earliest possible diagnosis and removal is consequently of the greatest importance.

*Initial Symptoms.*—All the phenomena are independent of the size of the tumors. The most violent boring pains, produced by the tension, are particularly characteristic of the small intramural new growths. These pains are exaggerated by all congestive conditions (menses, cohabitation, constipation) and by exploratory palpation of the uterus, which is neither necessarily enlarged nor displaced. These pains radiate into the surrounding tissues, and cause reflex neuralgias in the sacral and lumbar regions, in the face, etc.; they make up a large part of the hysteric symptom-complex which is present in patients otherwise apparently in good general condition.

Hemorrhage first appears as a menorrhagia; later, as an irregular metrorrhagia.

*Cause.*—Partly glandular endometritis over the tumor; as soon as the last muscle-fibers between the new growth and the mucosa have disappeared, however, the proliferation of the interstitial tissue causes a fungous endometritis, or multiple adenomatous new growths (Wyder). In other cases the uterus is unable to contract sufficiently to close the



## PLATE 66.

**Inner Surface of a Uterus with an Incised Intramural Submucous Hemorrhagic Myoma of the Posterior Wall.** (See Plate 63.) (Original water-color from an operative specimen at the Heidelberg Frauenklinik.) The anterior wall of the supravaginally amputated uterus is opened, and the entire uterine cavity is filled by a round, tense, elastic tumor, which has been divided into two halves and thrown to each side. By bimanual palpation a deceptive fluctuation was apparent, due to the fact that the muscular tissue was completely saturated with blood.

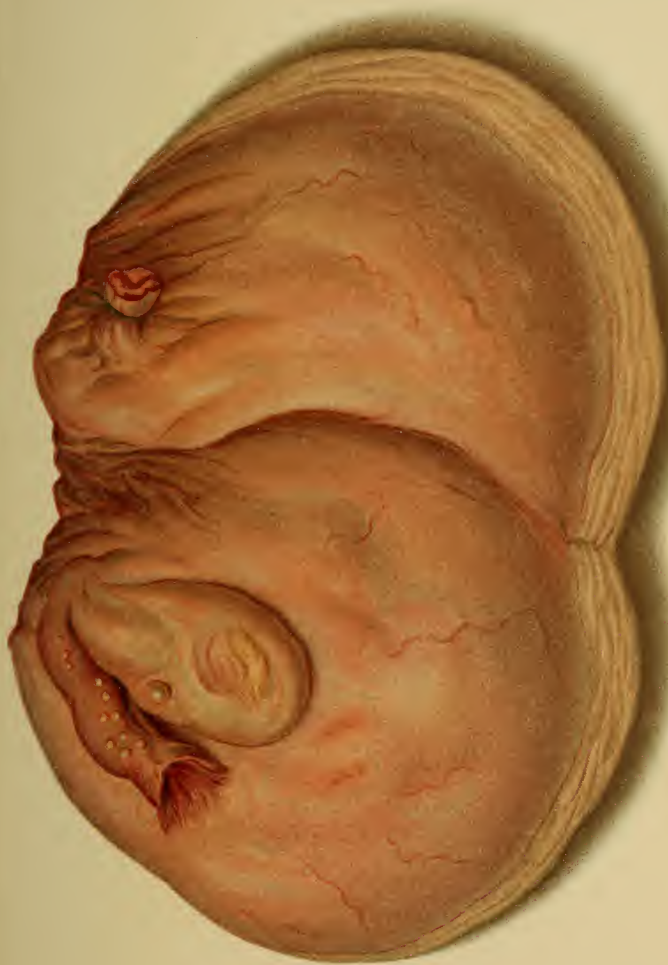---

vessels of the myoma (Landau). The contractility of these vessels themselves is evidently insufficient.

These hemorrhages appear early, and, corresponding to their cause of origin, almost without exception in intraparietal and submucous myomata. They frequently continue after the menopause.

If the tumor grows out of the uterine wall, escaping its tension, and is small and of the subserous variety, the initial pains cease and there are no further pressure phenomena; if it becomes submucous, distending the uterine cavity (Fig. 54), new labor-like pains appear and the leukorrhea and hemorrhage become more profuse. These pains bring about a dilatation of the os uteri. (Plate 60.) If the tumor-tissue yields, the pedicle becoming long-drawn-out, the complete "delivery" of the mass occurs.

**Diagnosis.**—Small intraparietal myomata, as well as diffuse homogeneous substitutions of the endometrium by adenomyomata, are not to be recognized by bimanual palpation. We suspect their presence from the apyrexia, with initial violent boring pains, and, later, menorrhagia and metrorrhagia. These symptoms demand the palpation of the uterine cavity (after dilatation, with or without incision of the commissures of the os), which reveals submucous or polypoid prominences, or different degrees of density of the uterine wall.





Later, the obliteration of the os uteri (Plates 60, 61, and Fig. 55) may be recognized by inspection.

For differential diagnosis see page 219. Above all, pregnancy must be excluded before dilatation of the os uteri (menstruation is not absent, cervix is not so livid nor so soft).

**Treatment.**— Prophylactic: ergotin subcutaneously (0.05 gm. daily, for months and years) to cause the tumor to contract and disappear. Ergotin also checks the hemorrhage, as does stypticin and hydrastin—the former by exciting the involuntary muscle-fibers in the vessel-wall to contraction, the latter two through the vasomotor nerves.

These measures are rendered more effective by hot vaginal irrigations (117° to 127° F., one or more liters several times daily or every two hours), and, further, by depletives, especially before the period: mild laxatives, salt baths, salt inunctions, applications of alcohol.

If the hemorrhages do not cease, the vagina is to be firmly packed with iodoform gauze or cotton tampons; if this is without avail, cotton is wrapped about Playfair's aluminum sound, soaked in ferripyrin or chlorid of iron solution, and applied to the uterine cavity, or even left there for several hours. Ergotin subcutaneously and by mouth (as *extractum secale cornutum*<sup>1</sup>). The author uses tampons the size of the finger, saturated with ferripyrin or gelatin emulsion. These are left until extruded by the uterus.

If the uterine cavity is dilated and its walls are relaxed, ferripyrin, solution of sesquichlorid of iron, or gelatin should be injected by Braun's syringe. Great caution must be exercised: the syringe should not contain over two cubic centimeters of fluid; the syringe is to be withdrawn as the injection is made; it is better to inject into gauze (previously introduced) than against the mucous membrane.

<sup>1</sup> See Therapeutic Table.

Anemia resulting from hemorrhage is to be treated symptomatically, see § 4, under 7 ; for the dysmenorrhea and neuralgia see § 4, under 8, and, in addition, salt or brine baths (Kreuznach, Tölz) and applications of mud, brine, or hot alcohol to the abdomen.

Fibroid and mucous polyps are to be removed by operation. If the tumors are large, their size is to be decreased by longitudinal or spiral incisions or by the excision of

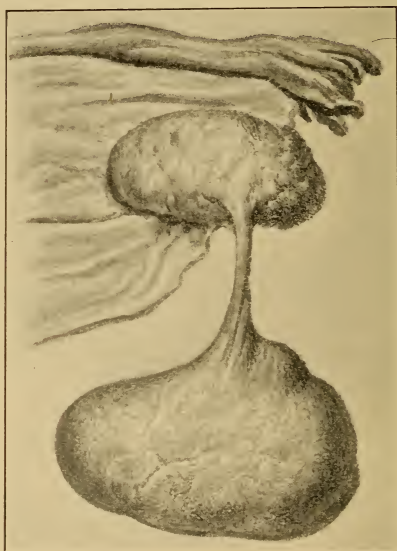


Fig. 56.—Myxofibroma of the ovary with a long pedicle (rare).  
(Specimen at the Munich Frauenklinik.)

pieces, until the enucleation of the pedicle is possible. The uterine cavity is then to be disinfected and packed with iodoform gauze.

Small submucous tumors are removed after dilatation of the cervix ; the overlying mucous membrane is incised, and the tumor is seized by the vulsella forceps of Muzeux and is shelled out of its bed. If the dilatation is insufficient,



the bladder is dissected free and the anterior cervical wall is divided to a point above the internal os.

Cervical myomata that have grown into the parametric connective tissue are removed after incision of the vaginal mucous membrane (Czerny). Vaginal tamponade.

### § 33. BENIGN TUMORS OF THE UTERINE ADNEXA.

The new growths proceed from the visceral serosa of the adnexa, with its subserous connective tissue, and the involuntary muscle-fibers of the broad and round ligaments; from the mucous membrane and muscularis of the tube; from the cuboid germinal epithelium of the ovary; and from the ovarian connective-tissue stroma.

We have the following :

1. *Papillary proliferations of the tube* : circumscribed or diffuse, with or without cyst formation in the tubal mucosa; of an infectious nature.

2. *Fibromata and fibromyomata, including paroophoritic adenomyomata and adenomyomata of the mucous membrane* (Plate 60) *of the tube* : solitary, from the size of a pea to that of a child's head; multiple, as a result of inflammatory proliferation (salpingitis nodosa, combined with hyperplasia of the mucosa and cyst formation) in the uterine isthmus of the tube, which is rich in muscle-fibers.

3. *Small fibromata and fibromyomata of the ovary* may develop from the corpora candiantia or fibrosa. (Plate 40, 3.) Under certain conditions they may become very large; they then lose their benign character, partly because they show a tendency to malignant degeneration, partly because they act as an obstacle to delivery. They may have a cystic or cavernous structure.

4. *Fibromyomata and adenomyomata of the round ligament* are very rarely intraperitoneal;<sup>1</sup> they are more frequent in the inguinal canal.

5. *Fibromyxomata and fibromyomata of the broad ligament* may grow to the pelvic outlet and simulate hernias. The latter must not be confused with intraligamentous uterine myomata and adenomyomata.

6. *Lipomata of the tubes and of the broad ligament* are rare; the former are only the size of a bean, the latter may weigh fifteen kilograms (thirty-three pounds).

7. *Cysts of the tubes and of the broad ligament, of serous origin* (with the exception of the mucous cysts mentioned under 1 and 2), are small and only occasionally of importance, inasmuch as they may become pedunculated (hydatids,<sup>2</sup> such as Morgagni's) and contract adhesions

<sup>1</sup> I found such a tumor at autopsy. It was round, as large as a small potato, and in the middle of the broad ligament. This position is very rare ("Samml. d. Münch. Frauenklinik"; v. Winckel's "Ber. u. Stud.," 1884-'90).

<sup>2</sup> This formation of hydatids is a frequent occurrence. I found them 45 times in 130 autopsies; in 8 of these several hydatids coexisted; in 3 cases 2 vesicles had the same pedicle. Several were calcified. Small cysts of the broad ligament were found 15 times; 5 of these were calcified. I have seen them repeatedly in the fetus.



with the intestinal coils. Those cysts situated in the anterior layer of the broad ligament are to be considered as remains of the canals of the Wolffian body; the others, however, are to be looked upon as pedunculated fimbria with epithelial inclosures.

8. *Unilocular cysts of the ovary* are due to dropsy of the follicles. (Plate 68, 1.) The multilocular cysts of the ovary are without significance only as long as they are small.

9. *Parovarian cysts* arise from the remains of the Wolffian duct (probably also from the remains of the Wolffian body between the parovarium and the uterus). These growths commonly remain small, but they may attain the size of a walnut or an apple and cause trouble. They are located between the ovary and the tube, and may be multiple. The cyst is always unilocular; the wall is thin and consists of endothelium and subserous connective tissue with elastic and involuntary muscle-fibers; it is lined with either ciliated or non-ciliated cylindric epithelium.

The contents are clear and are poor in albumin and consequently watery (of diagnostic importance regarding tapping). The fluid contains cylindric cells and has a specific gravity of 1005.

Paroophoritic cysts are found in the course of the uterus as far as the upper portion of the vagina (Gärtner's duct has been demonstrated up to this point in the fetus—Klein). Veit includes in this classification the large vaginal cysts, which extend into the broad ligament.

**Symptoms and Diagnosis.**—*Ovarian fibromata*, see Ovarian Cystomata and the following section.

*Ovarian cysts* (unilocular), see Ovarian Cystomata; also Oligocystic Degeneration, § 17. An ovary may show cystic changes without being enlarged. Nevertheless, pains exist, especially at the menstrual epoch, during palpation, or during defecation, which is usually difficult. These pains are referred to the sacrum, sometimes as the so-called "intermenstrual pain." (See § 17.) Dysmenorrhea follows, or, if the disease is bilateral, amenorrhea and sterility.

This painful affection, usually of an inflammatory nature, gradually stamps itself on the features of the patient—*facies ovarica* (lips pressed together, angles of the mouth drawn down and the surrounding skin correspondingly furrowed, wrinkled and furrowed forehead, sunken cheeks, prominent cheek-bones, and pointed nose).

If the tumor attains the size of a child's head, symptoms arise from the displacement of the uterus and from

pressure upon the rectum, bladder, vessels, and nerves (desire to urinate, constipation, hemorrhoids, phlebectasia, neuralgias in the lower extremities, etc.). It is at this point that the ovarian cysts cease to be unimportant.

The diagnosis of ovarian cysts is made by bimanual palpation (also through the rectum). A pedunculated tumor is found beside the uterus; the tumor replaces the ovary of this side.

*Parovarian cysts* first give rise to symptoms when they reach to the pelvic inlet. They produce disturbances of the circulation in the broad ligament, and consequently interfere with the nutrition of the ovary. This results in anomalies of menstruation.

They may be recognized as fluctuating tumors at the side of the uterus, distinctly differentiated from it, and upon puncture yield a fluid with the previously described characteristics. They rarely return after being tapped.

**Treatment.**—Parovarian cysts may be tapped. Those containing a fluid richer in albumin are to be removed by celiotomy. If the tumor has a pedicle, the operation is a simple one. If strong adhesions exist, remove as much as possible and unite by suture. [Celiotomy and complete removal should take the place of tapping.—ED.]

Intraligamentous cysts are to be dissected out from the surrounding connective tissue, or the corresponding portion of the broad ligament is to be excised.

Ovarian cysts not larger than an apple are to be removed only when the disturbances they produce are unbearable. Iodid of potassium is to be given in solution or in vaginal suppositories (as an absorbent) until iodism is produced. To alleviate the disturbances: warm fomentations to the abdomen and applications of iodin; rest during the periods. If pelvic peritonitis appears, rest in bed and the ice-bag are indicated. Regular movements of the bowels are to be secured. (See also § 35.) [Ovarian cysts presenting symptoms should be removed.—ED.]

## CHAPTER II.

### TUMORS OF BENIGN STRUCTURE THAT MAY BECOME DANGEROUS UNDER CERTAIN CONDITIONS.

#### § 34. THE FIBROMYOMATA.

All the large, progressively increasing myomata of the vagina, uterus, and ovary that are not polypoid (intraligamentous and intraparietal growths, and those with broad bases) belong to the group of fibromyomata that are followed by serious consequences (mortality, 10 %).

The dangerous results of these tumors are :

1. Extreme anemia and secondary cardiac disease, produced by the continued hemorrhage (later, the dilated, thin-walled vessels may rupture).

2. Hemorrhages may also occur into the substance of the tumor. (Plate 66.) The cause is usually a disturbance of the circulation with thrombosis (this sometimes leads to fatal emboli after operation). These extravasations suppurate easily, and thus cause sepsis.

3. Torsion of the pedicle <sup>1</sup> in large subserous polyps leads to necrosis and inflammation ; in the submucous polyps, to ulceration and putrefactive gangrene.

4. Inflammatory adhesions are formed with the intestines.

5. Submucous polyps may lead to inversion of the uterus (Figs. 24 and 57-59) if they proceed from the fundus and if the formation of a pedicle is made difficult by

<sup>1</sup> There are cases in which the uterus itself, instead of the pedicle, is twisted about its axis, or even torn open at the internal os. The tumor may become separated from the uterus, and obtain its nourishment through previously existing intestinal and omental adhesions.

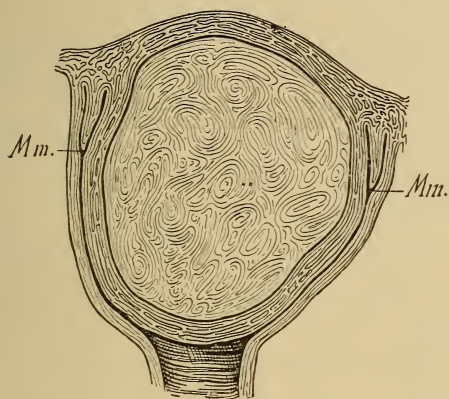


Fig. 57.—Intramural fibromyoma of the uterine fundus, projecting into the vagina. *Mm.*, Os uteri.

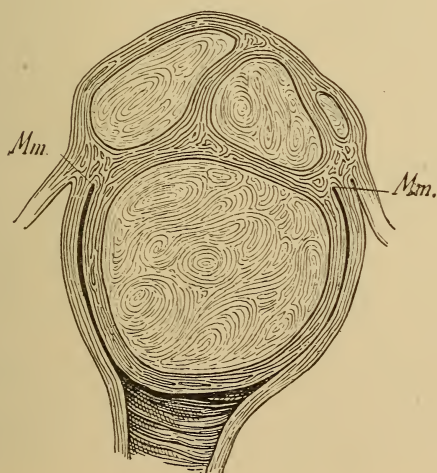


Fig. 58.—Multiple intramural myomata of the fundus. Submucous myoma of the fundus projecting into the vagina. *Mm.*, Os uteri.

## PLATE 67.

**Polypoid Subserous Fibromyoma ; Polyps of the Mucous Membrane in the Dilated Cervical Canal.** (Original water-color from a specimen at the Path. Inst. at Heidelberg.)

---

numerous strong muscle-fibers from the uterine muscularis extending into the tumor. Further consequences : pressure necrosis, gangrene.

6. The large size of the tumor (some of them may weigh eighty-five pounds, especially if they are the seat of cystic degeneration) may cause obstruction or distortion of the pelvic organs, <sup>1</sup> or may interfere with delivery. They are particularly dangerous when they are calcified.

Cysts arise from myxomatous degeneration, from absorbed extravasations, or from the edematous softening of muscle-fibers (due to compression or infectious thrombosis of the vessels).

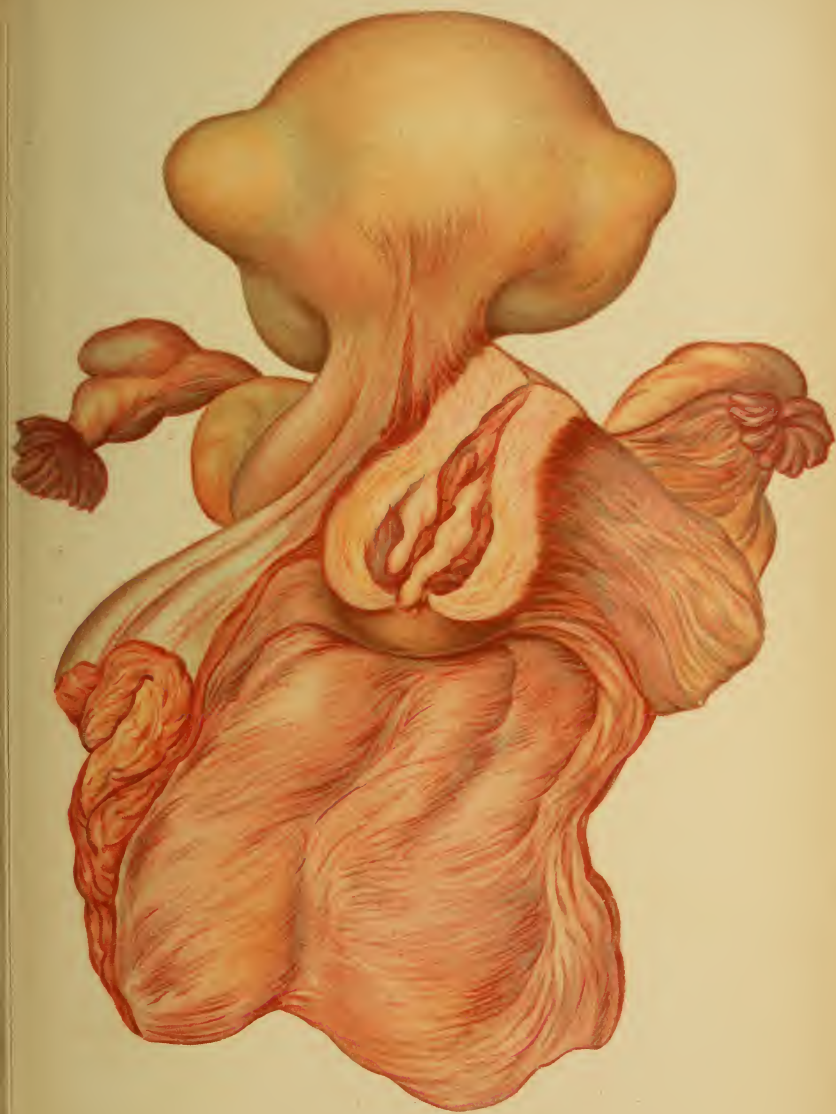
7. Intramural tumors may undergo fatty or calcareous changes, remaining stationary or becoming smaller. They may be the seat of myxomatous degeneration ; they then show an inclination to be transformed into myxosarcomata (Plate 87, 2 ; 73, 1), sometimes with intermuscular pseudocysts (Plate 73, 3), which arise from the destruction of round cells or from blood extravasations.

8. The central portions of the tumor may undergo primary metamorphosis into a fibrosarcoma. Primary carcinomatous degeneration of the tumor itself or of the proliferated uterine mucosa may take place. Malignant degenerations occur at the menopause in  $4\frac{1}{2}\%$  of all cases (Fehling).

9. The dangers of operative removal are hemorrhage and suppuration. If the tumors are sessile or are located deep in the uterine wall, necessitating the opening of the uterine cavity, peritonitis may occur, either from primary

<sup>1</sup> Occlusions of the intestines, bladder, and ureters, which lead to intestinal obstruction, absolute retention of urine, uremia, incontinence with secondary cystitis, pyelonephrosis, etc.









infection or from the later rupture of an abscess of the stump.

Finally, lung emboli are more common than in operations upon other large genital tumors. All these dangers are more pronounced when the patient is profoundly anemic.

**Symptoms.**—*Vaginal myomata*—only pressure symptoms.

*Large uterine myomata* (for initial symptoms see § 31). If *intramural*, menorrhagia, and, in addition, pressure

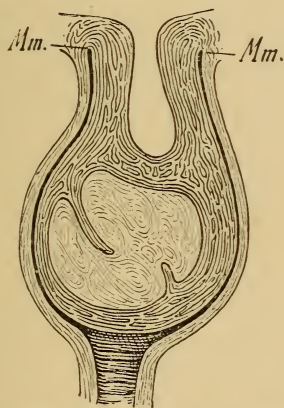


Fig. 59.—Intramural fibromyoma of the fundus uteri producing an inversion of the uterus. *Mm.*, Os uteri.

symptoms, as in all these larger tumors. (Plates 63 and 66.)

If *submucous*, menorrhagia and metrorrhagia with violent colicky pains, as the tumors twist the uterus and often occlude the outlet for the discharge. Slight perimetritic pains are present. Sterility or abortion is frequent. The tumors easily undergo suppuration during the puerperium.

If *submucous and polypoid*, all the symptoms of the simple submucous variety, and, in addition, labor-like

pains, since the uterus tries to expel the pendulous myoma. When the polyp lies in the vagina, it becomes edematous and the seat of a foul ulceration. A constant, nonremittent fever exists even when a fetid discharge is not present. This is due to interstitial infection of the tumor. (Plate 61, 2.) Catarrhal discharge is profuse because the irritation of the fibroid polyp causes the mucous membrane to proliferate *in toto*. Multiple mucoid polyps may consequently arise.

If *subserous*, the symptoms are few, often not more marked than the pressure symptoms of the pregnant uterus (dyspnea; reflex irritation of the breasts is not often absent). The tumor may irritate the peritoneum or may produce reflex neuralgias from pressure.

In *cervical myomata*, menorrhagia and profuse leukorrhea. (Plate 65.)

With very rare exceptions the tumors contract during the menopause; the climacterium is, nevertheless, not rarely prolonged by marked hemorrhages. The author saw regular periods from this cause in an American woman, fifty-seven years of age.

In *ovarian fibromyomata* the symptoms are very uncertain: sometimes absence of the menses or ascites.

**Diagnosis.**—*Vaginal Myomata*.—It must be determined whether the tumor actually springs from the vaginal wall, or is simply adherent to it, as uterine polyps may contract secondary adhesions with the vagina.

*Intramural Uterine Myomata*.—The wall of the organ is hypertrophied and the uterine cavity is elongated. Metritis and pregnancy must be excluded. In the former the wall is not so dense and the sound is not made to deviate from the straight line by the presence of a tumor. In the latter the cervix is livid and the entire organ is strikingly soft; the increase in size occurs in a typical way; the menses are absent.

If one suspects *submucous* or *polypoid myomata*, the uterine cavity is to be palpated after dilatation of the cer-

vix. The sound is to be passed first; the cavity is enlarged, but the sound passes around the tumor or can not effect an entrance. At the menstrual epoch the tumor separates the lips of the os (Plate 60, 2; 61); traction with the bullet-forceps gives information as to whether the tumor has a long pedicle or a broad-based insertion.

If such tumors are very large (Fig. 57), and if they project far into the vagina, it is often difficult to determine their true origin without bimanual examination through the rectum and the employment of the sound.

*Cervical myomata*, especially if they have undergone suppuration, must be distinguished from epitheliomata of the cervix. The former have a pedicle leading into the os uteri; when broken down, they have a loose fibrous structure and a brownish-red or pale rose color. The epitheliomatous nodules are softer; they crumble and bleed easily; they are always outside of the external os; they undergo ulceration without the production of polypoid excrescences. The microscope shows fibrous tissue in the one case, epitheliomatous plugs of cells in the other. (Plate 71, 2; 79.) Fibromyoma differentiates itself from sarcoma by its greater density, slower growth, painlessness, and absence of foul discharge with particles of tissue. The transition from myoma to sarcoma is consequently characterized by the appearance of these symptoms and by ascites. Fibromyomata have been mistaken for placental polyps, and also for inversion of the uterus. (For diagnosis of the latter see § 7.) Placental polyps, like polyps of the mucous membrane, are softer. They contain decidual cells, glandular epithelium, and chorionic villi.

It is often difficult to diagnose *subserous and intraligamentous uterine myomata* from tumors of the adnexa and from tumors of the pouch of Douglas. This is partly owing to the fact that they completely fill the rectovaginal culdesac, and partly because they may be embedded in the exudate of a pelvic peritonitis. (For differential diagnosis see following section, under Ovarian Cystomata.) The

sound demonstrates the course of the uterine canal, so that we know where to look for the tumor and where to look for the uterus. (Plate 58, 4.)

Bimanual examination is employed to determine whether the uterus moves with the tumor. This method of examination is of especial importance if the tumor is a subserous polyp with a long pedicle. (Plates 61 and 67.) The density of such tumors is also to be observed. Fibroid cysts or very edematous tumors may show fluctuation, thus resembling ovarian cysts.

The diagnosis is made by tapping. The fluid from the cystic myoma is lymph; it coagulates and contains only lymph-corpuseles. In simple myomata nothing is obtained but blood. The differential diagnosis from ovarian fibromata is sometimes impossible.

A vascular bruit may be heard upon auscultation in 66% of all myomata; rare in cystomata.

If a myoma undergoes suppuration, it becomes intensely painful and fluctuates. Septic jaundice and fever make their appearance.

*Ovarian Fibromata.*—The chief point is the ovarian origin of the tumor. The further diagnosis is made by the density of the new growth.

**Treatment.**—Operative interference is indicated if the treatment with ergotin (Hildebrandt), as given in the previous section, is fruitless and the tumor continues to grow and to produce threatening symptoms. This treatment is to be considered useless if the menorrhagia is not decreased by the daily injection of 0.2 gm. of ergotin for two months (*i. e.*, after at least from sixty to eighty injections).

The larger submucous tumors are to be removed piecemeal through the vagina (fifty-two pieces in one of v. Winckel's cases); suppurating tumors are to be cautiously removed by means of the polypus-forceps under continuous irrigation—*colpomyotomy*.



Enucleation, in the true sense of the word, is often impossible, as the intramural and submucous myomata are rarely, the adenomyomata never, encapsulated. It is difficult to remove the tumor, as the finger works in the uterine wall in the dark. Hemorrhage is controlled by injections of hot water and by tamponade. Sepsis occurs only too easily.

If such a case is foreseen, it is better to incise the overlying mucous membrane, to administer ergot, and to allow the uterus to expel the tumor. The tumor may be made smaller by morcellement (Péan) and the uterus removed. Ligation of both uterine arteries is recommended as a palliative measure.

There are three methods for the removal of the tumor by celiotomy :

I. *Myomotomy* : *i. e.*, removal of the tumor from the uterus, which is left uninjured.

II. *Supravaginal amputation of the uterus* : *i. e.*, removal of the uterine body, together with its myoma, from the cervix.

III. *Total extirpation of the uterus* (Fritsch, Küstner, Martin, Mackenrodt).

IV. *Castration* : *i. e.*, the removal of both ovaries. A premature menopause is produced, since experience teaches that myomata frequently grow smaller at this time. This measure is not absolutely certain in its results.

It must be carefully determined whether the disturbances and dangers due to the tumor are greater than those of the operation (embolism ; fatal hemorrhage ; sepsis, especially from the opened uterine cavity, see foregoing).

Indications for the operations :

1. Severe exhausting hemorrhages.
2. Inability to work.
3. Such rapid growth that life is apparently threatened, especially in cystic degeneration.
4. Abscess formation in the tumor.
5. Torsion of the pedicle with symptoms threatening the life of the patient.

I. Myomotomy is applicable to subserous polyps and to those subserous and intramural myomata that may be shelled out of the uterine wall. (Plate 61, 1 ; 67.)

If the uterine cavity is opened, or if only the mucous membrane remains as a thin layer—

II. Supravaginal amputation is to be performed.

The question of the necessity for and of the manner of amputation frequently remains undecided until the abdominal cavity is opened. It is indicated in the broad-based subserous tumors, in the large or multiple intramural growths, and in intraligamentous or degenerated (cystic, cavernous, carcinomatous, suppurating) myomata that do not project into the uterine cavity. (Plates 63, 66.)

An elastic tube is applied about the uterus and adnexa (laterally from the ovaries). The broad ligament is then ligated close to the uterus (Zweifel) in three portions, from the suspensory ligament of the ovary (infundibulopelvic ligament) to a point as low down as possible,



## PLATE 68.

**FIG. 1.—Unilocular Ovarian Cysts.** Two cysts were situated in such a manner that one of them forced its way into the other. (Original water-color from an autopsy at the Heidelberg Path. Inst.)

**FIG. 2.—Thin-walled Multilocular Glandular Muroid Cyst.** The pedicle, together with the tube and a hydatid, lies upon the tumor. The furrow is due to the impression of the iliopectineal line, as the smaller portion of the cyst was in the pelvis and filled the pouch of Douglas. (Original water-color from an operative specimen.)

and the uterus, with tumors and adnexa, is removed. If intraligamentous tumors are present, the broad ligament is incised and ligated on both sides in three portions.

The stump may be treated according to various methods :

1. *Schröder's Intraperitoneal Method.*—Wedge-shaped excision (cauterizing the stump with concentrated liquid carbolic acid, zinc chlorid, or Paquelin's cautery). The mucosa, the muscularis, and the serosa are sutured separately (etage suture) with catgut.

There is danger of secondary infection : *i. e.*, of abscess formation in the stump and rupture of the united serosa. A large stump should consequently be avoided, as portions of it may undergo necrosis.

2. *Péan-Hegar's Extraperitoneal Method.*—Long needles are passed through the stump at right angles, fixing it in the lower angle of the abdominal wound outside of the peritoneum. The serosa of the stump is sutured to that of the abdominal wall. The stump is covered only by the abdominal muscles.

It undergoes necrosis and is cast off, together with the elastic tube, after two or three weeks.

The disadvantage of this method consists in the permanent traction upon the bladder.

Fritsch unites the stump as does Schröder, using sagittal instead of transverse sutures, and sews it into the lower angle of the abdominal incision. On the ninth day he removes the coaptation sutures of the stump from the bottom of the wound.

3. Chrobak fixes the stump behind the peritoneum (consequently an extraperitoneal method) by covering it with a peritoneal flap previously excised either from the tumor or from the uterus.

III. Total extirpation guarantees the greatest security against secondary infection of the peritoneal cavity from the secreting or partly necrotic stump obtained by the supravaginal method; <sup>1</sup> it is, however, a more radical operation. In certain cases it is absolutely indicated,

<sup>1</sup> At the Heidelberg Frauenklinik, in 1896, thirty myomotomies were performed (the stump being treated by the retroperitoneal method) with two deaths, one from pulmonary embolism, one from severe anemia.

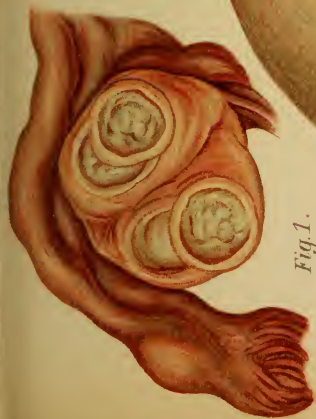

Fig. 1.

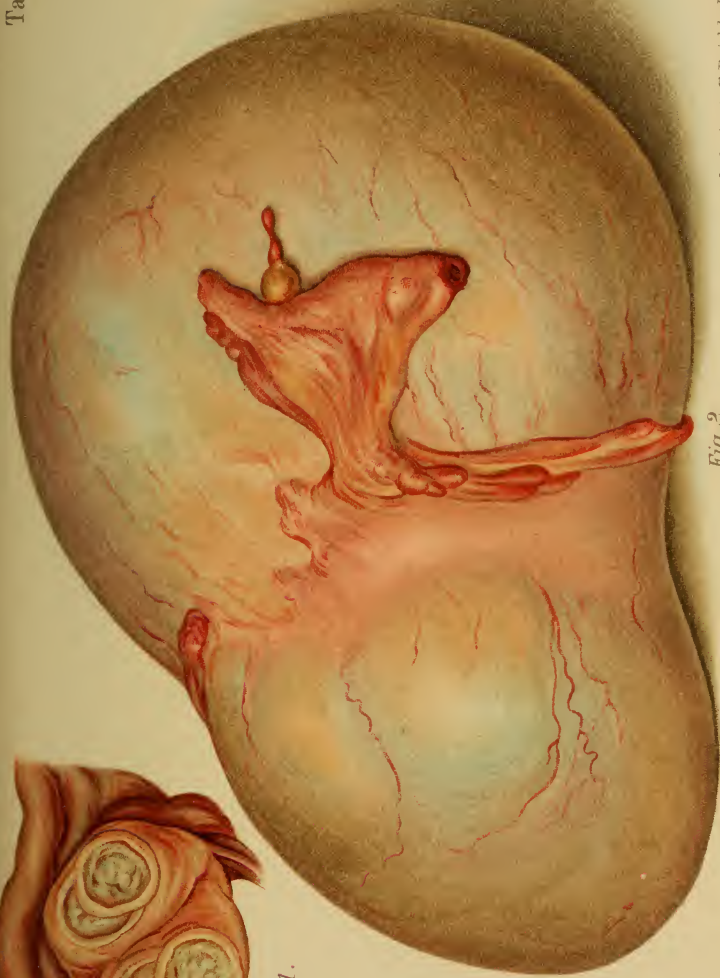

Fig. 2.

Lith. Anst. F. Reichhold, München.



as in pyosalpinx (Plate 42) and cervical myomata (Plate 65). The ovarian arteries are ligated, transverse incisions are made in the vesico-uterine and recto-uterine excavations, and the ligaments are successively ligated and divided. The neck is amputated in such a manner that a very small portion remains behind with the external os (the orifice may be cauterized). This wound is to be united by some nondraining suture material (silkworm-gut). Catgut ligatures are used in the parametritic cellular tissues and in the serosa.

IV. Hegar's castration is only a makeshift. It is to be performed only when the removal of the myomata must be looked upon as dangerous to life (very large myomata with multiple subserous nodules preventing their removal from the pelvic cavity). The operation has a mortality of 16%, because the ovaries are frequently so close to the tumor that the ligation of the vessels is very difficult. In many cases the looked-for result has failed to appear. The ligation of the uterine arteries from the vagina is a better operation (Gottschalk).

The operative removal of ovarian fibromata is indicated, even if they are of only moderate size and stationary, on account of the danger of malignant degeneration. Hemorrhage, especially from the adhesions, is the chief danger of the operation. The elastic rubber tube is used, and the pedicle is tied off with broad, strong ligatures before the removal of the tumor.

The preparatory treatment and after-treatment in all these celiotomies are the same as in the removal of ovarian cystomata.

### § 35. THE OVARIAN CYSTOMATA.

**Definition, Anatomy, and Histology.**—The multilocular glandular mucoid cyst arises from a proliferation of the germinal epithelium of the Graafian follicle,<sup>1</sup> together with a supporting and vascular proliferation of the connective tissues (see Plate 72)—cystadenoma.

Five varieties of ovarian cysts may be differentiated:

1. *Unilocular cysts* (Plate 68, 1)—hypertrophic ovarian follicles (hydrops folliculorum).

2. The *multilocular glandular mucoid cyst*—a nodular complex of many smaller cysts, filled with viscid mucus (greenish-yellow to grayish-black according to the admixture of blood) and surrounded by a single outer wall. (Plate 72.)

<sup>1</sup> Steffek demonstrated ovula in the young cysts of cystadenomata.

## PLATE 69.

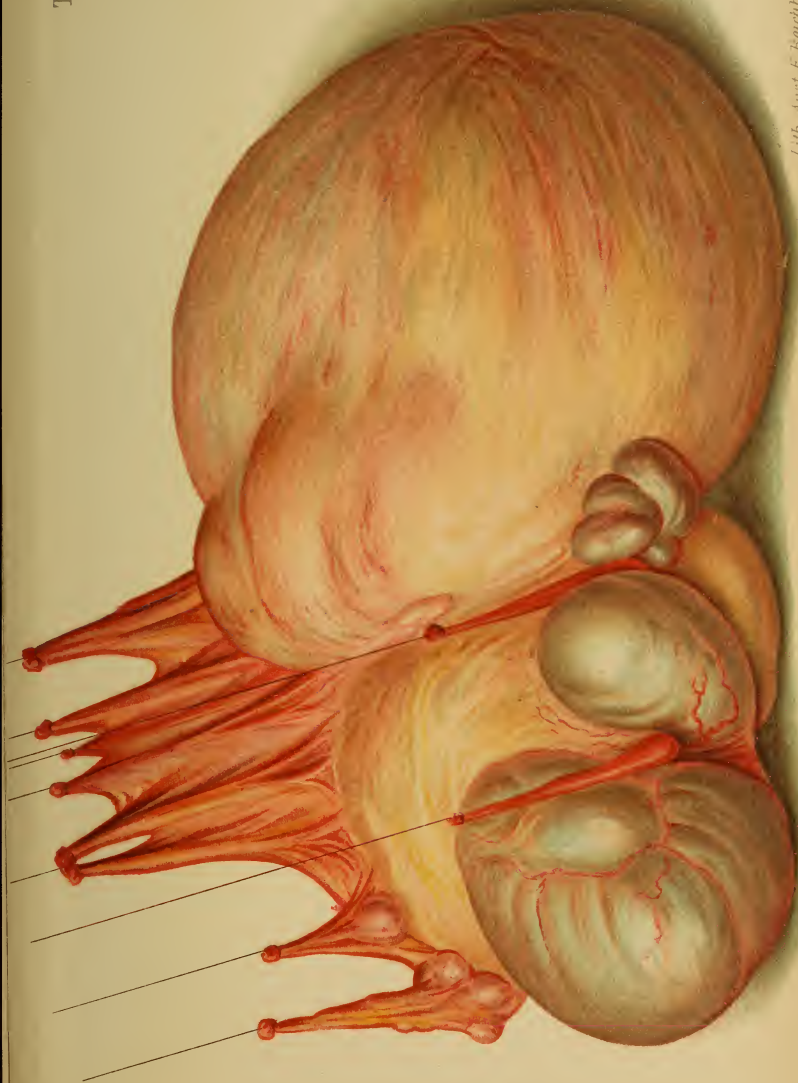**Multilocular Glandular Mucoid Cyst.** As a result of torsion of the pedicle, hemorrhages have occurred in individual cysts (dark-bluish color) and portions of the wall have become necrotic and adherent to the omentum. Subperitoneal disturbances of the circulation have formed cystic spaces (on the left) in the latter. (Original water-color from a case at the Heidelberg Frauenklinik.)


---

The tumors show a more or less rapid, progressive, and almost unlimited growth. They become dangerous when they grow larger than a man's head; their weight may exceed that of the patient herself. (Fig. 62.) When the tumor has involved the entire ovary, it is fixed to the uterus and nourished by a pedicle, which consists of the broad ligament, tube, and ovarian ligament. The pedicle is absent in intraligamentous tumors (Plate 59, 2) because the entire growth develops outside of the peritoneum in the subserous connective tissue of the broad ligament. The anterior surface of the ovary is embedded in the broad ligament (by the mesovarium), while the posterior surface, directed toward the pouch of Douglas, is uncovered. If an ovarian cyst develops from the anterior surface, it grows into the connective tissue between the two layers of the broad ligament—it is "intraligamentous"; if the tumor becomes larger, it strips up the posterior lamella, elevates the serosa of Douglas' pouch, and reaches the spinal column—it becomes "retroperitoneal."

The pedicle previously mentioned is pathognomonic of ovarian tumors, and may be demonstrated by the method illustrated in Plate 74. It is usually twisted in a spiral manner in the larger tumors. This torsion of the pedicle is due to intestinal peristalsis, to the variable emptying and filling of the abdominal organs, and to the movements of the body. In left-sided tumors the pedicle is more frequently twisted from 90 to 180 degrees to the right. If it is twisted more than 360 degrees, disturbances of the







circulation and extravasation occur in the tumor, and hematomata are formed in the pedicle; secondary disturbances of nutrition lead to retrograde metamorphoses; both results are serious in proportion to the rapidity of the compression (necrosis; rupture of the mucoid degenerated wall, Plate 72; decomposition; peritonitis). If colloid masses reach the peritoneal cavity, they become organized upon the serosa, constituting "peritoneal myx-edema" (pseudomyxoma peritonei, Werth).

The larger tumors always cause fibrinous deposits and adhesions, because the changed superficial epithelium becomes desquamated. In a beginning cystoma the fimbriated end of the tube sometimes becomes agglutinated; if the dividing wall disappears, a tubo-ovarian cyst results.

3. *Papillary proliferating cysts.* (See explanation to Fig. 61.)

4. *Racemose cysts* (Olshausen) differentiate themselves from the cystadenomata by the fact that several vesicles are attached to one pedicle; even if they have broad bases, they do not present a smooth globular surface, but look like a mass of small vesicles (resembling a hydatid mole). The vesicles contain a fluid that is not colloid; it is rich in albumin.

5. *Dermoid Cysts.* (Plates 45 and 79.)

Cystomata may lead to serious consequences:

1. From their increase in size—larger than a man's head.

2. From strangulation as a result of torsion of the pedicle, with hemorrhages, inflammation, suppuration, infection (they may, it is true, undergo absorption and natural cure), septicemia.

3. From intestinal adhesions and the subsequent production of intestinal obstruction.

4. From rupture of the tumor and consequent pseudomyxoma peritonei (Werth).

5. From carcinomatous degeneration.

6. Death from cardiac weakness, uremia.

**Symptoms.**—(See initial symptoms in § 32.) Pressure symptoms first occur when the tumor reaches the size of

## PLATE 70.

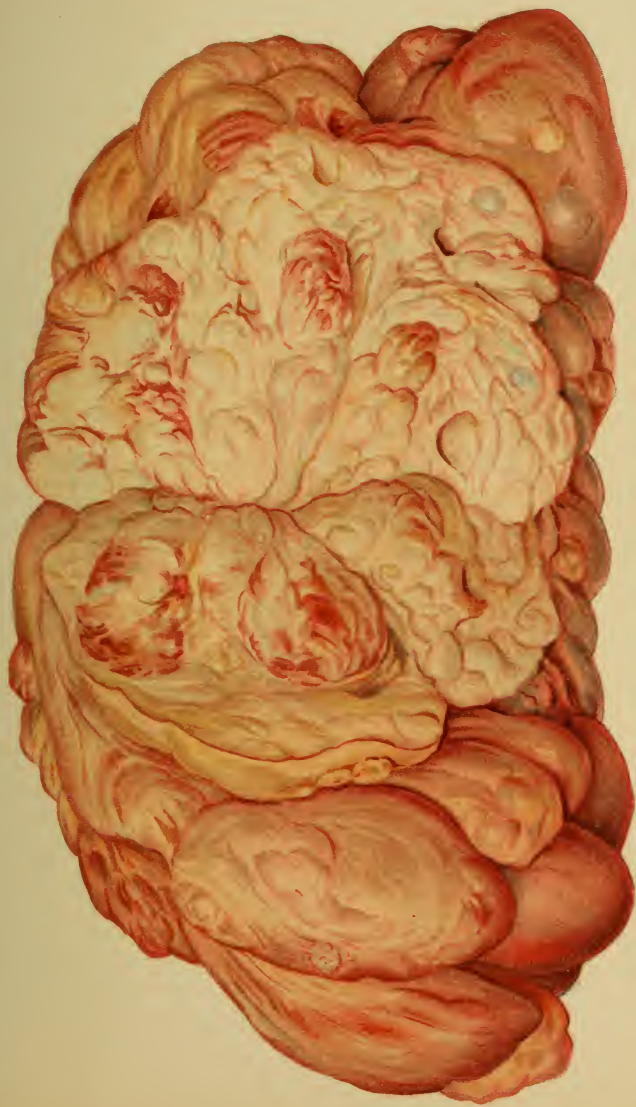**Multilocular Glandular Muroid Cyst.** The middle of the tumor is laid open by an incision. (Original water-color from an operative specimen from the Heidelberg Frauenklinik.)

## PLATE 71.

**FIG. 1.—Histologic Structure of a Uterine Mucous Polyp.** (Original drawing from a specimen from the Munich Frauenklinik.) Circumscribed proliferation of the uterine mucosa (proceeding from the body as well as from the cervix), consisting of glandular and connective tissue in their normal structure and relations (in contrast to the atypical proliferation of malignant adenoma, as seen in Plate 30, Fig. 2). The glandular spaces (1) are lined with ciliated columnar epithelium. Numerous thin-walled, dilated vessels (2 and 4) are seen in the connective tissue (3), and are responsible for the hemorrhage that is so easily produced.

**FIG. 2.—Microscopic Section through the Transition Zone of a Minute Myoma That is Becoming Encapsulated into the Surrounding Normal Uterine Muscularis.** (Original drawing from a specimen from the Munich Frauenklinik.) The tumor tissue to the left (1) consists of densely packed and interlaced non-striated muscle-fibers alone, without the admixture of connective-tissue fibers that occurs without exception in the large tumors (consequently called fibromyomata, which always originate in such pure intramural myomata). The border-line (2) of the normal muscular tissue consists of concentrically arranged parallel lamellæ, which are evidently compressed by the new growth. To the right, markedly dilated vessels (4) are seen in the muscularis (3), which shows a less parallel arrangement.

**FIG. 3.—Vaginitis (Colpitis).** (Original drawing from a specimen from the Munich Frauenklinik.) Round-cell infiltration of the submucous connective tissue, especially in the neighborhood of the numerous normal lymph-follicles (3—surrounded by round cells and lymph-channels). (1) Normal vaginal tissue; (2) normal connective tissue.







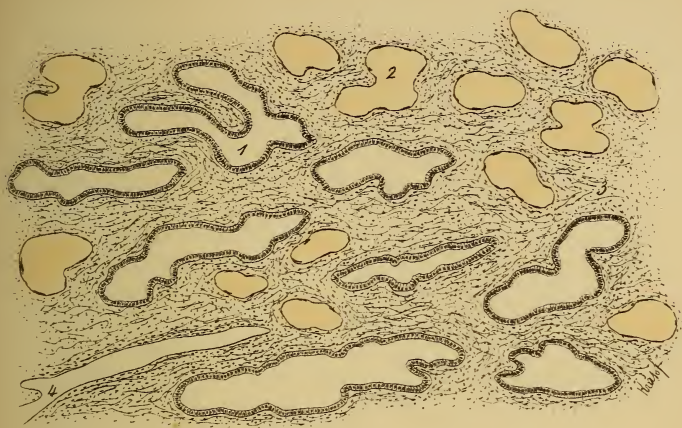


Fig. 1.

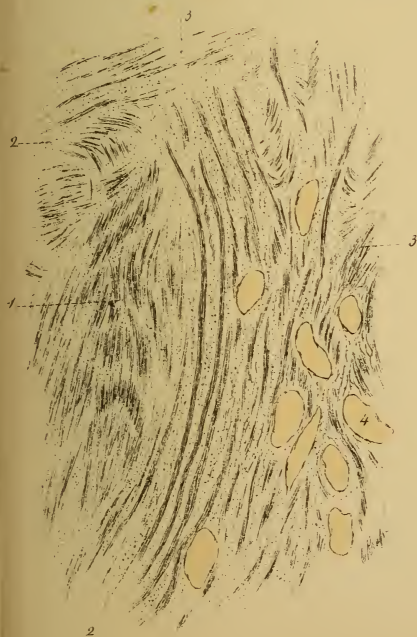

Fig. 2.

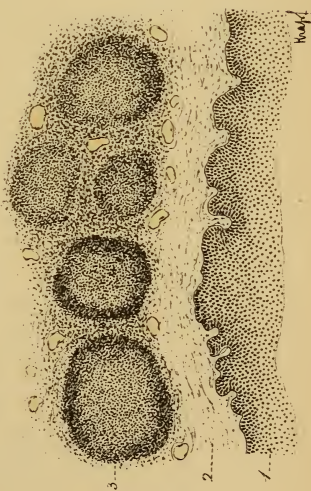


Fig. 3.



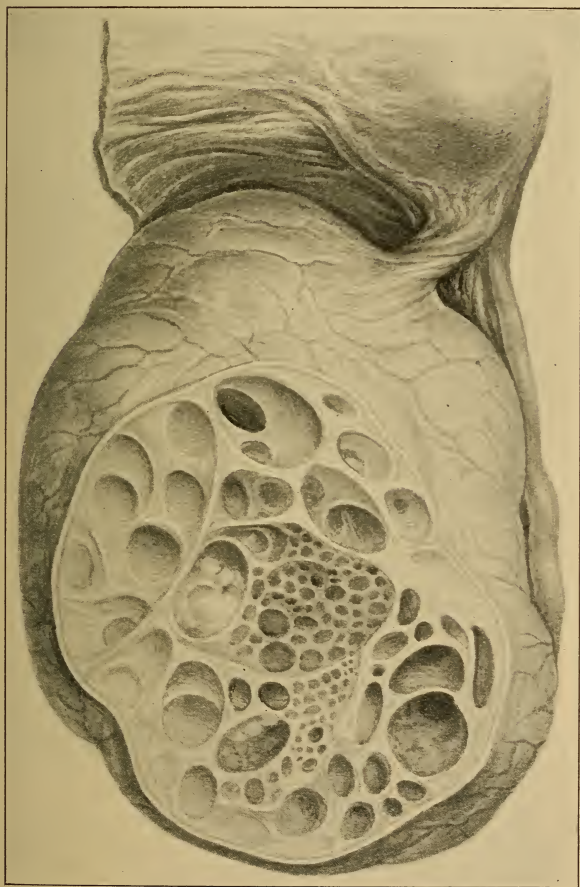


Fig. 60.—Multilocular glandular mucoid cyst of the ovary, with torsion of the pedicle. (Specimen at the Munich Frauenklinik.)

a child's head and remains wedged in the pelvic cavity (constipation, urinary disturbances, neuralgias). Intestinal perforation may occur. (See Plate 45, 2, representing a case treated in the dispensary at the Munich Frauenklinik.) Dyspnea, swelling of the thoracico-abdominal veins, edema, and pressure upon the ureters are observed. The patient is finally confined to bed.

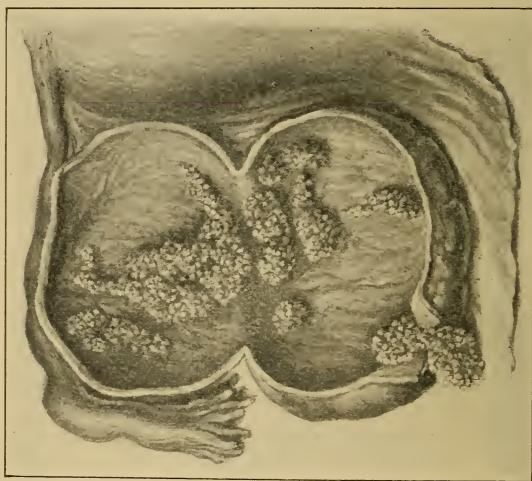

Fig. 61.—Papillary proliferating cyst (specimen from the Munich Frauenklinik), characterized by the fact that the epithelium produces not only glandular—*i. e.*, follicular and cystic—formations, but also conglomerations of papillary formations upon the walls of the cysts. (See also Plate 72, Figs. 1 and 2.) These dendritic proliferations are found either only upon the inner surface of the cysts, or also upon the outer surface; in the latter case they not rarely grow through the wall. They give metastasis to the serosa of the entire peritoneal cavity and produce ascites. Macroscopically, they are not to be differentiated from the similar, somewhat firmer, carcinomatous growths.

The **diagnosis** is made by the demonstration of a pedicle and the separation of the tumor from the uterus, the method of Schultze being employed. (Plate 74, Fig. 3.) Fluctuation is a further aid. In contrast to ascites, percussion demonstrates an area of dullness which



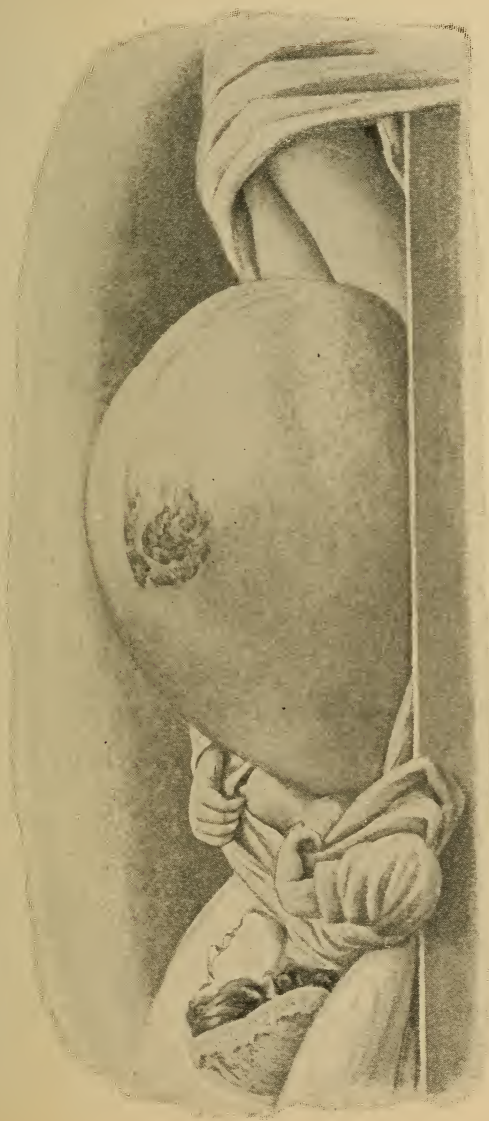


Fig. 62.—Enormous ovarian cyst (from a photograph kindly given to the author by his colleague, Dr. Cohnheim).

has an upper convex border; above and at the sides an intestinal tympanitic note may be obtained. Ascites may coexist. Vascular murmurs are much rarer than over myomata.

The uterus is usually found in front of and beneath the tumor (Plate 59); it is rarely retroverted (Plate 16, 4); if pregnancy occurs, total prolapse may take place. The uterus does not move with the tumor. The pedicle arises from one corner of the uterus (Plate 74, 3) and may be best palpated through the rectum. Dermoid cysts usually lie in front of the uterus in the vesico-uterine excavation.

The fluid obtained by tapping has the following characteristics:

(a) Microscopic. (See Plate 72, Fig. 5.)

(b) Chemic: Golden yellow to dark brown (blood) in color; specific gravity, from 1010 to 1024 (1005 to 1055); colloid from pseudomucin (metalbumin). The demonstration of the latter is important. The albuminous substances pass through a process analogous to digestion until they become soluble in water (the older the tumor, the more soluble the substance—Eichwald). The chemic differentiation of the mucous and albuminous substances found together in cystomata is as follows:

| <i>Mucous Series.</i>   | <i>Albuminous Series.</i>                                  | <i>Solubility.</i>  |
|---|--|---|
| 1. The substance of the colloid globules—transformed cellular parenchyma. | 1. { (a) Albumin.<br>(b) Albuminate of soda.               | 1. { Boiling +.<br>Acetic acid precipitates.  |
| 2. Mucin.   | 2. Paralbumin (propeptone).                                | 2. { Boiling +.<br>Acetic acid precipitates.  |
| 3. Colloid substance (soluble in water).                                  | 3. <i>Metalbumin</i> (pseudomucin) (not soluble in water). | 3. Alcohol precipitates, mineral acids do not.  |
| 4. Mucopeptone.   | 4. Albumin-peptone (fibrin-peptone).                       | 4. Precipitated by neutral metallic salts, potassium ferrocyanid, and tannin; soluble in water. |

The albuminous series is differentiated from the mucous series by the fact that the former contains nitrogen and sulphur and is precipitated by tannin and neutral metallic salts.

The fluid is boiled, and upon the addition of nitric acid all the albumins, as far as and including paralbumin, are precipitated. These, together with the corresponding mucins, are removed by filtration. Upon the addition of alcohol to the filtrate, the metalbumin is coagulated and sinks to the bottom in white clouds. If acetic acid alone is added to the filtrate, a cloudiness occurs, but no precipitation. Metalbumin is distinguished from the corresponding colloid substance by its insolubility in water, or by its being precipitated by a new test with ferrocyanid of potash.

The reduction test with 10% cupric sulphate solution (Trommer's sugar test) is employed for more exact examinations.

The chemic differential diagnosis between ascitic transudate and peritoneal exudate is given in the explanation of plate 58, 1.

*Parovarian Cysts*.—Contents clear as water; specific gravity from 1002 to 1006; rarely richer than this in albumin; ciliated epithelium without other formed elements, such as blood-corpuscles.

*Hydrosalpinx*.—Contents serous, mucoid, or gritty; rich in albumin; cholesterin, red and white blood-corpuscles, cylindric epithelium.

*Hydronephrosis*.—Much urea is present, demonstrable by partial evaporation, extraction with alcohol, and evaporation; the residue is dissolved in a small amount of water and treated with concentrated nitric acid. Rhomboid plates of urea nitrate are formed. Low specific gravity; little albumin.

*Echinococcus Cysts*.—(Occur in the genitalia in 4% of all cases, especially in the uterine submucosa and in Douglas' pouch.) Specific gravity from 1007 to 1015; hooklets and scolices; no albumin; much NaCl, and especially succinic acid. The latter is demonstrable by partial evaporation, dilution with water, and extraction with ether; upon evaporation the monoclinic prisms—six-sided plates of succinic acid—are obtained, or the watery solution gives a rust-colored flocculent precipitate with ferric chlorid.

### I. Intra=uterine Tumors.

**Differential Diagnosis.**—1. *Pregnancy*.—Absence of the menses, gradual typical increase in size, and, after the fifth month, fetal movements, ballotement, and audible cardiac sounds. The cervix is livid and soft. Characteristic softening of the lower uterine segment (bimanual through the rectum). The variable signs of pregnancy and secretion from the breasts are worthless, as they also occur with cystomata. The sound and the trocar are not to be used until pregnancy is absolutely excluded.

## PLATE 72.

**FIG. 1.—Primary Formation of Cysts from a Multilocular Glandular Mucoid Cyst of the Ovary.** (See also Plates 68–70 and Figs. 60, 62.) The individual cystic spaces (1) are formed because the walls tear, from mucoid degeneration (2, 3), and float about in the fluid colloid contents as free papillæ (2). (4) Smallest cyst. (5) Connective tissue. (Original drawing from a specimen.)

**FIG. 2.—Papillary Proliferating Cyst of the Ovary.** (Original drawing from a specimen from the Munich Frauenklinik.) (1) Broad papilla containing a cyst (2) lined, as is the entire cyst, with columnar epithelium (4), with pouchings similar to glands or folds (5); (3) cross-section of papillæ; (8) fine dendritic papillæ; (6) dense connective tissue of the cystic wall; (7) external wavy elastic layer of connective tissue.

**FIG. 3.—Necrotic Cyst-wall.** Myxomatous degeneration and separation of the connective-tissue fibers (2); vascular space (1). (Original drawing from a specimen.)

**FIG. 4.—Sediment from the Fluid of an Ovarian Cyst.** (1) Cholesterin crystals; (2) red blood-corpuscles; (3) granular columnar epithelium; (4) fatty granular cell; (5) leukocytes; (6) endothelium. (Original drawing.)

---

Retroflexion of a gravid uterus is to be especially considered. The chief symptom is ischuria.

It is to be further remembered that the product may have died (chilliness).

2. *Hematometra, with or without Hematosalpinx.*—If congenital, the menses have never appeared; if acquired, they have been absent since a definite time. The patulous condition of the vagina and uterus is to be demonstrated by the sound.

3. *Intramural and Submucous Myomata.*—Menorrhagia, labor-like pains, slower growth than in cystomata. They are dense, and vascular murmurs are usually present; the uterine cavity is elongated. They frequently coexist with cystomata.



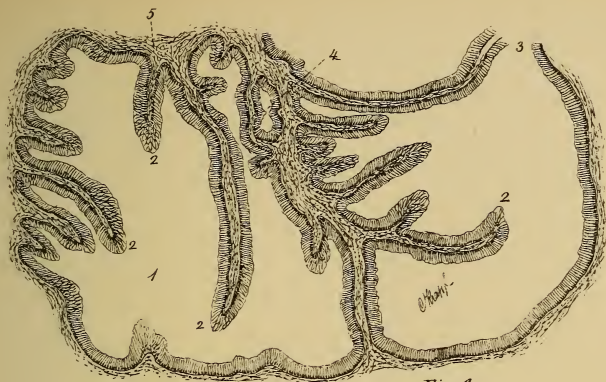

Fig. 1.

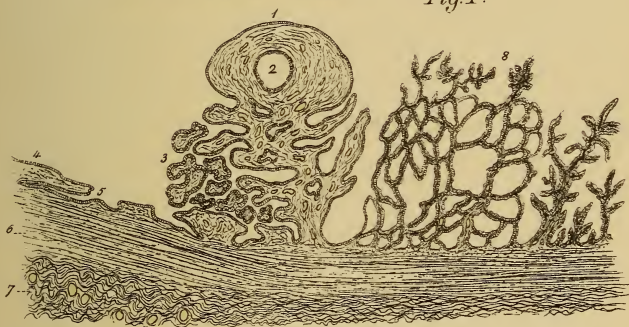


Fig. 2.




Fig. 3.

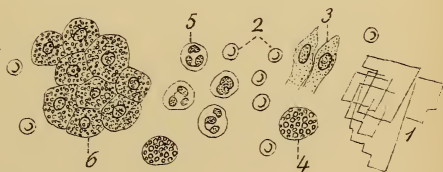

Fig. 4.





## II. Pedunculated Tumors of the Uterus and Adnexa.

4. *Subserous uterine myomata* present symptoms similar to those just mentioned, and, in addition, the cervix moves with the tumor, sometimes being forced in the opposite direction by leverage. With the exception of cystic fibromata and edematous tumors, their consistency is greater (cystomata may also become hard from extravasation of blood after torsion of the pedicle).

5. *Intraligamentous Uterine Myomata*.—Symptoms as in 3 and 4. They are intimately associated with the uterus, and are to be differentiated from intraligamentous cysts only by their hardness.

6. *Hydrosalpinx, Hematosalpinx, Pyosalpinx*.—Anamnesis, fever, tenderness and pain, lateral situation and sausage-shaped or horn-shaped, with constrictions. (Plates 41, 44, 59, 74.) Tapping.

7. *Parovarian Cysts*.—These are round; they show marked fluctuation, and are not nodular, but unilocular. They are close to the uterus and have, at most, an insignificant pedicle. Tapping.

8. *Ovarian Fibromata*.—These possess a uniform density, a surface covered with small protuberances, and are of slower growth.

## III. Tumors of the Pouch of Douglas.

9. *Abdominal Pregnancy*.—This is characterized by temporary amenorrhea and by pain, and occasionally the decidua is cast off. The sac has no pedicle, and portions of the fetus may be recognized.

10. *Intraperitoneal Retro-uterine Hematocele*.—Sudden origin, with collapse. The fluctuating tumor fills the recto-uterine pouch. The vaginal vault is tender. No diagnostic incision should be made. (Plate 58.)

The extraperitoneal peri-uterine hematocele (hematoma) leaves Douglas' pouch free and lies to the side of the uterus.

## PLATE 73.

FIG. 1.—**Myxosarcoma of the Uterus.** (Original drawing from a specimen from the Munich Frauenklinik.) It arises primarily or from an unusually rapidly growing fibroma (which has undergone degeneration from insufficient nutrition or from infection). (1) Malignant "giant cells." (2) Round-cell proliferation. (3 and 4) Myxomatous connective tissue; the fibers are pressed apart. (See also Plate 73, 2.)

FIG. 2.—**Spindle-cell Sarcoma of the Uterus.** With cyst formation (2); (1) giant cells abundantly present among the spindle cells. (Original drawing from a specimen from the Munich Frauenklinik.) (See also Plate 87, 2.)

By sarcomata we understand tumors of the connective-tissue type with an abnormal predominance of the cellular elements (round, spindle, giant, and stellate cells). They occur as soft, lobulated tumors, which grow rapidly, soon give rise to metastases, and recur upon removal. In contrast to epitheliomata, they arise more commonly in early life. They are found in the uropoietic apparatus, in the vulva, in the vagina, in the uterus, in the ovaries, and in the remaining adnexa.

They occur in the vulva as round-cell sarcomata, spindle-cell sarcomata, myxosarcomata, and melanosarcomata; in the vagina (Plate 73); in the uterus (Plate 87, Fig. 2); in the ovary they present a spindle-cell type, with or without cyst formation.

FIG. 3.—**Malignant Adenoma Growing through a Cyst-wall.** (Half diagrammatic original drawing from a specimen from the Munich Frauenklinik.) The superficial columnar epithelium (1) grows out into an atypically arranged adenomatous mass (6), consisting of cystic glandular spaces (7), with columnar epithelium (6), which is stratified in various places (8). The interstitial connective tissue (9) is scanty. The cyst-wall consists of columnar epithelium (1), dense fibrous connective tissue (2), wavy elastic connective tissue (3), with thin-walled vascular spaces (4), and the endothelium of the serosa (5).

FIG. 4.—**Angioma of the Urethra.** (Original drawing from a specimen.) The blood-capillaries (1) consist of endothelial cells alone, and lie close together in the connective tissue (2). (See also explanation to Plate 51, Fig. 2.)

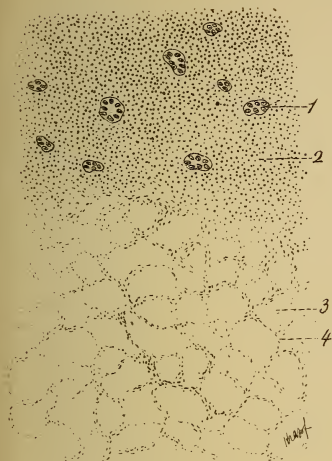


Fig. 1.

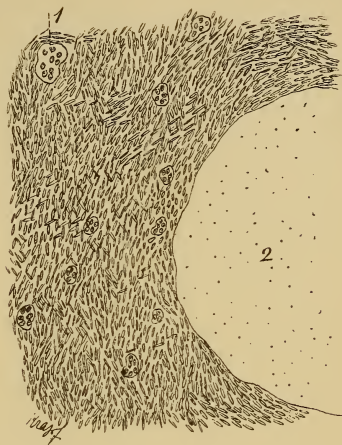

Fig. 2.

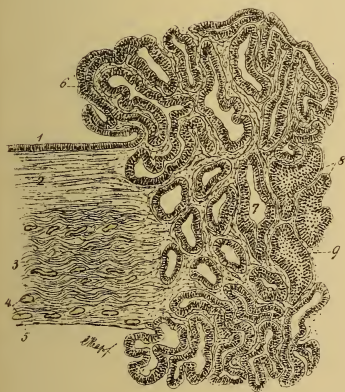


Fig. 3.

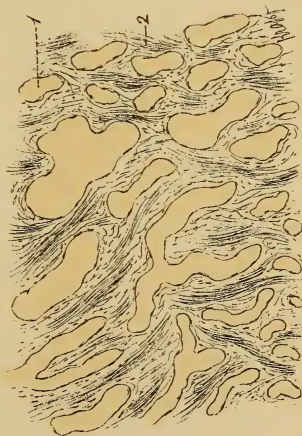



Fig. 4.





11. *Fluid Exudative Peritonitis*.—This pursues a febrile course, with violent pains, tympanites, and vomiting. Diarrhea is often present. The patient is unable to walk. The tumor is at first fluctuating or doughy; later, it is nodular and the uterus is immobile. (Plate 17, Fig. 1.)

12. *Parametritic tumors* present characteristics similar to the foregoing. They are to one side or posterior, and above the vaginal vault. Contracted intraligamentous abscesses are connected with the margin of the uterus. (Plate 59, 1.)

13. *Rectal tumors* are rarer, and are occasionally adherent to cystomata. They are to be palpated from the rectum as they are located in its wall. Stenosis is sometimes present. It is often impossible to establish the true condition of affairs; a cyst may be adherent to the intestine.

14. *Tumors of the pelvic bones* are immovably connected with them, and grow more slowly. It is very important that the ovaries should be located, since cysts adherent to the pelvis may closely simulate them upon palpation.

15. *Anterior sacral hydromeningocele* (a hydromeningocele of the dura mater between the body and ala of the sacrum) is a great rarity.

#### IV. Other Abdominal Tumors.

16. *Floating Kidney*.—The movable tumor is reniform, firm, and somewhat sensitive. The normal renal dullness is absent, and in its place a tympanitic percussion-note may be obtained. A pelvic pedicle is wanting.

17. *Hydronephrosis*.—This will have existed for a long time, and grows downward from the lumbar region without a pelvic pedicle. The intestines are in front of the tumor, whereas in ovarian growths they are either behind or above. Tapping.

18. *Renal tumors; Hematomata* (Plate 77).—Echinococcus cysts of the kidneys, of the liver, and of the pelvis give a hydatid thrill. Tapping.

19. *Splenic Tumor*.—This extends to the pelvis from

# Differential Diagnosis of the Ante-uterine and Retro-uterine Tumors.

## A. FLUCTUATING RETRO-UTERINE TUMORS.

*Slow Growth without Fever.*

Fundus uteri:

Continuous with the retro-uterine tumor.

- (1) Retroflexion of a gravid uterus; (2) intra-uterine cystic myomata; (3) hematomata; (4) echinococcus cysts of the uterus (submucous).

Distinct from the retro-uterine tumor.

- (1) Ovarian or parovarian cysts; (2) hydrosalpinx; (3) abdominal pregnancy (variable); (4) echinococcus cysts of the uterine adnexa and of the pelvis.

*Rapid Growth with Fever.*

Fundus uteri:

Continuous with the retro-uterine tumor.

- (1) Fluid peritoneal exudate; (2) intra-peritoneal retro-uterine hematocele; (3) parametric exudates and extraperitoneal peri-uterine hematocele (Douglas' pouch free).

## B. SOLID RETRO-UTERINE TUMORS.

Fundus uteri:

Continuous with the pelvic tumor.

- (1) Intra-uterine, intraligamentous, and broad-based subserous fibromyomata of the uterus, (Both with a febrile origin.)
- (2) Consolidated parametric exudates, (Douglas' pouch free).
- (3) Consolidated parametric exudates (Douglas' pouch free).

Distinct from the pelvic tumor.

- (1) Subserous polypoid fibromyomata of the uterus.
- (2) Ovarian fibromata and carcino-mata.
- (3) Pelvic tumors.
- (4) Rectal carcinoma.

## C. FLUCTUATING ANTE-UTERINE TUMORS.

*Slow Growth without Fever.*

Continuous with the tumor.

(1) Physiologic ante-  
flexion of  
a gravid  
uterus.(2) Intra-  
uterine  
cystic myo-  
mata.(3) Hema-  
tometra.(1) Ovarian  
dermoid  
cysts (usu-  
ally here;  
multilocu-  
lar ovarian  
cysts rarely  
here).(2) Hydrosal-  
pinx (more  
frequent  
here).(3) Abdomi-  
nal preg-  
nancy (rare-  
ly here).(1) Fluid per-  
itoneal ex-  
udate (rare).(2) Ante-uter-  
ine intra-  
peritoneal  
hematocoele  
(rarely  
here).(3) Anterior  
parame-  
tritic exu-  
dates and  
extraperi-  
toneal peri-  
uterine  
hematocoele  
(peritoneal  
pouch is  
free).*Rapid Growth with Fever.*

Distinct from the tumor.

## D. SOLID ANTE-UTERINE TUMORS.

Fundus uteri:

Continuous with the tumor.

(1) Intra-uterine  
and (rarely here)  
broad-based sub-  
serous fibromy-  
omata of the  
uterus.(2) Consolidated  
peritoneal ex-  
udate (rarely  
here).  
(Both with a febrile origin.)(1) Subserous poly-  
poid fibromyo-  
mata of the uterus.(2) Ovarian fibro-  
mata and carcino-  
mata (rarely here).(3) Vesical  
tumors.(4) Vesical  
calculi.(5) Anterior  
pelvic tu-  
mors.

Distinct from the tumor.

## PLATE 74.

FIGS. 1 and 2.—**Bimanual Examination of a Pyosalpinx with a Full and with an Empty Rectum.** Both bladder and rectum are to be emptied before every bimanual examination, as these illustrations show how easily deceptive ideas of the form and of the size of tumors may be obtained. *Py*, Pyosalpinx; *R*, rectum; *U*, uterus.

FIG. 3.—**Bimanual Examination, with Assistance, of the Pedicle of an Ovarian Cyst** (according to B. S. Schultze). (Original diagrammatic drawing.) The uterus is drawn downward with the bullet-forceps; the cyst is elevated through the abdominal wall; palpation is made from below through the rectum. In this way the pedicle is made as tense as possible. In the illustration the latter is twisted.

---

the left side of the abdomen, but has no pelvic pedicle. Leukemia.

20. *Tumors of the omentum, subperitoneal hematomata* (Plate 78), and *tubercular and carcinomatous adhesions* have no pedicle extending into the pelvis. Ascites or a tympanitic note may be demonstrated beneath them. The ovaries are normal.

21. *Cysts of the pancreas* have no pelvic pedicle.

22. *Tumors of the bladder* produce characteristic vesical disturbances. The urine should be examined for portions of tumor tissue. Dilatation of the urethra. They may be adherent to cystomata.

23. *Tumors of the abdominal walls and parietal peritoneum* are intimately adherent to the skin, and their outlines are strikingly distinct to palpation. During respiration they move backward and forward with the abdominal wall; intraperitoneal tumors move up and down with the diaphragm and disappear with increased tension of the abdominal muscles. In all positions of the body the tumor holds the same relation to the abdominal parietes. If the tumor is flattened by the contraction of the abdominal muscles, and can be felt immediately underneath their

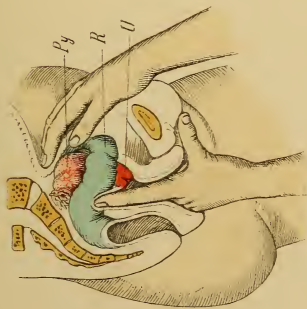


Fig. 1.

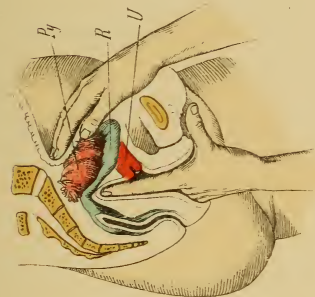


Fig. 2.

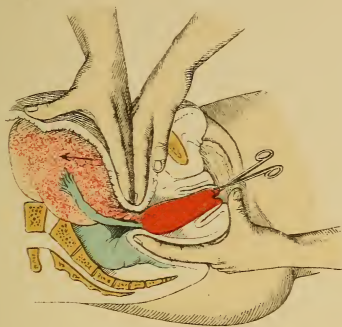


Fig. 3.





tense fibers, it springs from the serosa or from the transverse fascia; if the tumor becomes more prominent and fixed by the abdominal tension, it springs from the muscles themselves; if the tumor remains movable, it is situated in the subcutaneous connective tissue.

A fluctuating tumor in the lower abdomen may be a perimetritic or a parametritic abscess, or, if tubercular lumbar scoliosis is present, a psoas abscess; if the tumor is right-sided, appendicitis, typhlitis, perityphlitis, and an adherent pus tube in the vesico-uterine pouch must be considered.

#### V. Conditions Simulating Tumors.

24. *Distended Bladder.*

25. *Ascites.* (See Plate 58, 1.)

26. *Increased Amount of Fat in the Abdominal Wall.*

27. *Meteorism.*—General tympany is present; the genitalia are normal; localized hardness is absent; so-called "phantom tumors" are to be observed.

**Prognosis.**—Ninety per cent. of all cysts larger than a man's head are fatal from rupture and peritonitis, from suppuration, or from exhaustion. Malignant degeneration is always possible. Dermoid cysts suppurate easily or undergo carcinomatous degeneration.

Torsion of the pedicle is dangerous. It produces disturbances of the circulation with venous thrombosis, extravasation of blood, or rupture of the tumor. If the nutritional disturbance is gradual, retrograde metamorphoses occur; if it is rapid, necrosis (Plates 69 and 72) and gangrene follow.

**Diagnosis of Sudden Torsion of the Pedicle.**—Acute increase of pain; the tumor, often the abdomen also, becomes tender, causing the patient to bend forward in walking; reflex nausea; moderate evening rises of temperature, with morning remissions.

**Treatment.**—(See § 32.) If a cyst is as large as a child's head, it must be removed; pregnancy is no longer

## PLATE 75.

FIGS. 1 and 2.—**Two Different Cut Surfaces of a Sarcoma of the Ovary.** (Original water-color from an operative specimen from the Heidelberg surgical clinic.)

---

considered to be a contraindication to the operation. It is also best, however, to remove smaller cysts by ovariectomy, especially if they produce violent pressure phenomena, severe nervous symptoms, or render the individual unable to work. Since the other ovary likewise may easily undergo carcinomatous degeneration, the age of the patient, the family history, and the marriage relation must be carefully considered in every case, in order to determine whether the immediate removal of this organ is not also advisable.

Tapping should be resorted to only when special indications are present. These are as follows: When the operation is refused; during delivery; when marked dyspnea or other pressure symptoms are present and ovariectomy is contraindicated by malignancy, weak heart with edema, etc., profound anemia, pulmonary tuberculosis, nephritis, or other severe incurable constitutional diseases.

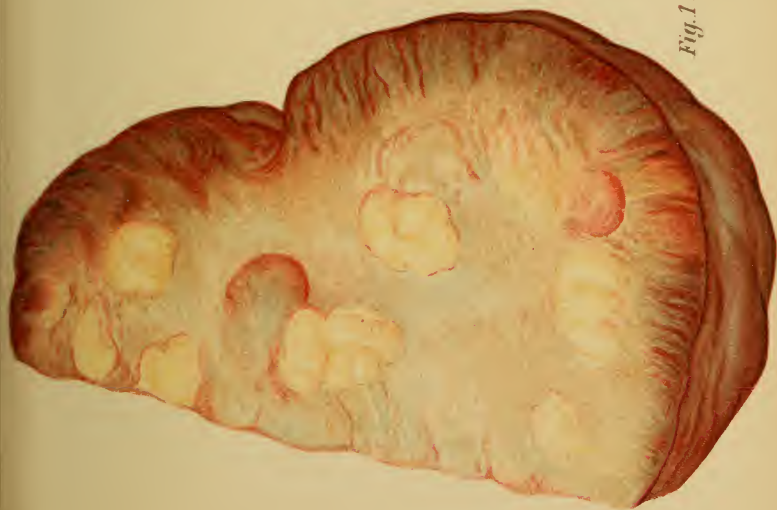
The cyst is to be tapped through the abdominal walls or the vagina by Bresgen's trocar or Potain's apparatus, the most rigid asepsis being observed and the entrance of air being carefully guarded against.

---

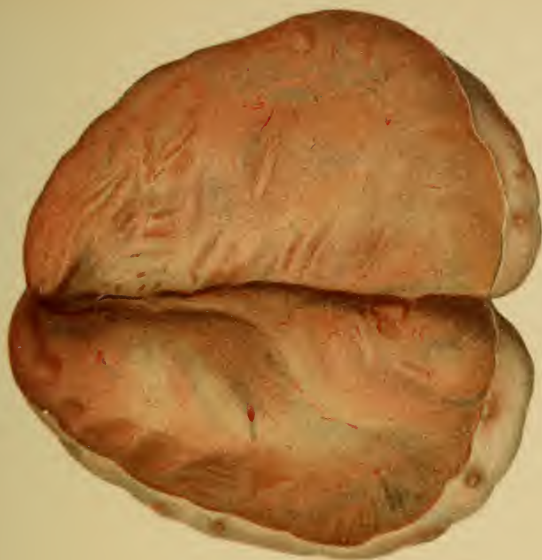## PLATE 76.

FIG. 1.—**Sarcoma of the Ovary.** (Original water-color from an operative specimen from the Heidelberg surgical clinic.)

FIG. 2.—**A Case of Commencing Sarcomatous Degeneration of the Ovary.** The albuginea is thickened, and small follicular cysts may be seen through the otherwise atrophic germinal layer. (Original water-color from an operative specimen from the Heidelberg surgical clinic.)



*Fig. 1.*

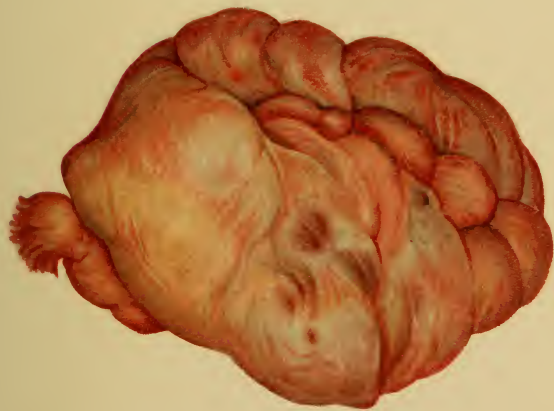

*Fig. 2.*

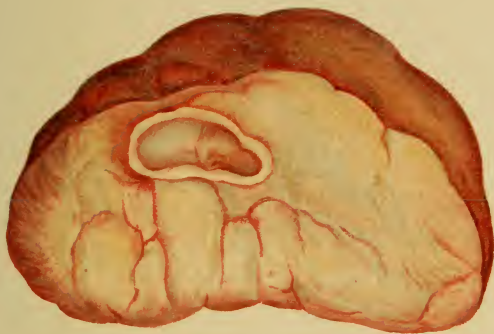*Lith. Anst. F. Reichhold, München.*







*Fig. 1.*



*Fig. 2.*



The trocar and elastic tube are to be previously filled with sterile water, and the free end of the tube is to be immersed in a receptacle containing the same fluid. This prevents the air from being sucked in by an accidental falling-back of the tumor; this accident is further hindered by sewing the cyst to the abdominal wall, which also renders impossible the escape of the fluid into the abdominal cavity. The cyst is to be evacuated by placing the patient in an appropriate position and not by manual pressure. The fluid is to be slowly drawn off, since a rapid removal is frequently followed by collapse. The puncture is to be closed by adhesive plaster (in the shape of a Maltese cross) or by an occlusive dressing.

Ovarian cysts rarely contract after tapping; they usually refill, and the patient becomes profoundly exhausted. Extirpation by modern aseptic methods has a mortality of only  $4\frac{1}{2}\%$  (Fritsch). At the Heidelberg Frauenklinik, in 1896, there was only one fatal result in sixty celiotomies (severe anemia and multiple myomata); there was not a fatal case from ovariectomy.

It is not within the scope of this book to go into the details of the technic of ovariectomy, but the preparation of the patient and the after-treatment, with its complications, will now be considered. The day before the operation the patient receives a full bath; the abdominal walls are shaved, scrubbed, and disinfected (soap and brush, alcohol and brush, sublimate solution and brush). During the night a sublimate compress is applied to the lower abdomen (Fritsch). Since infectious germs always exist in the cutaneous glands and in the deeper layers of the epidermis, the disinfection must be repeated immediately before the operation, special attention being given to the navel, old scars, or other uneven places in the skin.

For several days preceding the operation the diet should be liquid but nutritious (bouillon, eggs, milk, oatmeal-water). The bowels must be thoroughly and energetically evacuated, care being taken, however, that this is not carried to excess. Immediately before the operation the bladder is to be emptied; the vulva and vagina are to be thoroughly cleansed and tightly packed with iodoform gauze in case it is necessary to open the vaginal vault or to perform other operations through the vagina.

**Dressing and After-treatment.**—Dermatol is to be

## PLATES 77 AND 78.

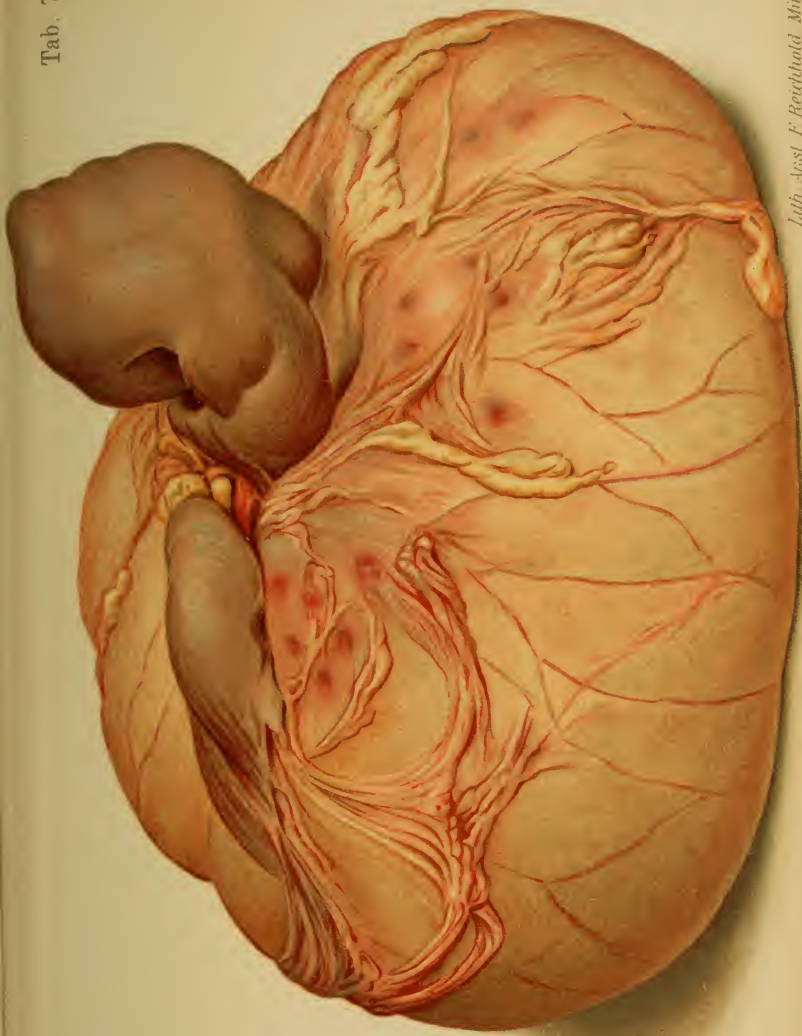
**Multiple Extraperitoneal Extravasations of Blood, Especially in the Great Omentum.** The largest one was connected with the atrophic kidney by numerous peritoneal adhesions, and simulated a renal tumor. (Plate 77.) The different stages of development are shown in plate 78 in their natural size. Figures 1 and 2, primary extraperitoneal hemorrhages; as the hemorrhage increases a peritoneal pedicle is formed (Fig. 3); the greater portion of the wall is now insufficiently nourished, and undergoes necrosis; the capillary vessels are seen radiating from the pedicle into the tumor; complete necrosis occurs upon torsion of the pedicle. (Fig. 4.) A cross-section shows the bloody contents and the thickening of the wall. (Fig. 5.) (Original water-color from specimens in the Heidelberg Path. Inst.)

dusted upon the line of incision; this is to be followed by iodoform gauze or iodoform collodion, cotton, and an abdominal binder. This dressing is not to be changed for several days unless it is absolutely necessary. The sutures are to be removed on the tenth day; if vaginal sutures suppurate, they are to be removed earlier, and a compress saturated with a solution of aluminum acetate <sup>1</sup> is to be applied.

Immediately after the operation free diaphoresis is to be encouraged (the bed is to be previously warmed), partly to hasten reaction, partly to prevent abdominal transudation, which furnishes a culture-medium for any micro-organisms which may have accidentally gained access to the peritoneal cavity (Fritsch).

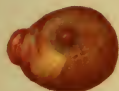*First day:* Allow the patient very little fluid in the form of restorative drinks: cold tea especially; small quantities of wine, cognac, or rum and water are exceptionally allowable; bouillon, coffee perhaps, and cracked ice and rectal injections of normal saline solution for the thirst. The patient must be kept warm. If reaction is tardy, rectal injections of alcohol, wine, or ether may be given in

<sup>1</sup> See Therapeutic Table.

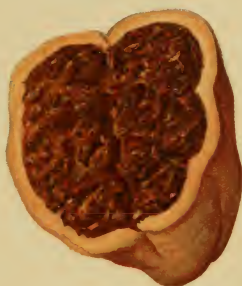




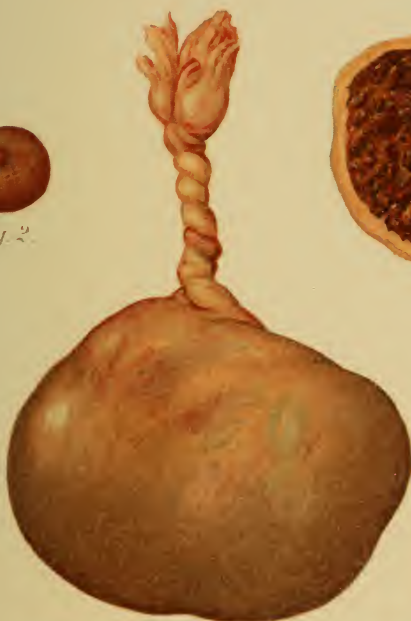


*Fig. 2.*



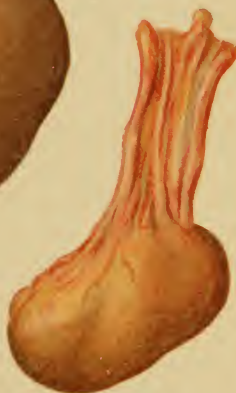*Fig. 5.*



*Fig. 4.*



*Fig. 1.*



*Fig. 3.*



addition to the foregoing remedies. If signs of internal hemorrhage present themselves, the wound is to be reopened.

*First week:* Liquid nutritious diet. An enema of infusion of senna <sup>1</sup> is given on the second day to guard against the formation of intestinal adhesions (Kehrer).

From then on two enemata are to be given daily, especially if abdominal pain is present. Mild cathartics may also be employed. If the urine is not passed spontaneously, the patient is to be carefully catheterized twice daily. Dorsal position; the lateral position (caution!) is to be allowed only with threatened hypostasis of the lungs. Vomiting may occur from swallowed chloroform (cracked ice and iced champagne), meteorism, constipation, or peritonitis. The bed is not to be changed until the beginning of the—

*Second week:* Easily digested solids; if the condition of the patient is absolutely good, veal, chicken, Zwieback, toast, wheat-bread, etc., may be allowed after the fourth or fifth day.

The patient may get up in the third week.

For meteorism: warm fomentations, oil of peppermint, fennel tea, high introduction of the rectal tube; if combined with marked vomiting, increased temperature, tenderness, and peritoneal exudate (peritonitis), inunctions of blue ointment, and administration of calomel. (See p. 123; § 15.)

If very severe sudden collapse with anemia occurs (internal hemorrhage), the wound should be immediately reopened. Severe sudden collapse with dyspnea and cyanosis (especially in fibromyomata) indicates pulmonary embolism.

<sup>1</sup> The author is in a position to compare the routine treatments of two clinics for many years. In the one, the opium treatment, placing the intestines at rest, was employed; in the other, the enemata of senna infusion were adopted. The latter treatment is, in his opinion, undoubtedly the better, especially as the subjective condition of the patient more nearly approaches the normal.

## PLATE 79.

FIG. 1.—**Epithelioma of the Vulva.** (Original drawing from a specimen from the Munich Frauenklinik.) (Compare with Plate 80, Fig. 2.) The epithelioma originates in the squamous epithelium (4). Numerous plugs of cells (5) are seen dipping down from the surface (4) into the stroma (3) and forming “cell nests,” which are surrounded by connective tissue richly infiltrated with round cells. The capillaries are dilated. At the edge of the stroma epitheliomatous “pearls” are formed from the cuboid cells of the matrix (1) and from the polygonal epithelium which proliferates centrally from them. A giant cell is seen among these cells at (2).

FIG. 2.—**Part of an Epitheliomatous Papilloma of the Vaginal Cervix.** (Original drawing from a specimen from the Munich Frauenklinik.) 1, Epitheliomatous papilla: the central connective tissue is infiltrated with round cells and contains thick-walled vessels; the squamous epithelial cells are seen at the periphery. 2, Connective tissue infiltrated with nests of cancer cells. 3, Extravasated blood.

FIG. 3.—**Epitheliomatous “Pearls” from an Ulcer of the Cervix.** The structure is the same as in figure 1. 1, Cuboid cells of the matrix; 2, polygonal cancer epithelium; 3, connective tissue infiltrated with round cells and traversed by dilated vessels; 4, lymph capillaries. (Original drawing from a specimen from the Munich Frauenklinik.)

FIG. 4.—**Dermoid Cyst.** (See Plate 45, Fig. 2.) (Original drawing from a specimen from the Munich Frauenklinik.) 1, Superficial squamous epithelium with connective-tissue papillæ; 2, low epithelium resting upon an even stroma; 3, hair, with sebaceous gland consisting of cuboid epithelium; 4, cross-section of a hair; 5, muscle-fiber; 6, connective tissue.

Dermoid cysts generally originate in the ovary (very rarely also in the vulva). They develop from the same tissue elements as do the cystomata, only with this difference: they assume a cutaneous character and are made up of all portions of the skin, from the epidermis to the subcutaneous connective tissue. There is scarcely a tissue or an organ in the body, be it ever so complicated, which may not also occasionally appear in these tumors (maxillary bones with teeth,



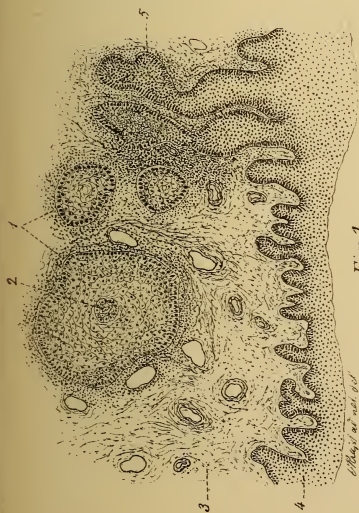


Fig. 1.

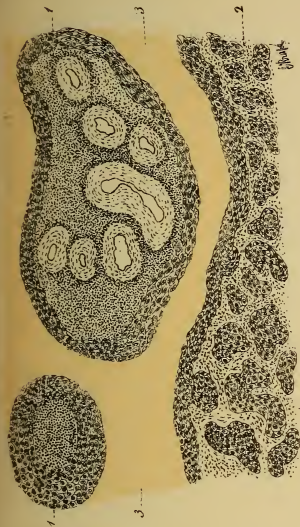


Fig. 2.

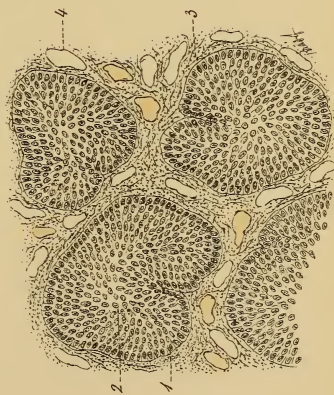

Fig. 3.

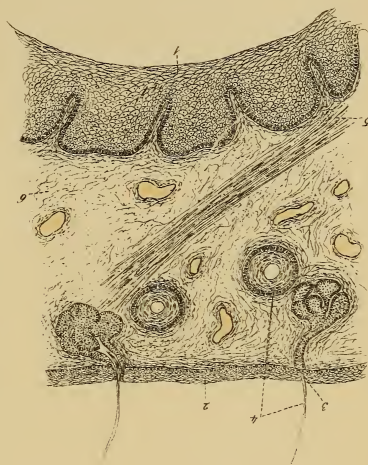

Fig. 4. Lith. Anst. F. Reichhold, München.



brain-substance, eye, etc.). The cysts are filled with sebaceous matter and blond hair.

These dermoid growths may coexist with ovarian cysts; they may also undergo carcinomatous degeneration. With these exceptions they are always unilocular; they have thick walls and vary in size from that of a man's fist to tumors the size of a man's head.

Their etiology is uncertain; they may be due to "intrafetation," from fission and displacement of the fetal rudiments.

---

As the peritonitis subsides the exudate undergoes absorption, organization, and encapsulation. (For the treatment see § 18.)

## CHAPTER III.

### MALIGNANT TUMORS.

The malignant tumors consist of epitheliomata (squamous epithelial tumors), malignant adenomata (glandular cancers), malignant papillary cysts of the ovary (papillary glandular proliferations), sarcomata (round-cell and spindle-cell proliferations, with or without mucoid degeneration or deposits of pigment in the intercellular tissue), and endotheliomata (proliferations of the endothelium of the vessels, or angiosarcomata, since they are a connecting link between epitheliomata and the connective-tissue tumors).

#### § 36. MALIGNANT TUMORS OF THE VULVA, BLADDER, AND VAGINA.

These occur:

*On the Vulva.*—(1) Epithelioma (Plates 80, Fig. 1; 79, Fig. 1); (2) fibrous carcinoma (rare); (3) malignant adenoma of the glands of Bartholin; (4) sarcoma (see explanation of Plate 73, Fig. 3).

*In the Urethra.*—(5) Epithelioma (very rarely primary).

*In the Bladder.*—(6) Villous cancer (Plate 88, Fig. 5); (7) diffuse scirrhus of the entire wall; (8) multiple nodular carcinoma; (9) sarcoma (very rarely primary).

*In the Vagina.*—(10) Papillary epithelioma (Plates 79, Fig. 2; 80, Fig. 2; 88); (11) flat diffuse carcinomatous infiltration (Plates 80, Fig. 2; 88); (12) sarcoma (Plate 73, Figs. 2 and 3; rare).

**Symptoms and Diagnosis.**—*Epithelioma of the vulva:* pruritus often exists long before the small, flat, reddened nodules make the skin uneven. Later the edges are livid and dense; small nodules are observed in the surrounding skin. Disintegration soon occurs and there is early metastasis to the inguinal glands. The ulcer has irregular

edges with hard surroundings. The patient is usually over forty years of age.

*Sarcoma of the vulva* occurs in younger patients, and may be congenital; the tumor has a fibrous structure. For the anatomy of sarcoma see explanation of Plate 73, figure 2.

*Cancer of the bladder*: symptoms as in § 31 under Bladder. Urethral dilatation is necessary. The tumor consists of soft, crumbling, polypoid masses, which are readily torn away from the tumor; these do not consist of intact villi, as in a fibrous tumor, but of disintegrated shreds of tissue (microscope). These tumors are usually secondary; metastasis occurs early; embolism is frequent; peritoneal symptoms are observed.

*Epithelioma of the vagina*: pruritus is also observed here; irregular hemorrhages. Pain, both during coitus and spontaneous. If ulcerated, purulent and offensive discharges and casting-off of fetid, crumbling pieces of tissue. Vesical disturbances gradually appear, and finally fistulous tracts are formed. (See Plate 79.) When a vaginal epithelioma is diagnosed, it must be determined whether it is not a secondary growth from the cervix. (Plate 88.) Papillary epithelioma usually begins anteriorly with a broad base (chronic vaginitis). The nodular form is usually peri-urethral; the nodules quickly coalesce and soon ulcerate.

Sarcoma causes analogous disturbances. (See Plate 73.) Death follows from venous metastases, septicemia, or hemorrhage. Recurrent fibromata or polyps are to be looked upon with suspicion.

**Treatment.**—All these tumors must be removed as soon as they are diagnosed. This is accomplished with the knife and the Paquelin cautery; the limits of the extirpation must lie outside of the infiltrated zone. Glandular metastases are not to be neglected. As a prophylactic measure at the time of the menopause, every suspicious large or weeping warty prominence on the vulva should be



## PLATE 80.

**FIG. 1.—Ulcerated Epithelioma of the Left <sup>1</sup> Labium Majus.** (Original water-color.) This tumor at first consists of slightly reddened individual flat prominences and nodules. The edge of the tumor is very dense and is of a bluish color; the central portion soon becomes disintegrated. The tumor creeps along slowly, giving early metastases to the inguinal glands. The vagina is usually spared. Histologically, the tumor consists of squamous epithelium (Plate 79, Fig. 1); it is very rarely a fibrous carcinoma.

**FIG. 2.—Flat Ulcerating Epithelioma of the Posterior Lip of the Os Uteri and of the Posterior Vaginal Vault.** (Original water-color.) This tumor has grown from epitheliomatous nodules. (See Plate 88, Fig. 1.)

---

removed. It is not right first to subject them to prolonged cauterizations.

Urethral carcinoma does not lead to incontinence as long as the sphincter remains intact. If the case is inoperable, the decomposing urine is to be drawn off as quickly as possible and the interior of the bladder disinfected.

In cancer of the bladder (Plate 88, Fig. 5), if it is a circumscribed villous tumor, the affected portion of the vesical wall is to be removed; if it is diffuse, flat, and consists of nodular formations, excochleation with the sharp curet. Irrigation with solutions of salicylic acid or silver nitrate; if hemorrhage occurs, ice-water irrigations, ice-bag, and vaginal tamponade. On the following day the coagula are to be removed through a large catheter.

---

## PLATE 81

**FIG. 1.—Nodular Epithelioma of the Vaginal Cervix.** (Original water-color.)

**FIG. 2.—Epitheliomatous Papilloma of the Anterior Lip of the Os Uteri.** (View of the cervical canal.) (Original water-color.)

<sup>1</sup> TRANSLATOR'S NOTE.—The original reads "right."

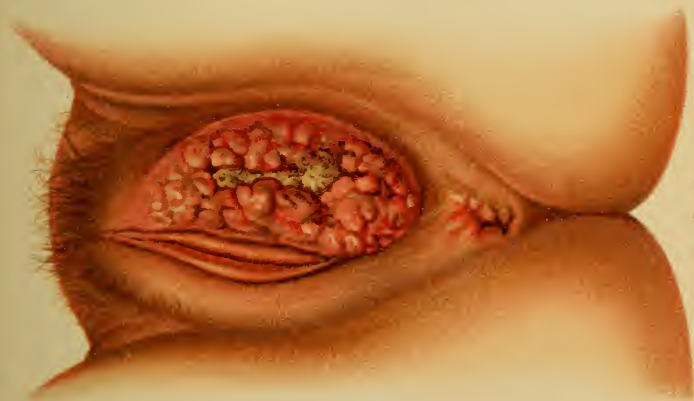

Fig. 1.

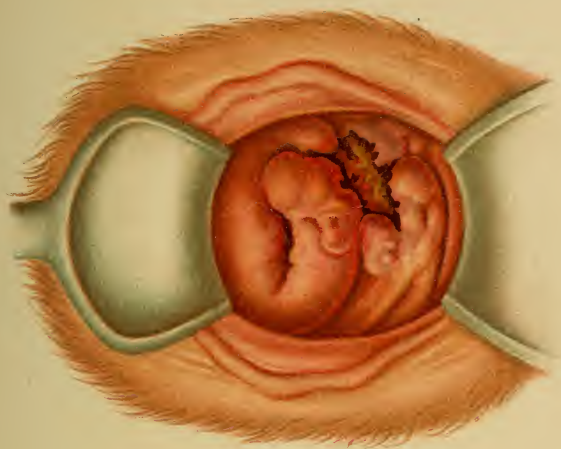


Fig. 2.



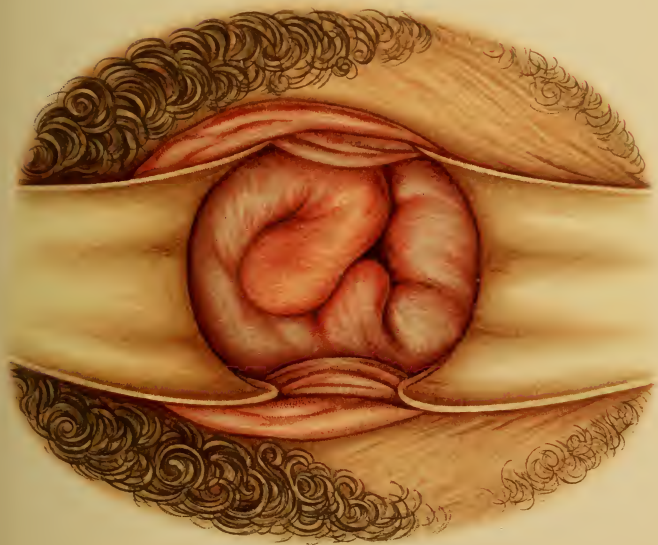


Fig 1.

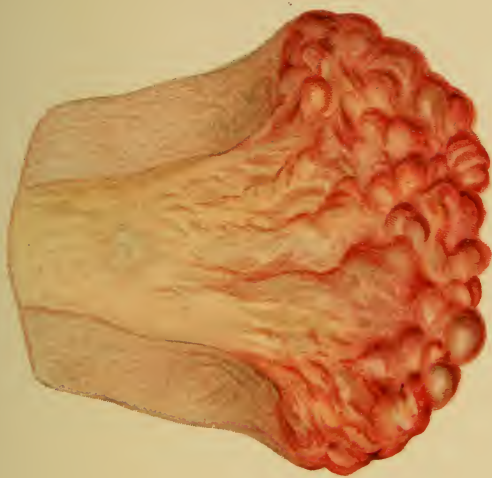


Fig. 2.





## § 37. MALIGNANT TUMORS OF THE UTERUS.

### I. Carcinoma of the Uterus.

The individual varieties of uterine cancer are :

1. Epitheliomatous papilloma of the vaginal cervix. (Plates 79, Fig. 2; 81; 84, Figs. 1 and 2 (beginning); 85, 1; 88, 1-4; 90, 2.)
2. Flat epithelioma of the cervix and of the vaginal vault. (Plate 80, Fig. 2.)
3. Epitheliomatous ulcer of the cervix. (Plates 79, Fig. 3; 82; 83; 85, Fig. 2; 86; 89.)
4. Nodular epithelioma of the cervix. (Plates 80, Fig. 2; 83.)
5. Superficial epithelioma of the body of the uterus. (Plate 89, Figs. 3 and 4.)
6. Glandular cancer, malignant adenoma of the body of the uterus. (Plates 30, Fig. 3; 87, Fig. 1.)

**Symptoms.**—It is of the utmost importance to diagnose these malignant tumors as early as possible, because it is only in the beginning, before metastases have occurred, that the opportunity exists for a thorough removal without recurrence.

The initial symptoms in nearly every case are hemorrhages, discharge (first mucoid, then purulent, and finally sanious with or without crumbling particles of tissue), and pain (sometimes pruritus). Finally, the discharge assumes a most offensive character.

If the hemorrhages and pain are not so pronounced, the case is probably one of cancer of the uterine body.

The irregularity of the hemorrhages at the climacteric period easily deceive both the patient and the physician. These cases must consequently be watched all the more closely.

The pain is inconstant, of a tearing, boring, or lancinating character, and radiates to the sacrum and thighs. In corporeal carcinoma the pain is colicky or paroxysmal and is associated with the discharge of solid tissue particles from the uterine cavity. Other causes for the pain are pressure upon nerves, destruction of the uninvolved soft parts by the foul cancer discharge, the formation of fistulas, and the subsequent vesical catarrh.

## PLATE 82.

**A View of an Epitheliomatous Ulceration of the Mucous Membrane of the Cervical Canal.** The external os is intact. In spite of its apparent insignificance, this case was an inoperable one, as the atypical proliferation, as a matter of fact, extended deep into the parametritic tissues, involving the bladder wall and fixing the uterus. (Original water-color from an actual case.)

---

All varieties of vesical disturbance make their appearance. Vomiting and headache occur very early, from pressure upon the ureters (v. Winckel), and are to be looked upon as uremic in character. The urine is always decreased in amount.

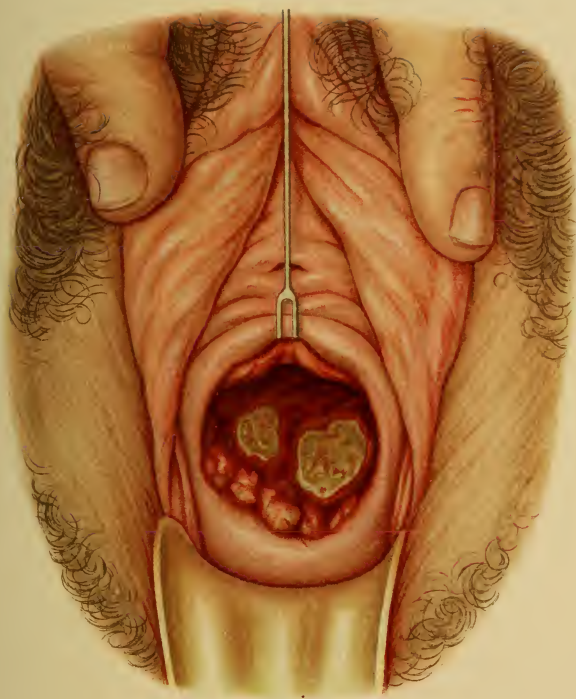
Later, as the wall of the bladder becomes affected, usually at the trigonum, with closure of the ureters by a dense infiltration, the symptoms assume an unmistakable uremic character. Almost complete anuria exists, the patient becomes unconscious, edematous, and has convulsions. The edema is increased by the firm infiltration of the parametritic tissues, which compresses the pelvic veins and produces thromboses. These infiltrations gradually narrow the rectum and cause fecal stasis, hemorrhoids, and tenesmus.

General symptoms occur—cachexia, reflex dyspepsia, and disgust for food. Death follows from exhaustion, uremia, or peritonitis.

**Diagnosis.**—Inspection of the cervix through the speculum. (See colored plates.) The tumors bleed easily, and are so friable that they tear when seized by tenacula.

In cervical ulceration it is to be noted that the os uteri remains closed and intact, while the cervical canal is transformed into a dilated, disintegrated cavity. This is demonstrated by the sound, as is also the disintegration of the walls of the dilated uterine cavity. These ulcers are punched out, with reddened, swollen edges; they have a lardaceous coating and bleed easily. They are found espe-

Tab. 82.





cially in the vaginal vault as extensions from the cervix, as well as in the cervical canal. (Plate 82.)

An absolute diagnosis is made by the microscopic examination of pieces of tissue, which are either cast off or intentionally scraped from the uterine wall. (Regarding glandular cancer, see Plate 30, Figs. 2 and 3.)

An exact anamnesis must always be obtained to avoid errors in diagnosis. In this way a decomposing abortion or retained placenta may be excluded at the beginning; the microscope would, in addition, reveal chorionic villi and decidual tissue. A disintegrating fibromyoma (see § 34, Differential Diagnosis) is recognized by the firm consistency of the pieces of tissue removed for diagnosis and by their histologic fibrous structure. The rare multiple condylomata of the cervix must be considered; they are not yellow, like the epitheliomata, but bluish-red; they have the same etiology as the condylomata of the vulva.

It is also to be mentioned that certain obstinate inflammations of the endometrium occurring at the menopause, and having the microscopic structure of fungous endometritis, are often nothing more than the beginnings of glandular cancers; in the same manner papillary erosions and laceration scars act as predisposing causes of papillary epitheliomata.

**Treatment.**—The suspected masses, with at least one or two centimeters of the surrounding healthy tissues, are to be immediately removed by operation.

As a prophylactic measure endometritis, erosions, laceration scars, and ectropion are to receive appropriate and early treatment.

If an epitheliomatous papilloma is certainly limited to the cervix (Plates 84, Fig. 2; 88, Figs. 2 to 4; 90, Fig. 2), one or both lips of the os and the affected portion of the vaginal vault may be removed. (Plates 80, Fig. 2; 81; 84, Fig. 1; 85, Fig. 1; 88, Fig. 1.)

If, on the contrary, we have to do with an ulcer of the cervix, it seems to me that its removal can be surely



## PLATE 83.

FIGS. 1 and 2.—**Epitheliomatous Ulcer of the Cervix.** (Through the speculum and in cross-section; original water-color.) (See also Plate 89, Fig. 2.) The tumor consists of the solitary primary nodules and of their ulcerations. Figure 2 shows the nodular infiltration of the cervical wall.

---

secured only by the total extirpation of the uterus. Schröder's supravaginal amputation of the cervix through the vagina, even if the ulcer does not reach to the internal os, is frequently followed by recurrences in the body of the uterus, from which metastases may occur. It may not be a question of metastasis at all, as we have specimens which show that beginning carcinomatous degeneration may simultaneously exist in the body or fundus of the uterus and in the cervix. (Plates 82 ; 83 ; 85, Fig. 2 ; 89, Figs. 1 and 2.)

Total extirpation may be performed :

1. Through the vagina (Langenbeck-Czerny)—colpohysterotomy.
  2. After opening the abdominal cavity (Freund)—celiohysterotomy.
  3. By the sacral method (Hochenegg-Herzfeld-Hegar).
  4. By the parasacral method (Wölfler).
- 

## PLATE 84.

FIG. 1.—**Epitheliomatous Papilloma of the Anterior Lip of the Os Uteri and of the Anterior Vaginal Vault.** (Original water-color.) (See Plates 79, 85, and 88.) The tumor consists of uneven bluish masses, which render the os difficult of recognition by palpation. This form spreads along the surface.

FIG. 2.—**Beginning Epithelioma of the Cervix.** (Original water-color from a case of v. Winckel's.) Small round nodules develop at the external os. They are in the cervix, beneath the mucous membrane, and soon ulcerate.

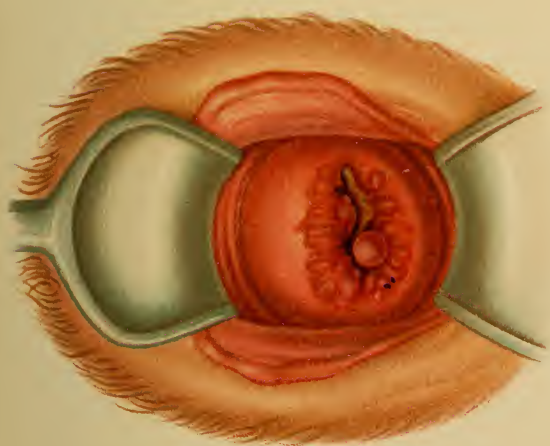



Fig. 1.

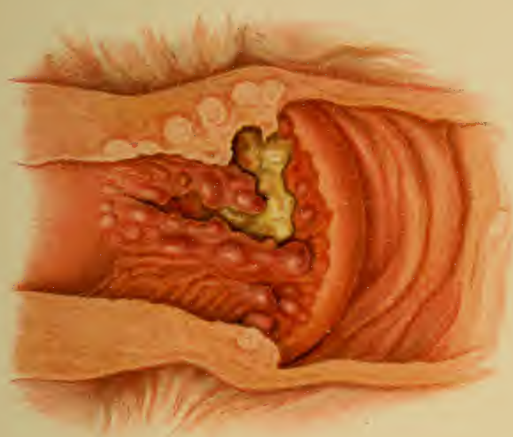

Fig. 2.





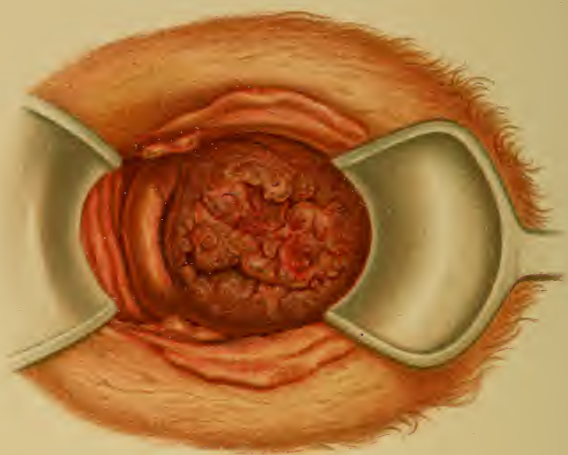


Fig. 1

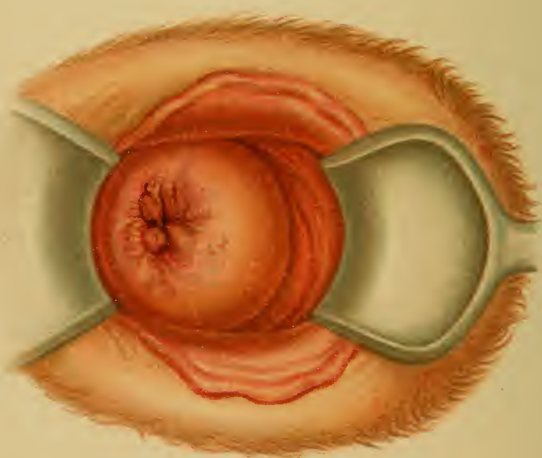


Fig. 2

*Excision of the Tumor of the Hand*



The patients are prepared as usual (full bath, evacuation of the bowels by laxatives and enemata, bladder emptied immediately before the operation); the vaginal and uterine cavities are to be irrigated several times with antiseptic solutions and then wiped out.

1. *Vaginal Extirpation*.—The cervix is made accessible by means of Simon's duckbill specula (one posterior, one anterior, and two lateral retractors), and is drawn down by a stout ligature passed through its substance. If the parametritic tissues are infiltrated, the uterus is more or less fixed, and a removal of all the diseased tissue is out of the question.

The stout ligature not only aids in drawing down the uterus, but at the same time it also closes the external os and prevents the escape of the infectious masses of an intra-uterine carcinoma. If the case is one of papilloma of the cervix, as much as possible of the carcinomatous tissue is to be removed by the knife, scissors, and sharp curet, and the remainder is to be destroyed with carbolic acid or Paquelin's cautery before the vaginal vault is opened. The vagina is to be again wiped clean with antiseptics.

After the removal of the uterus from the ligated adnexa, the wound in the vaginal vault is made smaller by several sutures and is drained with iodoform gauze. The ligatures left in the adnexa and about the parametritic vessels usually come away spontaneously. The patient is to be kept in bed for two or three weeks.

2. *Total Extirpation by Celiotomy*.—This operation, devised by Freund, is still indicated to-day for large dense tumors (or those complicated with fibromyomata) that can not be removed through the vagina. Bardenheuer's modification is the best: the cervix is circumscribed by a vaginal incision; the abdominal cavity is opened, the ligaments are tied off on each side in three sections, the uterus is removed, and the wound is united by suture.

3. *The sacral and the parasacral methods* may be carried out if adhesions, parametritic cancer nodules, or a large uterus (it may be puerperal) render the median incision ineffectual.

The inoperable cases demand symptomatic treatment.

1. *For the putrid suppuration*: removal of the carcinomatous masses by means of knife, scissors, curet, and thermocautery. As an eschar, and later a malignant granulating surface, is left behind, the wound should be closed as far as possible by sutures, which exert a certain restraining pressure upon the all-too-rapid proliferation. During this excochleation, avoid creating rectal or vesical fistulas. Atmocaussis is to be employed in such cases.

As far as caustics are concerned, especially in cases that can not be cureted, I wish to mention only carbolic acid and formalin. Schröder applied 20 % bromin alcohol for

## PLATE 85.

**FIG. 1.—Epitheliomatous Papilloma of Both Lips of the Os.** The tumor has ulcerated, invaded the deeper tissues, and spread to the anterior vaginal vault. (Original water-color.)

**FIG. 2.—Epitheliomatous Ulcer of the Cervix.** (Original water-color.) The external os and the cervix are intact; the lips of the os and the cervical wall are, however, markedly thickened by the carcinomatous infiltration. The cervical canal is ulcerated and forms a crater between the external and the internal os, which is easily demonstrable by the sound. The walls contain disintegration cysts filled with putrid masses. Solitary cancer nodules are seen in the body of the uterus. The neck of the uterus is much enlarged, in contrast to the body.

---

five minutes by means of cotton tampons. These were held in position by tampons saturated in normal saline solution. Nitrate of lead (powdered, 30 parts, with 70 parts lycopodium) is slower in its action—from twelve to sixty hours.

For the fetid odor: potassium permanganate in strong solution (dark reddish-brown), or irrigation several times daily with 1% or 2% creolin, cresol soap, or lysol. Quinin iodid and aristol are to be used as dusting-powders.

2. *For the hemorrhages* the following treatment is pallia-

---

## PLATE 86.

**FIG. 1.—Epithelioma of the Cervix That Has Perforated into the Bladder.** (Original water-color.) In spite of the great destruction above it, inspection shows the os uteri to be almost completely unchanged. Greenish-gray putrid masses and necrotic shreds cover the floor of the carcinomatous ulcer. The uterine wall is infiltrated with nests of cancer cells. (See Plate 89, 5.)

**FIG. 2.—Perforation of an Epithelioma of the Cervix into the Bladder and Rectum.** (Original water-color from a specimen of v. Winckel's.) The os uteri has become ulcerated and the process extends to the vagina. (See Plate 89, 6.)

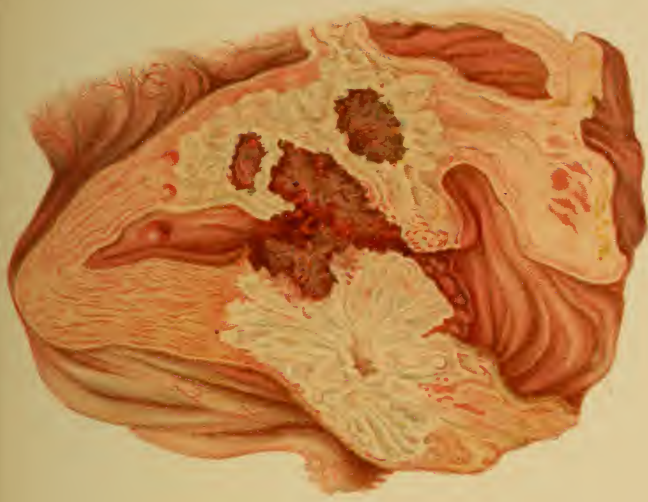


Fig. 2.

Lith. Arch. d. Koenigl. Med. Mus.

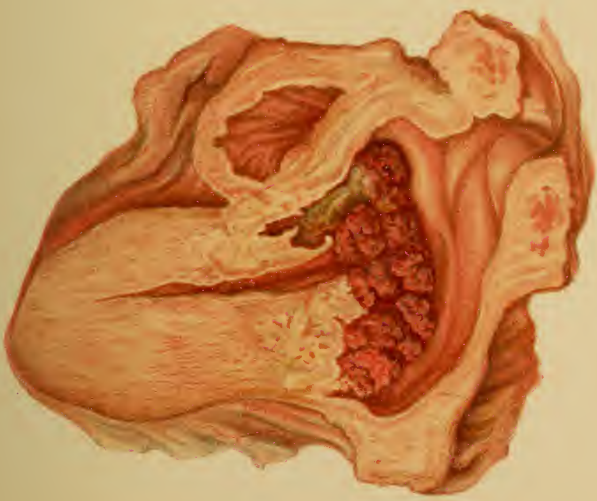

Fig. 1.



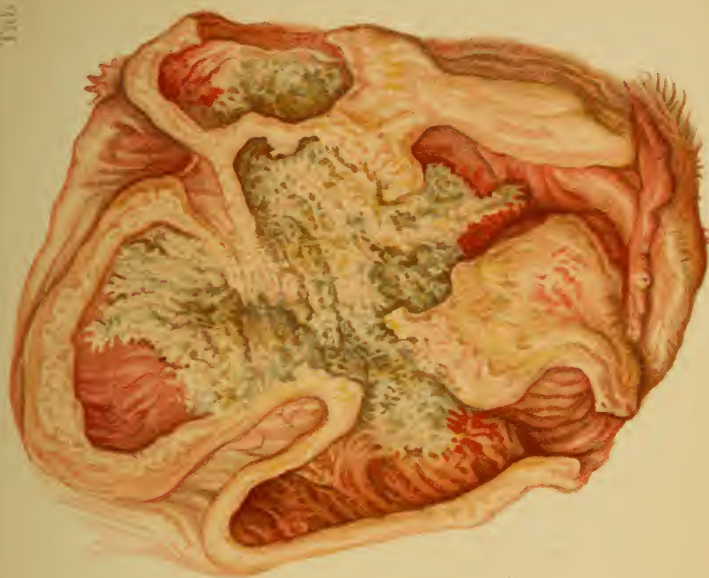


Fig. 2. *Uterus post. & broadhead. Mordant.*

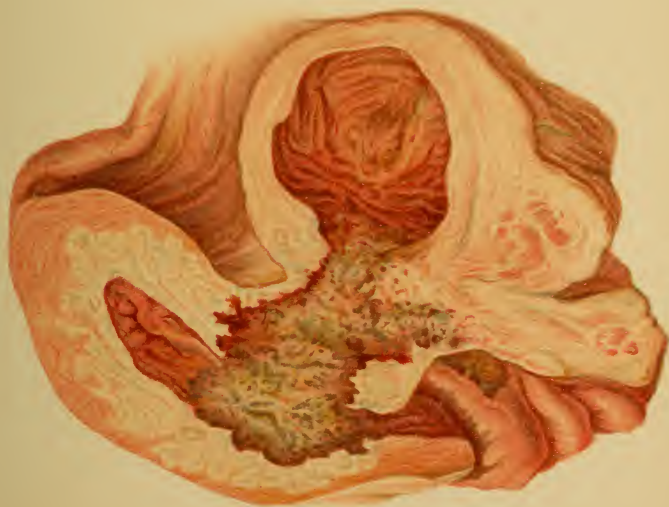

Fig. 1.





tive: astringent irrigations or vaginal suppositories, vinegar, alum, ferripyrin powder, chlorid of iron; iodoform gauze tamponade, or packing with gauze soaked in solution of aluminum acetate or in formalin solution.

The general nutrition is to be carefully regulated. Preference is to be given to a light, easily digestible and stimulating diet, with stomachics (compound tincture of cinchona), hematogen, hemalbumin, ferratin, wine of iron peptonate, and the like. Laxatives and high injections, if necessary, with infusion of senna.

3. *For the Lancinating Pains.*—The following may be used successively as the pains grow more severe: sulphonal, trional, urethan, and chloralamid by the mouth; antipyrin, extracts of hyoscyamin and belladonna, chloral, and laudanum by the rectum, later also by the mouth; finally, morphin subcutaneously in gradually increasing doses.

4. *For the vomiting:* stomachics, decoctions of condurango, cracked ice, cold milk (buttermilk), iced champagne, cold tea.

5. *For the headache:* cold applications, lactophenin, phenacetin, antipyrin.

Since the two latter symptoms are of a uremic nature, they are also to be treated by warm baths, hot packs, and the induction of profuse sweating.

## II. Sarcoma of the Uterus.

For anatomy see Plate 73.

These tumors are as malignant as the carcinomata, if not more so. They occur in the uterine body as primary growths or as secondary deposits from ovarian sarcomata (see Plate 87, 2); the patients affected are often in their youth. They usually consist of a round-cell proliferation, sometimes associated with spindle cells. (Plate 73.) They become villous or polypoid, and dilate the os uteri. Metastases take place through the venous system—finally as

## PLATE 87.

FIG. 1.—**Carcinoma of the Uterine Body.** (Original water-color from a specimen of v. Winckel's.) Nodular, soft, easily crumbling, bluish-red masses are seen upon the mucous membrane. They also extend into its depths, either as solid plugs of cells from the superficial epithelium, or as a malignant adenoma from the glandular epithelium.

FIG. 2.—**Sarcoma of the Uterus.** (Original water-color from a specimen from the Munich Frauenklinik.) The soft, fibrous masses are like tinder. They are mucous, muscular, or subperitoneal, and may arise from the myxomatous degeneration of a fibroma. (See also Plate 73.)

pulmonary emboli. Endotheliomata occur very rarely on the cervix.

**Symptoms.**—The discharge is profuse, mucoid, not

## PLATE 88.

FIG. 1.—**Flat Cervical Epithelioma of Both Lips of the Os Uteri Involving Both Vaginal Vaults.** There are two varieties of epithelioma of the cervix: (1) the superficial form; (2) the epitheliomatous papilloma. Both consist of plugs of the proliferating squamous epithelium. (See Plate 79.)

FIG. 2.—**Epitheliomatous Papilloma of Both Lips of the Os Uteri.** (See Plate 85, Fig. 1.)

FIG. 3.—**Polypoid Epitheliomatous Papilloma of the Anterior Lip of the Os Uteri.**

FIG. 4.—**Epitheliomatous Papilloma of the Posterior Lip of the Os Uteri Filling the Entire Posterior Vaginal Vault.**

FIG. 5.—**Villous Cancer of the Bladder in Its Most Frequent Position.** (In the region of the ureteral orifices.) It has infiltrated the vesicovaginal septum. It causes cystitis; cancer cells and shreds of tissue are found in the urine.

FIG. 6.—**Rectal Carcinoma (Glandular Cancer) Infiltrating the Rectovaginal Septum.** The tumor undergoes a crater-like disintegration, so that examination reveals two stenoses, between which a considerable dilatation is situated.

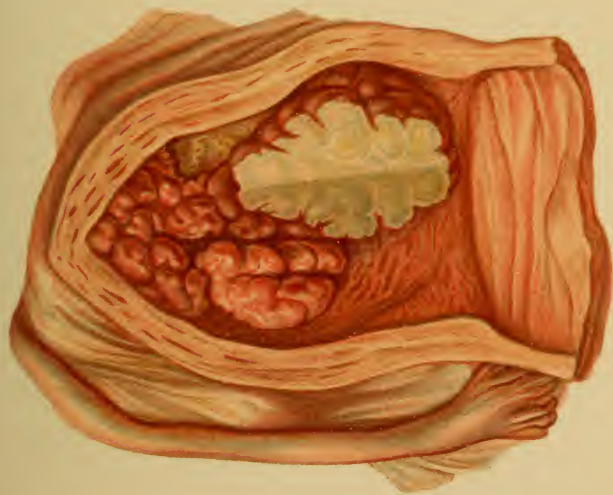


Fig. 1.

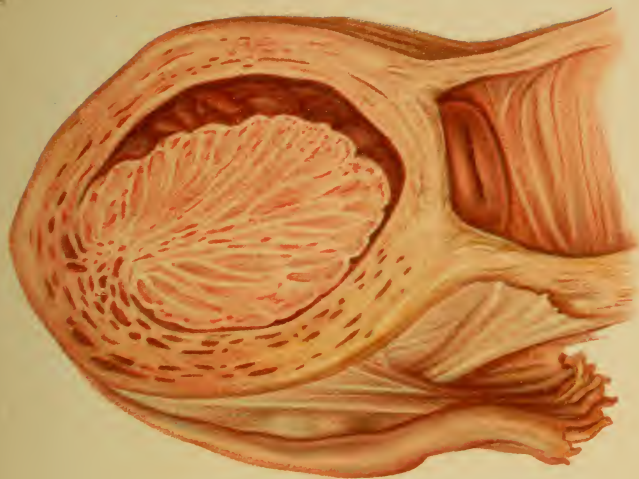
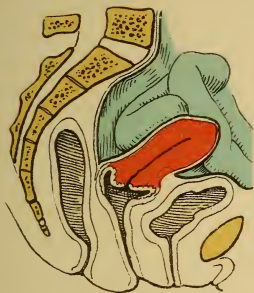

Fig. 2.

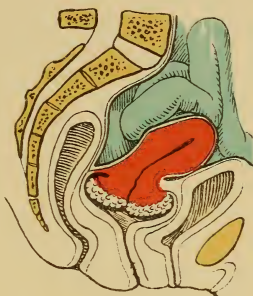Lun. Anst. P. Reichhold. München.



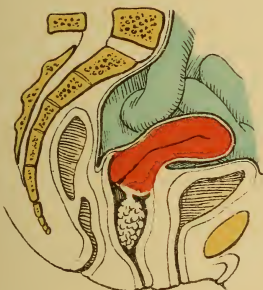



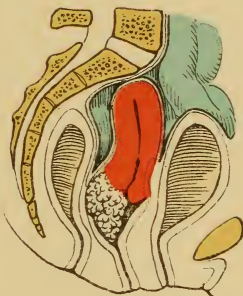
*Fig. 1.*



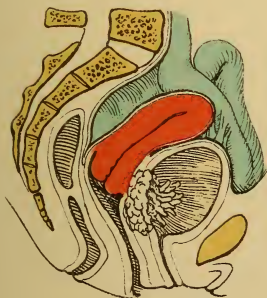
*Fig. 2.*



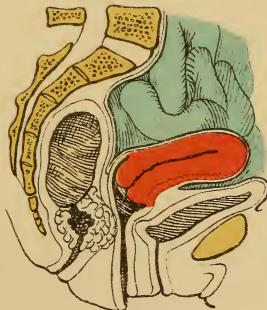
*Fig. 3.*



*Fig. 4.*



*Fig. 5.*



*Fig. 6.*



very bloody, and, in contrast to carcinoma, not offensive until late in the disease. Pain first appears with the dilatation of the os uteri. Metastases to the lung cause dyspnea and cyanosis. Anemia is present if the hemorrhages are severe.

**Diagnosis.**—Enlargement of the uterus (see Plate 87) with or without dilatation of the os uteri. If the os is intact, dilate and palpate the uterine cavity; villous polypoid excrescences are present. Microscopic examination of cureted pieces. If the fibrous character of the tissue renders its nature doubtful, look especially for “giant cells.” (See Plate 73, Fig. 2.) It is to be remembered that a fibromyoma may undergo sarcomatous degeneration. (See Differential Diagnosis, § 34.)

**Treatment.**—If mucous, excochleation; if the uterus is enlarged, total extirpation. If too far advanced, symptomatic—as in carcinoma.

## § 38. MALIGNANT TUMORS OF THE ADNEXA, ESPECIALLY OF THE OVARIES.

### I. Carcinoma.

Carcinoma of the ovary occurs in various forms: (1) Solid papillary; (2) a form resembling the papillary cystadenomata, but more solid; (3) a form resembling the multilocular cystadenomata, but with areas of softening; (4) metastases from a uterine carcinoma, diffuse nodules in the enlarged ovary (very rare).

**Anatomy.**—The ovaries are disposed to carcinomatous degeneration, not infrequently at the age of puberty (Olshausen).

**Symptoms.**—Nonappearance of the menses, ascites and peritoneal phenomena, early cachexia, and metastases with disturbances of the circulation in the lower extremities. Stenosis of the rectum. (See Plate 59, Fig. 4.)

**Diagnosis.**—An enlarged, rapidly growing ovary, or ascites with a previous pure glandular cystoma. Exploratory incision and demonstration of nodules, and multiple,

## PLATE 89.

**FIG. 1.—Cancer Nodules in the Cervix, Which Has Not Yet Ulcerated.** The os uteri is closed; the anterior lip is thickened from the carcinomatous infiltration. (See also Plates 80, 82, 83.)

**FIG. 2.—Epitheliomatous Ulcer of the Cervix.** The os uteri is closed. (See Plate 85.)

**FIG. 3.—Epitheliomatous Ulcer of the Cervix Which Has Invaded the Uterine Body.** The os uteri is destroyed.

**FIG. 4.—Carcinoma of the Body of the Uterus Which Has Perforated into the Bladder.** (Plate 86, Fig. 1.) The os uteri is intact.

**FIG. 5.—Epitheliomatous Ulcer of the Cervix Which Has Perforated into the Bladder.** The fundus of the uterus is intact; the os is destroyed.

**FIG. 6.—Epitheliomatous Ulcer of the Cervix Perforating into Both Bladder and Rectum.** (Plate 86, Fig. 2.)

---

diffuse, papillary, excrescences in and upon the peritoneum.

**Treatment.**—Extirpation, if limited to the ovary; if the growth is not so localized, violent pressure symptoms demand tapping or the formation of an artificial anus.

Glandular carcinomata of the tubes are very rarely primary, and, as such, are impossible to diagnose.

---

## PLATE 90.

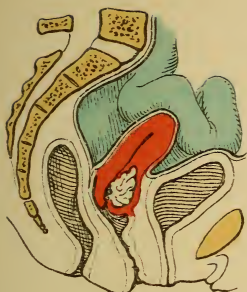
**Four Tumor-like Changes at the External Os.**

**FIG. 1.—Fungous Endometritis and Ectropion.** (See Plates 30, 31, 56.) Cystic dilated glands in the cervical mucosa.

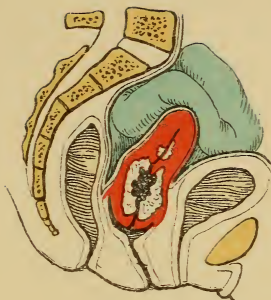
**FIG. 2.—Epitheliomatous Papilloma of Both Lips of the Os.** (See Plates 81, 84, 85.)

**FIG. 3.—Ovules of Naboth in a Mucous Polyp, Visible at the Os Uteri.** (See Plates 29, 56.)

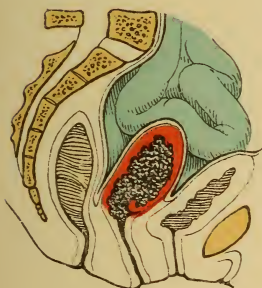
**FIG. 4.—Fibroid Polyp Separating the Lips of the Os Uteri.** (See Plate 60, Fig. 2.)



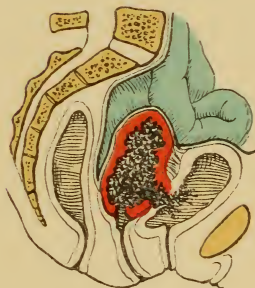
*Fig. 1.*



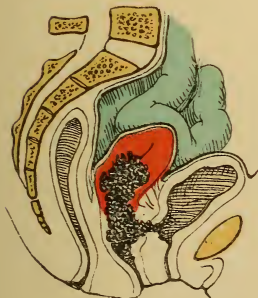
*Fig. 2.*



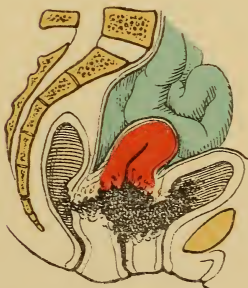*Fig. 3.*



*Fig. 4.*



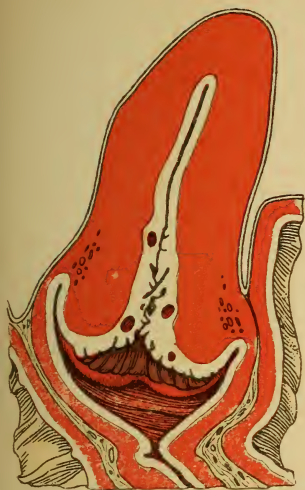*Fig. 5.*



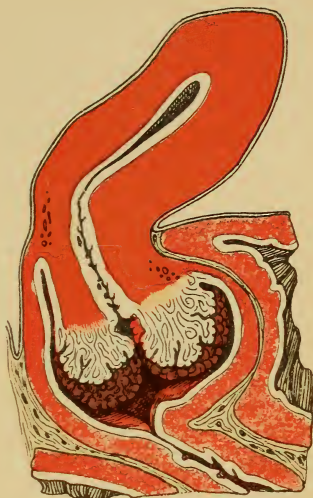*Fig. 6.*



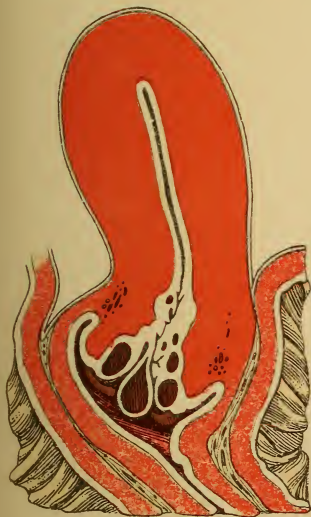



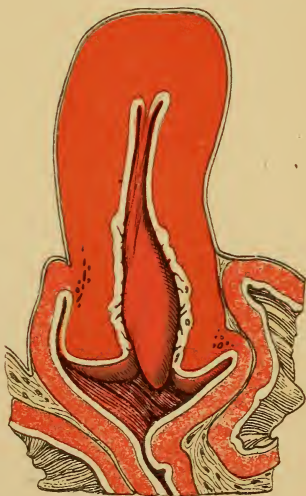
*Fig. 1.*



*Fig. 2.*



*Fig. 3.*



*Fig. 4.*



## II. Sarcoma.

These are usually spindle-cell tumors in early life, combined with deposits of round cells and degenerations of a myxomatous or carcinomatous character. They grow slowly, and their diagnosis and treatment are the same as those of ovarian fibromata. (See §§ 33 and 35.) Sarcomata also occur in the ligaments.

Endotheliomata (angiosarcomata) may grow to a considerable size and show a decidedly malignant character. They have a cavernous structure; the tissue is usually myxomatous.

The treatment is generally hopeless, as total removal is usually fruitless, even when carried out at the first appearance of symptoms.



## THERAPEUTIC TABLE.

---

1. **Absorbents.**—Sapo medicatus, potassium iodid, tinct. iodi, iodin glycerin, ichthyol, hot vaginal douches, mud-baths, brine-baths, hot sand-baths.

### Acids :

2. **Acetic Acid** (Pyroligneous Acid).—1 : 3 or concentrated. To be applied through the speculum (with 3 to 4% carbolic acid) every two or three days for weeks and months; erosions; cervical catarrhs.
3. **Boric Acid.**—2 to 3%. In cystitis, urethritis ; 2 to 4 injections daily.
4. **Boric Acid Vaseline.**—5 : 20, for pruritus.
5. **Carbolic Acid.**— $\frac{1}{2}$  to 2%, in vaginitis, endometritis. 2 to 5%, in vulvitis. 3 to 5% or concentrated, to wipe out the uterine cavity, multiple recurrent polyps, fistulas.
6. **Carbolic Acid.**—2%. Subcutaneously,  $\frac{1}{2}$  to 2 syringefuls in lupus, erysipelas.
7. **Carbolic Acid Glycerin.**—2 to 4%, endometritis, metritis.
8. **Carbolic Acid Intoxication.**—Small doses of opium, morphin, ice, milk, soluble sulphates.
9. **Chromic Acid.**—25 to 33%, as a caustic for condylomata.
10. **Chromic Acid.**—33%, in fistulas, endometritis (every week).
11. **Fuming Nitric Acid.**—As a caustic in lupus, fistulas, endometritis, one drop upon cotton every four to five days. It acts most promptly when immediately followed by the application of liquefied carbolic acid.
12. **Salicylic Acid.**—1 to 5 : 1000, in pruritis, vaginitis, cystitis. 1.0 to 5.0 (gr. xv to gr. lxxv) salicylic acid powder are dissolved in alcohol, and added to one liter of lukewarm water (irrigator); it is not caustic.  
*Salicylic Acid Vaseline* (Lanolin, Mollin).—1 : 300, for pruritus.
13. **Tannic Acid.**—0.3 (gr. v), intra-uterine pencil for endometritis. (See Intra-uterine Pencils.)
14. **Tannic Acid Vaginal Suppositories.**—0.4 (gr. vj) with 3.0 (gr. xlv) cacao-butter in blenorrrhea.



15. **Aloes Extract.**—Ext. rhei comp., aa 3.0 (gr. xlv). Ft. in pil. No. xxx, two pills daily. Laxative, emmenagog.
16. **Althea Decoction.**—Injection for vaginitis, acute endometritis, acute myometritis.
17. **Alum in Intra-uterine Pencils.**—0.3 (gr. v), 4 cm. long, 0.2 to 0.4 cm. thick, with gum arabic and glycerin, in endometritis.
18. **Alum Solution.**—1 to 3 to 6%, as injection or upon tampons in vaginitis, vaginal inversion. Iodoform gauze is saturated with the solution, and renewed every three hours in acute vaginal gonorrhea.
19. **Alum Vaselin** (Lanolin, Mollin).—2 to 4 : 50, in pelvitis, vaginitis, vaginal inversion.
20. **Aluminum Acetate Solution.**—10 to 20%, astringent vaginal injection. 2 to 5%, intra-uterine application.
21. **Antipyrin.**—0.5 to 1.0 (gr. viij–xv), in pill, every two hours (6.0 — 3 iss—pro die), for menstrual molimina, dysmenorrhea, pain, fever.
22. **Antipyrin.**—2.0 (gr. xxx), in solution, as an enema. Also used subcutaneously, 1 : 2; the syringe must be carefully cleaned after each injection to prevent the precipitation of antipyrin crystals.
23. **Antispasmodics.**—(See Antipyrin, Chloral, Chloroform, Morphin, Opium, Ext. Viburn. Prunifol. Fld.)
24. **Applications and Fomentations.**—"Priessnitz," for paralysis of the vesical sphincter, peritoneal irritation, acute corporeal endometritis, oophoritis.  
*Brine.*—In myomata, chronic parametritis, perimetritis, metritis, and oophoritis.  
*Hot Water.*—In menorrhagia, dysmenorrhea, combined with hot alcohol.  
*Lead-water.*—(See Same.)
25. **Argent. Nitrat.**—2% solution, in endometritis, ulcerations of the vaginal cervix, urethritis; to be applied or injected (every week); or 0.2 to 0.5 : 1000 to be injected from 4 to 6 times daily.
26. **Argent. Nitrat.**—1 to 2 to 6 : 1000, in cystitis.
27. **Argent. Nitrat.**—5 to 10 to 20% or solid stick, in pruritus, vaginitis, fistulas; applied every week.
28. **Argentamin.**—Specific for older cases of gonorrhea: 1 to 2%, intra-uterine; 5%, in the vagina.
29. **Argonin.**—Specific for gonorrhea: 3 to 5%, intra-uterine; 2%, vesical irrigation; 5 to 10%, vaginal irrigation.
30. **Astringents.**—Alum, aluminum acetate solutions, cupric sulphate, decoctions of oak-bark, formalin, glycerin, lead-water, tannin.
31. **Bathing Resorts.**—Mud-baths (absorbent), Teplitz, Franzensbad, Kissingen, Elster and Mattoni's mixture (5 liters to the

bath) in metritis, parametritis, and perimetritis, chronic oophoritis, hematocele.

*Brine-baths*.—Kreuznach, Tölz, Nauheim, Küssen, Oeynhausien, Hall (upper Austria), Heilbronn, or artificially produced by adding from 10 to 20 pounds of lye or sea-salt to the warm bath. Applicable in myomata, scrofula, vulvitis, metritis, chronic parametritis, and perimetritis (one-half to one and one-half hours in duration, followed by one hour's rest).

For Anemia: Brückenau, Triburg, Elster, Franzensbad, Pyrmont, Schlangenbad, Schwalbach, St. Moritz, Wildbad.

*Hot Sand-baths*.—Blasewitz near Dresden, Küstritz near Gera. Applicable for same affections as mud-baths. May be replaced by thermaphore.

*Iodin Baths*.—Kreuznach, Tölz, Hall, in scrofula.

*Sea-baths*.—In nocturnal enuresis, scrofulous vulvitis, menorrhagia.

For Vesical and Renal Disease: Carlsbad, Wildungen (0.5 (gr. viij) sodium salicylate with 0.015 (gr.  $\frac{1}{4}$ ) morphin to  $\frac{1}{3}$  of a liter, in cystitis), Neuenahr, Assmannshausen, Obersalzbrunn, Vichy, for menorrhagia from nephritis.

32. **Baths**.—Warm baths, 95° to 100° F. (one-quarter to one-half hour), in paralysis of the vesical sphincter, uremia (carcinomatous), oophoritis, acute endometritis, chronic metritis, and subinvolution.

*Foot-baths* (100° F.), with 1 to 3 tablespoonfuls of salt or mustard once or twice daily in oligorrhea, amenorrhea, anemic dysmenorrhea.

*Sitz-baths* (90° to 100° F.), with wheat bran ( $\frac{1}{2}$  to 1 pound), decoctions of oak-bark (7 to 10%), one and a half to two hours, in pruritus, urethritis.

*Sitz-baths*, with tannin or alum (2%), sea-salt or lye (1 pound to 2 bucketfuls of water), as before, in dysmenorrhea, amenorrhea, urethritis, pruritus, parametritis, and perimetritis (ten to twenty minutes in the beginning).

33. **Belladonna Extract**.—As rectal or vaginal suppository 0.02 (gr.  $\frac{1}{3}$ ) with 3.0 (gr. xlv) cacao-butter, in rectal and vesical tenesmus, dysmenorrhea, endometritis, and myometritis, neuroses of the uterus and vagina.
34. **Belladonna Tinct.**—20 drops t. i. d. (with potassium bromid, 0.3 (gr. v), in nocturnal enuresis.
35. **Belladonna = vaselin** (Lanolin, Mollin).—1 to 2 : 50, in pruritus.
36. **Bismuth Subnitrate**.—Intra-uterine pencils (0.2, gr. iij), in endometritis.
37. **Bismuth Subnitrate Solution**.—2 to 3%, astringent intra-uterine application.
38. **Bismuth Subnitrate Ointment**.—10%, in eczema, herpes.
39. **Bismuth Talcum**.—Dusting-powder for profuse secretion.

40. **Bromin Alcohol.**—20%, hemostatic injection in carcinoma.
41. **Byrolin=boric Acid—Lanolin=glycerin.**—Good salve for the hands.
42. **Caffein Citrate.**—0.1 (gr. iss) (with lactophenin, sacchar. alb., āā 0.5, gr. vij), for hemicrania.
43. **Caffein Sodium Benzoate.**—0.2 (gr. iij), t. i. d., in migraine.
44. **Calomel.**—0.25 (gr. iv) (with sacchar. alb., 0.5, gr. viij) several times daily, or 0.5 (gr. viij) at one dose, as a laxative, in acute peritonitis, parametritis, and metritis. To be followed by from 15 to 20 drops tinct. opii; later, 0.05 to 0.1 (gr.  $\frac{3}{4}$  to iss).
45. **Camphor.**—1.0 (gr. xv), ol. amygd. dulc., 9.0 (ʒ ij), subcutaneously in collapse.
46. **Camphor, Monobromate.**—0.1 to 0.3 (gr. iss to v) with sacchar. alb., 0.5 (gr. viij), three times daily in hysteric conditions of irritability.
47. **Carlsbad Salts.**—1 to 3 teaspoonfuls on rising, in a glass of lukewarm water, as a laxative.
48. **Cascara Sagrada.**—Ext. fld., syr. zingiberis, aquæ, āā 10.0 (ʒ iiss), a teaspoonful twice daily, as a laxative.
49. **Catheter, Permanent.**—15 to 30 cm. long, 0.6 to 0.7 cm. thick; left in position for three days; it is to be well sterilized!
50. **Catheterization.**—Before every operation, after perineoplasty, in paralysis of the vesical sphincter, incontinence of retention.
51. **Caustics.**—(See Fuming Nitric Acid; Argent. Nitratis, 2 to 20%; Carbolic Acid, 3%, conc.; Chromic Acid, 33%; Zinc Chlorid, 5 to 10 to 50%; Vienna Paste; Solution of Mercurous Nitrate; Caustic Potash; Sublimate, 1 : 1000; Formalin, conc.) The vagina is to be thoroughly irrigated after cauterizing the uterus.
52. **Caustic Potash** —Fistulas, lupus.
53. **Caustic Potash.**—1 : 300, aq., in severe cases of intertrigo.
54. **Chloral.**—By the rectum, 1 to 2 : 15 (with potassium bromid, āā), in rectal and vesical tenesmus, dysmenorrhea, carcinoma.
55. **Chloral in Rectal or Vaginal Suppositories.**—0.5 (gr. viij) with 3.0 (gr. xlv) cacao-butter, for vesical and intestinal tenesmus, dysmenorrhea, uterine and vaginal neuroses, carcinoma.
56. **Chloral Solution.**—5 : 100 (with syr. aurant. cort., 25), to be taken for the same affections as above.  
*Chloral Solution.*—(With syr. aurant. cort., āā), 15 : 175 aq.; one teaspoonful 3 or 4 times daily, in nocturnal enuresis. It may be combined with potassium bromid.
57. **Chlorin Water.**—(and aq. dest., āā 50.0 (ʒ iss) with 1.0 (gr. xv) acid. hydrochlor.) one tablespoonful every two hours in meteorism, peritonitis, diarrhea.

58. **Chloroform Narcosis.**—Chloroform, 3; sulphuric ether, 1; absolute alcohol, 1 (Billroth). Chloroform + ether (1 : 2) = Vienna mixture.
59. **Chloroform and Ol. Hyoscyami**, āā 10.0 (ʒ iiss).—Inunction in pruritus; upon tampons for the pain from carcinoma, perimetritis and parametritis, oophoritis.
60. **Cocain Hydrochlor.**—5 to 10% solution or ointment as a local anesthetic, in pruritis (alternating with 10 to 20% argent. nitrat.), vaginismus, uterine and vaginal neuroses, dysmenorrhea.  
*Cocain Hydrochlor.*— $\frac{1}{4}$  to 1 : 1000, as injection, in cystitis.  
*Cocain Hydrochlor.*—0.01 to 0.2% in 0.2% NaCl solution for Schleich's infiltration anesthesia.  
*Cocain Hydrochlor.*—In rectal or vaginal suppositories: 0.1 (gr. iss) to 3.0 (gr. xlv) cacao-butter, in vesical and rectal tenesmus, carcinoma.
61. **Colocynth. Ext.**—0.005 to 0.02 (gr.  $\frac{1}{13}$  to  $\frac{1}{3}$ ), as a drastic cathartic.
62. **Condurango Decoction.**—12 : 175, in carcinomatous dyspepsia.
63. **Cornutin Citrate.**—0.003 to 0.005 (gr.  $\frac{1}{22}$  to  $\frac{1}{13}$ ), in pill, twice daily, in metrorrhagia.
64. **Cupric Aluminat.**—1.0 to 5.0 : 1 liter of water, in endometritis.
65. **Cupric Sulphate.**— $\frac{1}{2}$  to 2% injection or upon tampons, in metrorrhagia; 1 : 1000, in endometritis.
66. **Cupric Sulphate Vaseline or Zinc Sulphate Vaseline.**—2 to 3 to 5 : 50 to 75, on tampons, in metrorrhagia.
67. **Dermatol**, as a dusting-powder after plastic operations.
68. **Diaphoretics.**—Ammonium chlorid solution (5 : 200), liq. ammon. acetat. (1 to 2 teaspoonfuls in elderflower or chamomile tea).
69. **Diet in Anemia.**—(See § 3, under 7, Treatment.)
70. **Digitalis Inf.**—2 : 180, syrupi 20, one teaspoonful every two hours (with potassium nitrate 10.0—ʒ iiss), in menorrhagia from cardiac disease.
71. **Disinfection of the Hands.**—(See § 34, under Treatment.) In office practice the hands must be scrubbed with alcohol and 1 : 2000 sublimate, especially if they have come into contact with discharges. Instruments (specula, sounds) are to be well boiled each time they are used.
72. **Diuretics.**—Potassium nitrate, urotropin. (See under Digitalis in Pelvic Peritonitis.)
73. **Douches, Hot.**—(See Vaginal Injections.)
74. **Dry Cups.**—In oligomenorrhea, dysmenorrhea.
75. **Emollients.**—Linseed decoctions, oatmeal water, althea decoction, starch.

76. **Enemata for Hemorrhage.**—0.6% warm NaCl solution (2 liters or more); alcohol, wine.
77. **Enemata of Oil.**—In intestinal and vesical tenesmus. (See Tinct. Opii, Emollients, and Injections, Rectal.)
78. **Enemata (Purgative).**— $\frac{1}{2}$  to  $1\frac{1}{2}$  liters of lukewarm mucilaginous or oily fluid, or of water with or without salt, soap, glycerin, or senna (5.0—gr. lxxv—to the cup).
79. **Ergotin.**—(See *Secale Cornutum*.)  
2.0 (ʒss) with aq. dest. 8.0 (ʒij) and acid. carbolic. fld. gtt. j, one syringeful daily (three to six times a week); 0.2 (gr. iij), in menorrhagia, metrorrhagia, myomatosis.
80. **Ergotin.**—2.5 (gr. xxxviiij) with aq. dest. 15.0 (ʒiij) and acid. salicyl. 0.05 (gr.  $\frac{3}{4}$ ); 1 to 2 syringefuls = 0.15 to 0.3 (gr. ij—ivss), as in above affections.
81. **Ferric Chlorid Solution.**—20 to 50% or concentrated, applied upon cotton to the interior of the uterus by means of the aluminum sound; or, upon tampons or injected, in multiple recurrent sessile polypi, menorrhagia, carcinoma, Werlhof's disease, myomata.
82. **Ferric Chlorid Solution.**—1 : 800, injected into the bladder in hematuria—ferripyrrin is better.
83. **Ferripyrrin.**—In powder or solution, 1 : 5, as a hemostatic.
84. **Formalin (35% formaldehyd solution).**—1 : 2 to 3 parts of water, 1 tablespoonful to a liter of water, as a vaginal and intra-uterine irrigation. Undiluted as a caustic agent.
85. **Frangula Cortex.**—Add 1 tablespoonful to 3 cups of water, and evaporate to 2 cups; or—
86. **Frangula Decoctions.**—25.0 (ʒviss) : 180.0 (f ʒvj) with sodium salicylate 5.0 (gr. lxxv) and sodium sulphate 20.0 (ʒv). A wineglass of this mixture is given morning and evening as a laxative. The fluid extract is given in doses of from 20 to 40 drops.
87. **Gelatin Injections.**—Intra-uterine, as a hemostatic.
88. **Hemostatics.**—Ferripyrrin, ferric chlorid solution, aluminum acetate solution, gelatin emulsion.  
Iodoform gauze tampon ; galvanocautery, Pacquelin's cautery, actual cautery, atmocausis (in operations for carcinoma and myoma); bromin alcohol (carcinoma).
89. **Hydrarg., Ung.**—1.0 to 8.0 (gr. xv to ʒij) pro die, with equal part of vaselin, inunctions, every two hours for a week, in peritonitis.
90. **Hydrastis Canad. Ext. Fld.**—15 to 25 drops, four times daily, for months, in menorrhagia (especially if ovarian).



91. **Hydrastinin Hydrochlor.**—0.05 (gr.  $\frac{3}{4}$ ) in pill, three times daily; or 10% solution,  $\frac{1}{2}$  to 2 syringefuls (subcutaneous) pro die.
92. **Hyoscyami, Oleum.**—As inunction. (See Chloroform.)
93. **Hyoscyami Ext.**—1.5 (gr. xxij) with aq. amygd. am. 150.0 (f  $\frac{3}{4}$  v), 15 drops, four times daily, in uterine and vaginal neuroses, vesical and intestinal tenesmus, dysmenorrhea.  
*Hyoscyamus Injections.*—15 : 1000, in vaginitis, dysmenorrhea.
94. **Hysteria.**—Asafetida; ext. cannabis indica; lactophenin, 0.5 to 1.0 (gr. vij to xv); salophen, 1.0 (gr. xv); salipyrin, 1.0 (gr. xv); phenacetin, 0.5 to 1.0 (gr. vij to xv); antipyrin, 0.5 to 1.0 (gr. vij to xv), also by the rectum; monobromated camphor; castoreum; chloral; chloroform; belladonna; cocain; hyoscyamus; potassium bromid; morphin; opium; flor. chamomillæ; fol. menth. pip.; valerian.
95. **Ice=bag.**—In acute oophoritis, peritonitis, parametritis, metritis, hematocele, erysipelas, uremia (carcinomatous).
96. **Ice, Cracked.**—In vomiting.
97. **Ichthyol.**—For the exanthemata seen with amenorrhea.
98. **Ichthyol.**—10% solution in water or glycerin, in vulvitis, pruritus, parametritis, hematocele.
99. **Ichthyol or Ammonium Sulpho-ichthyolate Vaseline** (Lanolin, Mollin, Glycerin).—10%, in chronic perimetritis, parametritis, oophoritis, vulvitis, hematocele; 10% with green soap, upon the abdomen for peritoneal exudate.
100. **Ichthyol in Intra-uterine Pencils.**—0.2 (gr. iij), in endometritis.
101. **Intra-uterine Pencils.**—With gum arabic and glycerin (4 cm. long, 0.2 to 0.4 cm. thick). (See Alum, Bismuth Subnitrate, Iodoform (90%); Itrol; Protargol, Ferric Chlorid Solution, Tannin, Zinc Oxid, Zinc Chlorid.) Iodoform may be added to them all.
102. **Injections.**—*Into the Bladder* (82° to 88° F.), one cup of oatmeal water with 15 to 25 drops of laudanum, in vesical spasm. Into the bladder in cystitis:  $\frac{1}{4}$  to 1 liter, 1 to 3 times daily, 90° to 95° F. (See Argent. Nitrat., Boric Acid, Cocain, Lime-water, Saline Solution, Tannin.)  
*Into the Vagina.*—Hot (115° to 130° F.), several liters 2 to 3 times daily, or every two hours in menorrhagia, metrorrhagia, myomatosis (for the hemorrhage and as an absorbent); to soften the cervix (in dilatation), in chronic indurated parametritis and perimetritis, chronic oophoritis, chronic metritis (during the menses also). They are also used when the uterus is infantile, or when it is undergoing involution. Into the vagina: 82° to 88° F., several times daily; astringents, antiseptics (carbolic acid, lysol, potassium permanganate, salicylic acid, sublimate), or emollients in beginning metritis.



Vaginal injections of brine in chronic metritis are best given in the full or sitz-bath (5 to 8 liters, 111° to 118° F.).

*Into the Uterus.*—By means of Braun's syringe (drop by drop), the two-way catheter; or permanent irrigation by means of an elastic catheter, which is held in the uterine cavity by a rubber cross-piece.

*Rectal Injections.*—(See Chloral, Glycerin, Narcotics, Saline Solution, and also Enemata.)

103. **Iodin Glycerin.**—10 : 200, upon tampons, for above affections.
104. **Iodin, Tincture.**—Applied to the abdomen, cervix, and vaginal vault in corporeal carcinoma, chronic metritis, parametritis, perimetritis, and oophoritis.
105. **Iodoform Emulsion, or Iodoform Glycerin.**—10%, in corporeal carcinoma, endometritis.  
*Iodoform Vaseline* (Lanolin, Mollin).—10 to 20%, in vulvitis, pruritus, oophoritis, parametritis, and perimetritis (upon tampons).
106. **Iodoform Gauze.**—10 to 20%, intra-uterine tamponade (for twenty-four hours), vaginal tamponade (at first, for six hours; later, from twelve to twenty-four hours), in menorrhagia, metrorrhagia, hemorrhages from myomata and carcinomata. It is also used to dilate the cervix and in endometritis.
107. **Iodoform Intra-uterine Pencils.**—90%, 4 cm. long, 0.2 to 0.4 cm. thick in acute (puerperal) and chronic endometritis. In puerperal endometritis they are to be made 6 cm. long and 0.4 to 0.6 cm. wide; in inflammations of the vulva and vagina in children, they are to be made 5 to 8 cm. long.
108. **Ipecac.**—1.0 (gr. xv) every ten minutes, until vomiting is produced. Dover's powder, 0.3 (gr. v), several times daily, in dysmenorrhea, dyspepsia.
109. **Itrol.**—Excellent dusting-powder for wounds and ulcers; 1 : 4000 to 5000 for intra-uterine and vaginal irrigation. It is also used as a bougie (3% to 10%) and as a salve (3% to 10%) in sepsis (instead of blue ointment).
110. **Krameria Ext.**—4 : 50, upon tampons, in vaginitis; it is not painfully astringent. It is also used in intestinal catarrh.
111. **Lactophenin.**—0.5 to 1.0 (gr. viij to gr. xv), several times daily (with 0.1—gr. iss—cafein), in neuralgia.
112. **Laminaria.**—As intra-uterine tamponade, in metrorrhagia, menorrhagia, to dilate the cervix. They are to be previously carefully disinfected for fourteen days in 5% carbolic acid solution, 10% iodoform-ether, or 1% corrosive sublimate alcohol. They are left *in situ* twenty-four hours.
113. **Largin.**—Specific for gonorrhea; used like protargol. (See p. 99.)

114. **Lassar's Paste** = Sulph. prec. 50.0 ( $\frac{3}{4}$  iss) with  $\beta$ -naphthol 10.0 ( $\frac{3}{4}$  iiss) and lanolin, saponis viridis, aa 25.0 ( $\frac{3}{4}$  viss). This is to be rubbed into a smooth paste. It is applied for acne.
115. **Laxatives (in the Order of Their Efficiency).**—Enemata (see the same), senna infusion by the rectum; calcined magnesia, with or without sulphur; citrate of magnesia; compound licorice powder; castor oil; decoctions of frangula; wine of cascara sagrada; calomel; tamarind (Grillon); Carlsbad salts; tincture of cascara sagrada; various waters, such as Kissingen, Friedrichshall, Carlsbad, etc.; powdered rhubarb with aloes; infusion of senna; compound extract of colocynth by the mouth. Dietetic: Fruit (boiled), kefir, whey, buttermilk, in chronic perimetritis, dysmenorrhea, oophoritis, metritis, and parametritis.
116. **Lead Acetate.**—One teaspoonful to one cup of water = lead-water (2 to 5 teaspoonfuls to a liter of lukewarm water), in pruritus, vulvitis, vaginitis, erysipelas.
117. **Lime-water.**—Used in full strength, for irrigation in cystitis; or 25.0 in 500.0 milk internally.
118. **Linseed Decoctions.**—In vaginitis, cystitis, acute endometritis, and metritis.
119. **Magnesia, Calcined.**—1.0 to 2.0 (gr. xv to gr. xxx), 1 to 3 times daily, as a laxative.
120. **Massage.**—In oligomenorrhea, infantile uterus, chronic parametritis and perimetritis, ovarian adhesions.
121. **Menthol Spirit.**—5% in pruritus of the vulva, urticaria, and pruriginous exanthemata the result of amenorrhea.
122. **Mercuric Chlorid.**—1 : 2000, intra-uterine injection, in multiple recurring uterine polypi, endometritis; 1 : 5000, in urethritis.
123. **Mercuric Chlorid.**—1 to 2 : 1000, in vulvitis, pruritus.
124. **Mercuric Chlorid.**— $\frac{1}{4}$  to 1 : 1000, in vaginitis.
125. **Mercurous Nitrate.**—Caustic for catarrh of the cervix.
126. **Morphin Hydrochlorate.**—0.2 to 10.0 (gr. iij to f $\frac{3}{4}$  iiss) aq. dest.,  $\frac{1}{4}$  to  $\frac{1}{2}$  to 1 syringeful hypodermically = 0.005 to 0.01 to 0.02 (gr.  $\frac{1}{12}$  to  $\frac{1}{6}$  to  $\frac{1}{3}$ ) morphin hydrochlorate, in vesical spasm, carcinoma.
127. **Morphin Hydrochlorate (Powder).**—0.01 (gr.  $\frac{1}{100}$ ) with sacch. alb. 0.5 (gr. viij), in menstrual molimina, dysmenorrhea, uterine neuralgia, vesical spasm, and as a hypnotic in carcinoma.
128. **Morphin Suppositories (Rectal or Vaginal).**—0.02 (gr.  $\frac{1}{50}$ ) with 2.5 (gr. xxxviij), cacao-butter, for same affections as the preceding.
129. **Morphin Vaseline (Lanolin, Mollin).**—1.0 to 2.0 (gr. xv to gr. xxx) : 50.0 ( $\frac{3}{4}$  iss) in pruritus.

130. **Narcotics (in the Order of Their Efficiency).**—Hyoscyamus (with chloroform) as an injection; ext. belladonna, in rectal or vaginal suppositories; cocain, to be administered in the same manner; laudanum, by the rectum; chloral (+ potassium bromid), by the rectum; antipyrin, by the mouth or rectum; morphin, by the mouth, by the rectum, or hypodermically. Hypnotics: Sulphonal, trional, potassium bromid, codein, chloral, morphin.
131. **Nosophen.**—Antiseptic and desiccating dusting-powder for wounds.
132. **Oak-bark Decoctions.**—10 to 20 : 250, in vaginal inversion, vaginitis.
133. **Oatmeal Water.**—(See under Injections into the Bladder in Cystitis; and under Injections into the Vagina in Vaginitis, Acute Endometritis, and Myometritis.)
134. **Obesity Cures.**—Banting, Oertel, Epstein, Mendelsohn; used when the panniculus adiposus is excessively developed—a cause of menorrhagia.
135. **Oleum Ricini.**—2 to 3 capsules, one tablespoonful several times daily.
136. **Oophorin.**—For menstrual molimina; after removal of the ovaries.
137. **Opium.**—Laudanum, 15 to 25 drops, by the rectum or upon vaginal tampons in menstrual molimina, dysmenorrhea, oophoritis, metritis, parametritis, perimetritis, carcinoma, hematocele, peritonitis.  
Opium: Extract of opium 0.2 (gr. iij) with emuls. amygd. dulc. 150.0 (f  $\frac{3}{4}$  v), one tablespoonful every two hours (mixture only keeps a day!), in carcinoma, intestinal catarrh, acute metritis, pelvic peritonitis.
138. **Phenacetin.**—0.5 to 1.0 (gr. viij to gr. xv) t. i. d., for neuralgia.
139. **Potassium Bromid.**—In powder (1.0—gr. xv—once or twice daily) or solution (15 : 175, 2 to 4 tablespoonfuls daily), in nocturnal enuresis, uterine neuralgia, dysmenorrhea, oophoritis, hysteria, pruritus.
140. **Potassium Carbonate Solution.**—In folliculitis of the vulva; 1% solution for boiling instruments.
141. **Potassium Iodid.**—In vaginal suppositories, 0.2 to 0.5 (gr. iij to gr. viij), with 3.0 (gr. xlv) cacao-butter, in parametritis, perimetritis, metritis, uterine and vaginal inversion, oophoritis, hematocele.
142. **Potassium Iodid-glycerin.**—10 to 15 : 200, upon tampons (may add 15 to 20 drops of laudanum), for the affections just mentioned above.


143. **Potassium Iodid=vaselin** (Lanolin, Mollin).—3 to 10% in pruritis, vaginismus, acute (puerperal) metritis, and parametritis.
144. **Potassium Permanganate**.—Dark cherry-red solution, as an irrigation fluid in foul carcinomata. Given as an emmenagog, in pill form (0.5—gr. viij—in a pill, 2 or 3 pills thrice daily).
145. **Protargol**.—0.5 to 2.5 (or even 5)%, intra-uterine irrigation; 5%, vaginal irrigation; 1 to 2.5%, vesical irrigation. Protargol with glycerin or salve, 5 to 10% intra-uterine (or as a bougie), in urethritis. Used in vaginal tamponade. *It is a specific for gonorrhea (Neisser).*
146. **Quinin, Compound Tincture**.—20 drops to a half-teaspoonful, thrice daily, in anemia, uremia, dyspepsia.
147. **Quinin-iodin**.—Dusting-powder, in foul carcinomata.
148. **Rhubarb, Infusion of Root**.—5.0 to 15.0 : 180.0 (gr. lxxv to f ʒ iv : f ʒ vj) with sulphate of sodium 10.0 (gr. iiss) and elæosacch. menth. piperit., 5.0 (gr. lxxv), 2 tablespoonfuls every two hours as a laxative.
149. **Rhubarb, Powdered Root**.—Used as a laxative.
150. **Sagrada, Wine**.—½ teaspoonful, as a laxative.
151. **Saline Infusion**.—0.6%, NaCl solution, ½ to 1 liter (sometimes more), intravenous or subcutaneous injections.
152. **Saline Solution**.—5%, in cystitis, especially after injections of silver nitrate.
153. **Salol**.—1.0 to 2.0 (gr. xv to xxx), 3 or 4 times daily, in cystitis.
154. **Santonin**.—Troches or pills, 0.025 to 0.05 to 0.1 (gr. ⅜ to ¾ to iss), 3 times daily, with laxatives to prevent xanthuria; as an emmenagog and anthelmintic.
155. **Secale Cornut., Aqueous Extract**.—15.0 : 175.0 (ʒ iv : ʒ vss) with dilute sulphuric acid 2.5 (gr. xxxviiij) and tinct. cinnamomi 15.0 (ʒ iv); 1 tablespoonful every fifteen minutes, for acute hemorrhage.
156. **Secale Cornut., Extract**.—With pulv. secale cornut., āā 2.0 (gr. xxx). Ft. in pil. No. xxx—1 pill every two or three hours, in conditions mentioned above.
157. **Secale Cornut., Ext. Aqueous**.—2 to 4 : 180 (ʒ ss to ʒ j : f ʒ vj) aquæ with syr. cinnamomi 30.0 (f ʒ j); 1 tablespoonful every two hours, in conditions mentioned above and in paralysis of the vesical sphincter.
158. **Secale Cornut. Pulv.**—In vesical or uterine hemorrhage, in metritis (chronic hyperemia), and after reduction of an inverted uterus.



159. **Sennæ Fol., Infusum.**—2 to 4 teaspoonfuls (with 1 teaspoonful of fennel) to 1 cup of water, as a laxative.
160. **Sinapisms.**—Mustard plasters and analogous applications; cantharidal plasters; or two parts of cantharides, dissolved in sulphuric ether, to one part of a solution of gutta percha in chloroform, to be applied to the cervix! Tincture of iodine is also applied to the cervix. It is painted upon the abdomen in dysmenorrhea, and upon the thigh in amenorrhea.
161. **Sodium Salicylate.**—With sacch.,  $\text{ãã}$  0.5 (gr. viij); 1 powder every two hours, or in solution 0.5 : 150.0 (gr. viij : f  $\frac{3}{4}$  v), in neuroses, cystitis, erythemata.
162. **Strychnin.**—0.005 to 0.0075 to 0.01 (gr.  $\frac{1}{13}$  to  $\frac{1}{9}$  to  $\frac{1}{6}$ ) subcutaneously, in vesical paralysis.
163. **Stypticin.**—0.05 (gr.  $\frac{3}{4}$ ) (6 to 8 tablets daily), or 1 : 20 aq. cinnamomi (30 drops 5 times daily), or 1 or 2 syringefuls of a 10% solution subcutaneously.
164. **Sulphonal.**—1.0, as a somnifacient.
165. **Sulphur.**—2 teaspoonfuls daily; precipitated sulphur, powdered rhubarb root, compound licorice powder,  $\text{ãã}$  7.5 ( $\frac{3}{4}$  ij), as a laxative.
166. **Suppositories (Rectal).**—2.5 to 3.0 (gr. xxxviii to xlv) cacao-butter. (See Morphin, 0.01 to 0.02 (gr.  $\frac{1}{6}$  to  $\frac{1}{3}$ ); Ext. Belladonna, 0.01 to 0.02 (gr.  $\frac{1}{6}$  to  $\frac{1}{3}$ ); Chloral, 0.5 (gr. viij); Cocain Hydrochlorate, 0.1 (gr. iss).)
167. **Suppositories (Vaginal).**—2.5 to 3.0 (gr. xxxviii to xlv) cacao-butter. (See Morphin, 0.02 (gr.  $\frac{1}{3}$ ); Ext. Bellad., 0.02 to 0.03 (gr.  $\frac{1}{3}$  to  $\frac{1}{2}$ ); Chloral, 0.5 (gr. viij); Cocain Hydrochlorate, 0.1 (gr. iss); Potassium Iodid, 0.2 (gr. iij); Tannic Acid, 0.4 (gr. vj).)
168. **Tamarind Decoction.**—8.0 to 50.0 : 100.0 to 300.0 ( $\frac{3}{4}$  ij to  $\frac{3}{4}$  iss : f  $\frac{3}{4}$  iiss to f  $\frac{3}{4}$  x) aquæ at one dose, as a laxative. It is also administered in the form of tamarind paste (Grillon).
169. **Tampons.**—Glycerin (in vaginal inversion), vaselin, lanolin, or mollin with tannin, alum, ichthyol, potassium iodid, chloroform with oil of hyoseyamus, cupric sulphate, zinc chlorid or sulphate.
170. **Tannin Solution.**—0.5 to 1.0 : 100.0 (gr. viij to gr. xv : f  $\frac{3}{4}$  iiss), in cystitis.
171. **Tannin Solution.**—2 to 4%, in vaginitis, vaginal inversion, vulvitis.
172. **Tannin Vaseline** (Glycerin, Lanolin, Mollin).—2 to 4 : 50.0 ( $\frac{3}{4}$  ss to  $\frac{3}{4}$  j :  $\frac{3}{4}$  iss), for the above-mentioned affections.
173. **Trional.**—0.5 (gr. viij), in powder, as a somnifacient.
174. **Ung. Hydrarg. Ammoniati.**—For pruritus.

175. **Ung. Zinci Oxidi.**—For eczema, herpes.
176. **Ung. Zinci Oxidi.**—With amyli  $\bar{a}\bar{a}$  50.0 ( $\bar{3}$  iss) and acid. salicyl. 3.0 (gr. xlv) and vaselin (lanolin, mollin), 100.0 ( $\bar{3}$  iiiss), for pruritus, wounds.
177. **Urotropin.**—0.5 (gr. viij), 3 times daily, as a diuretic.
178. **Viburnum Prunifol., Ext. Fld.**—1.0 to 4.0 (gr. xv to  $\bar{3}$ j) several times daily, as an antispasmodic in dysmenorrhea, threatened abortion; 1 teaspoonful may be given several times daily for one or two weeks.
179. **Washing with Cool Water.**—For nocturnal enuresis.
180. **Weir Mitchell Rest-cure.**—For nervous anemic patients.
181. **Zinc Chlorid.**—5% intra-uterine pencil held in position by a tampon, for endometritis (three days rest in bed).
182. **Zinc Chlorid.**—10 to 50% solution, for intra-uterine application (once a week) after dilatation of the cervix in endometritis; 5 to 10% injection, for multiple recurrent sessile polypi.
183. **Zinc Chlorid.**— $\frac{1}{2}$  to 1% injection or upon tampons in vaginitis, vaginal inversion.
184. **Zinc Oxid Intra-uterine Pencils.**—0.3 (gr. v), in endometritis.
185. **Zinc Oxid.**—2 : 40 pulv. amyli, for intertrigo.





# INDEX.

## A.

Abdominal pregnancy, 221  
 Absence of entire genital tract, 19  
   of uterus and adnexa, 18  
   of vagina, 29  
 Acne in amenorrhea, 39, 41  
 Adenomyomata, 193  
 Adnexa, benign tumors of, 199  
   diagnosis, 200  
   symptoms, 200  
   treatment, 201  
   malignant tumors of, 245  
     diagnosis, 245  
     symptoms, 245  
     treatment, 246  
 Alexander's operation, 88  
 Amenorrhea, 39  
   physiologic, 40  
   symptomatic, 39  
   treatment, 41  
 Angiosarcomata, 234  
 Anomalies of formation, fetal, 17  
   hyperplastic, 29  
   infantile, 35  
   of menstruation, 38  
 Antelexion, infantile, 36  
   puerile, 36  
 Anterior sacral hydromeningocele, 223  
 Anteversion and antelexion, 76  
   diagnosis, 76  
   etiology, 76  
   treatment, 78  
 Anus perinealis, 27  
 Aplasia, 17  
 Arrested development, 35

Ascites, 178, 227  
 Ascitic fluid, characteristics of, 178  
 Atmocausis, 115  
 Atresia ani, 22  
   vaginalis, 22, 27, 29  
   vestibularis, 27  
   hymenalis, 25, 27  
   unilateral, of duplicate genitalia, 26, 27  
   urethrae, 22  
   vulva, 22  
 Atresias, congenital, 22  
   traumatic, 155, 163  
 Azoospermism, 47

## B.

Bartholinitis, 93, 96, 99  
 Bier's constriction, 100  
 Bladder, atrophy of, 142  
   benign tumors of, 188  
   carcinoma of, 235, 236  
   catarrh of, 140  
   cysts of, 187  
   distended, 227  
   drainage of, 147  
   fibromata, fibromyomata, 187  
   hypertrophy of, 142  
   malignant tumors of, 235  
   papillomata of, 186, 188  
     diagnosis, 189  
     prognosis, 189  
     treatment, 189  
   polyps, 187  
   senile, 142  
   tuberculosis of, 137, 139

Braun's syringe, 197  
 Broad ligament, cysts of, 199  
     fibromyomata, 199  
     fibromyxomata, 199  
     lipomata, 199  
 Buboës, 139  
 Bullet-forceps, 83

## C.

Castration, 209  
 Celiosalpingectomy, 126  
 Cervical canal, diameter of, 37  
     length of, 59  
 Cervicitis, acute, 101  
     chronic, 101  
     diagnosis, 105  
     symptoms, 104  
     treatment, 106  
     purulent, 101  
 Cervix, atresia of, 27  
     catarrh of, 101  
     dilatation of, 37, 109, 163  
     tears of, 161  
     treatment, 161  
 Chancre, hard, 139  
     soft, 139  
 Chancroidal bubo, 139  
 Charcot's arch, 153  
 Chrobak's extraperitoneal  
     method, 210  
 Clitoris, duplication of, 49  
     fissa, 23  
     hypertrophy of, 49  
 Cloaca, 26  
 Coccygodynia, 154  
     treatment, 154  
 Colpeurynter, 56  
 Colpitis crouposa, 117  
     diphtheritica, 117  
     exfoliativa, 44  
     gonorrhœica, 94, 97  
     ulcerosa adhæsiva, 151  
     vetularum, 151  
 Colpocleisis, 172  
 Colpocystotomy, 183  
 Colpohyperplasia cystica, 187  
 Colpomyotomy, 208  
 Colpoperineauxesis, 68  
 Colpoperineoplasty, 68

Colpoperineorrhaphy, 68  
 Colporrhaphy, anterior, 68  
     posterior, 68  
 Condylomata, acuminate, 99, 100  
     flat, 139  
 Curetment, 110, 111  
 Cystitis, anatomy, 140  
     diagnosis, 141  
     diphtheritica, 141, 142  
     etiology, 141, 142  
     sequels, 143  
     symptoms, 141  
     treatment, 146  
 Cystocele, 53  
 Cystoscope, operative, 144  
 Cystoscopy, 144

## D.

Decidua menstrualis, 43, 44  
     vera graviditatis, 44  
 Deciduoma, 190  
 Defects of uterus, 18  
     of vagina, 22  
 Dermatitis simplex, 149  
 Descensus uteri, 57, 60  
 Diagnosis, differential, of ante-  
     uterine and retro-uterine tu-  
     mors, 224, 225  
 Dilatation of cervix, 37, 109, 163  
 Displacements of tubes and ova-  
     ries, 75  
     of uterus, 74  
 Distended bladder, 227  
 Douglas' pouch, tumors of, 221,  
     224, 225  
 Duplication by a septum, 31  
     of cervix, 32  
     of clitoris, 49  
     of entire genital tract, 29  
     of nymphæ, 49  
     of organs, 29  
     of uterine appendages, 30  
     of uterus, 30  
 Dysmenorrhea, congestive, 42  
     etiology, 42  
     in infantile antelexion, 36  
     in intramural myomata, 42  
     inflammatory, 42  
     membranacea, 43

Dysmennorrhea, obstructive, 42  
 reflex, 42  
 treatment, 43

## E.

Echinococcus cysts, 219  
 Ectopia vesicæ, 167  
 Ectropion, 104, 107  
   differential diagnosis, 105  
 Elephantiasis vulvæ, 152, 187  
 Elevatio uteri, 72  
   diagnosis, 72  
   treatment, 72  
 Elongatio colli, 61  
 Emboli after operations for myo-  
 mata, 202, 205  
 Endometritis acuta, 118  
   chronica, 100  
     diagnosis, 105  
     symptoms, 104  
     treatment, 106  
   corporis uteri, 107  
     symptoms, 108  
     treatment, 109  
   dissecans, 108  
   exfoliativa, 44, 108  
   from stenosis, 38  
   fungosa, 108  
   glandularis, 107  
   hæmorrhagica, 108  
   interstitialis, 108  
   polyposa, 108, 185  
   post abortum, 108  
   yeast cultures, introduction of,  
     110  
 Endothelioma, 234, 244, 247  
 Enemata, Hegar's, 133, 135  
 Enterocolpocele, 50  
 Enuresis nocturna, 146  
 Episioplasty, 159  
 Epispadias, feminine, 23, 29  
 Epithelioma, 185, 234  
 Erosion, differential diagnosis,  
   105  
   follicular, 105  
   papillary, 105  
     differential diagnosis from  
       cancer, 234  
   simple, 105

Eversio vesicæ, 167  
 Evolutio præcox, 39  
 Exanthemata, periodic, 149  
   vulvar, 149  
 Excisions, wedge-shaped, 107, 116  
 Exfoliatio mucosæ menstrualis, 43  
   diagnosis, 44  
 Exstrophia vesicæ, 167  
 Extra-uterine pregnancy, 176  
 Exudates, parametritic, 135  
   perimetritic, 132

## F.

Facies ovarica, 200  
 Fallopian tube, cysts of, 199  
   fibromata, fibromiomata, 199  
   hydatids of, 199  
   lipomata of, 199  
   papillary proliferations of,  
     199  
 Faradization for cervical stenosis,  
   37  
 Ferripyrin, 46  
 Fibroma of ovary, 208, 211, 221  
 Fibromyomata, cervical, 199  
   "delivery" of, 196  
   diagnosis, 196, 206  
   enucleation of, 209  
   etiology, 191  
   histoid, 192  
   indications for operation, 209  
   intercorporeal, 194  
   intraligamentous, 194  
   intramural, 194  
   organoid, 193  
   polypoid submucous, 194  
     subserous, 194  
   sarcomatous changes in, 207  
   sequels of, 202  
   submucous, 194  
   subserous, 194  
   symptoms, 195, 205  
   torsion of pedicle, 202  
   treatment, 197, 208  
 Fibrosarcoma, 207  
 Fissura vesicæ inferior, 167  
   superior, 167  
 Fistula, cauterizations for, 173  
   congenital, 22

- Fistula, ileo-ureterovesical, 168  
   ileovaginal, 168, 173  
   ileovesical, 168  
   intestinal, 168  
   operations for, 172  
   rectohymenalis, 23  
   recto-ureterovesical, 168  
   rectovaginal, 168, 171  
   rectovesical, 168  
   rectovestibularis, 23  
   ureterocervical, 167  
   urethrovaginal, 165, 170  
   urinary, 165  
     after-treatment, 173  
     diagnosis, 171  
     symptoms, 170  
     treatment, 172  
   vesico-abdominal, 167  
   vesicocervical, 166  
   vesicocervicovaginal, 165, 166  
   vesico-umbilicalis, 167  
   vesico-ureterovaginal, 166, 171  
   vesicovaginal, 165, 170  
 Floating kidney, 223  
 Folliculitis vulvæ, 150  
 Foreign bodies in bladder, 180  
   treatment, 180  
   in genital tract, 180  
   treatment, 180  
 Fritsch's operation, 159  
 Furunculosis vulvæ, 149

## G.

- Garrulitas vulvæ, 158  
 Gärtner's ducts, 200  
 Genital canal, duplications of, 29  
   tuberculosis, diagnosis, 137  
     histology, 136  
     prognosis, 138  
     symptoms, 137  
     treatment, 138  
 Gonococci, 94, 97  
 Gonorrhea, 93  
   diagnosis, 97  
   latent, 95  
   symptoms, 96  
   treatment, 97  
 Gonorrheal endometritis, 95  
   mixed infection, 96

- Gonorrheal peritonitis, 96  
   pyosalpinx, 95  
   urethritis, 99  
 Gummata, 140

## H.

- Hegar's castration, 211  
   enemata, 133, 135  
   funnel, 99, 147  
   operations, 116, 159, 211  
 Hematocele, intraperitoneal retro-  
   uterine, 176, 221, 224  
   diagnosis, 177  
   etiology, 176  
   prognosis, 179  
   symptoms, 177  
   treatment, 179  
 Hematocolpos, 25  
 Hematoma, extraperitoneal, 175  
   vaginæ, 26  
   vulvæ, 26, 175  
 Hematometra, 25, 163, 164, 220  
 Hematosalpinx, 25, 220  
 Hermaphroditism, 20  
 Hernia, diagnosis, 48  
   inguinalis labialis, 48  
   treatment, 49  
   vaginalis labialis, 48  
 Hot sand-baths, 135  
 Hydatids, formation of, 199  
 Hydrocolpocele, 50  
   treatment, 52  
 Hydromeningocele sacralis ante-  
   rior, 223  
 Hydrometra, 163  
 Hydronephrosis, 219, 223  
 Hydrops folliculorum, 211  
 Hydrosalpinx, 124  
 Hymen bifenestratus, 33  
   septus, 33  
 Hyperinvolution, puerperal, 40,  
   134  
 Hyperplasias, 29  
 Hypertrophy of bladder, 142  
 Hypoplasia, 17  
 Hypospadias, feminine, 22, 27, 29  
 Hysterical symptom-complex, 153  
 Hysteroceleisis, 172  
 Hysterotrachelorrhaphy, 162

## I.

- Ileovaginal preternatural anus, 169
- Impotentia coëundi, 46
- Impressio fundi uteri, 54, 55
- Incontinence, fecal, 157
  - of retention, 145
  - urinary, 145
  - vulvar, 155, 158
- Inflammation, etiology, 93
  - glandular, 92
  - interstitial, 92
  - terminations, 93
- Intermenstrual pain, 109
- Intertrigo, 158
- Intestinal fistula, 168
- Inversion of anterior vaginal wall, 53
  - treatment, 53
- of posterior vaginal wall, 52
  - treatment, 53
- of uterus, complete, 55
  - diagnosis, 55
  - etiology, 54
  - partial, 54
  - symptoms, 55
  - treatment, 55
- of vagina, 50
  - diagnosis, 52
  - treatment, 52
- Ischuria paradoxa, 145

## K.

- Kehrer's operations, 37, 57, 116
- Küstner's operation, 57
  - urethral funnel, 99, 147

## L.

- Lacerations, 154, 157, 158
- Laminaria, 109
- Lochiometra, 163
- Lupus vulvæ, 137

## M.

- Mackenrodt's operation, 172
- Martin's operation, 68, 89

- Massage, 90
- Masturbation, 42, 93, 101, 151
- Menorrhagia, etiology, 45
  - treatment, 45
- Menstrualis, decidua, 43, 44
  - exfoliatio mucosæ, 43, 44
- Menstruation, disturbances of, 39
  - physiologic, 33
  - vicarious, 41
- Metalbumin, 218
- Meteorism, 227
- Method of Schultze, 216, 226
- Metritis, acute, 118
  - diagnosis, 120
  - symptoms, 119
  - treatment, 123
- chronic, 111
  - diagnosis, 113
  - etiology, 113
  - prognosis, 113
  - symptoms, 113
  - treatment, 114
- Metrorrhagia, 195, 205
- Molimina menstrualia, 20
- Mollusca, 195
- Morphinism as a cause of amenorrhea, 39, 40
- Müllerian ducts, 17, 25, 26, 32
- Myomata, cervical, 207
  - intraligamentous, 207, 221
  - vascular bruit in, 208
- Myometritis, 109, 120
- Myomotomy, 209
- Myxedema, peritoneal, 213
- Myxofibroma ovarii, 198
- Myxosarcoma, 204, 222

## N.

- Nervous symptoms in retroflexion, 81
- Neuralgia in laceration scars, 158
  - in uterine and ovarian tumors, 195, 198, 201
  - lumbo-abdominal, 154
  - uteri, 42
- Neuritis in carcinoma, 237
- Neuroses in amenorrhea, 39
  - of the vagina, 143, 150
  - periodic, 41



New growths, etiology of, 134  
Nymphæ, duplication of, 49

## O.

Oligocystic degeneration, 128  
Oligomenorrhea, etiology, 39  
treatment, 40  
Oophoritis, acute, 119, 222  
chronic, 126  
diagnosis, 128  
etiology, 126  
symptoms, 128  
treatment, 129  
Oophorosalingitis, 127  
Operation, Alexander's, 88  
Fritsch's, 159  
Hegar's, 116, 159  
Kehrer's, 37, 57, 116  
Küstner's, 57  
Mackenrodt's, 172  
Martin's, 63, 89  
Martin's (A.), 116  
Schröder's, 116  
Simon's, 116, 159  
Sims', 37, 116, 164  
Skutsch's, 89  
v. Winckel's, 163  
Ovarian cystomata, anatomy, 211  
character of contents, 218  
definition, 211  
diagnosis, 216, 219  
histology, 211  
multilocular, 211  
prognosis, 227  
sequels, 213  
symptoms, 213  
tapping, 228  
torsion of pedicle, 227  
treatment, 227  
unilocular, 211  
Ovarica, facies, 200  
Ovarie, 154  
Ovariocolpocele, 50, 75  
Ovary, abscess of, 127  
atrophy of, 127  
dermoid cyst of, 213  
fibroma of, 199, 221  
fibromyomata of, 199, 221

Ovary, multilocular glandular  
mucoid cysts of, 211  
oligocystic degeneration of, 128  
papillary proliferative cysts of,  
213, 216  
presence of third, 34  
racemose cysts of, 213  
unilocular cysts of, 211  
Ovulation, 38  
Ovules of Naboth, 108

## P.

Pancreas, cysts of, 226  
Papillary vulvitis, 149  
Paracolpitis, acute, 117  
chronic, 134  
Paralbumin, 218  
Parametritis, acute, 120, 123  
chronic, 134  
atrophic, 134  
symptoms, 135  
treatment, 135  
diagnosis, 134  
etiology, 134  
symptoms, 134  
treatment, 135  
exudates of, 121, 223  
Paraproctitis, 117  
Paroophoritic adenomyomata,  
195, 199  
cysts, 200  
Parovarian cysts, 200, 201, 219,  
221  
Péan-Hegar's extraperitoneal  
method, 210  
Pelvic peritonitis, diagnosis, 132  
etiology, 131  
prognosis, 131  
symptoms, 131  
treatment, 132  
Pelvis fissa, 23  
Pericystitis, 131  
Perimetritis, chronic, 131  
exudates of, 132  
Perimetro-oophoritis, 96  
Perimetrosalpingitis, 96  
serosa, 131  
Perineal defects, congenital, 29  
lacerations, etiology of, 156

- Perineal lacerations, operations  
     for, 159  
     sequels, 157  
     symptoms, 157  
     treatment, 159  
   perforation, 156  
 Perineoplasty, 159  
 Perineorrhaphy, 159, 160  
 Periproctitis, 131  
 Peritoneal myxedema, 213  
 Peritonitis, acute, 119, 231  
     exudativa saccata, 119  
     gonorrheal, 133  
     pelvic, 131, 132  
     sacculated, 233  
     tubercular, 133, 138  
 Pessaries, application of, 84, 89  
     care of, 87  
     disadvantages of, 87  
     intra-uterine, 37, 38  
     lever-, 71, 84  
 Pessary, Breisky's, 71  
     Hewitt's, 71  
     Hodge's, 71, 84, 85  
     Mayer's ring, 70, 84  
     Schultze's 8-shaped, 71, 84, 85  
     sledge-, of B. S. Schultze, 71  
       reversed application of, 90  
     Zängerle-Martin stem-, 71  
 Phlebectasia, vulvar, 151  
 Phlegmone vaginæ, 117  
     vulvæ, 117, 149  
 Placenta, retention of, 239  
 Playfair's aluminum sound, 195, 199  
 Pregnancy, abdominal, 221  
     diagnosis of, 219  
 Prolapse, vaginal and uterine, 57  
     complete, 57  
     development, 60  
     diagnosis, 63  
     etiology, 62  
     partial, 57  
     reposition, 71  
     symptoms, 61  
     treatment, 64-74  
 Propeptone, 218  
 Pruritis vulvæ, 149, 150  
 Pseudohermaphroditism, 20  
 Pseudomucin, 218  
 Pulmonary emboli, 202, 205  
 Pyocolpocoele, 50, 75  
     treatment, 52  
 Pyocolpometa, 29  
 Pyometra, 163  
 Pyo-oophorosalphinx, 127  
 Pyosalpinx, 125, 126
- R.
- Rectal injections, Hegar's, 133, 135  
 Rectocoele, 52  
 Reposition of prolapsed uterus, 71  
 Retained catheter, 147, 174  
 Retention of urine, 145  
 Retrofixatio colli, 89  
 Retroflexion, puerile, 79  
 Retroversion and retroflexion,  
     congenital, 79  
     diagnosis, 82  
     etiology, 79  
     reposition, 90  
     symptoms, 81  
     treatment, 83  
 Rhagades, 157  
 Rose's procedure, 181  
 Round ligament, adenomyomata  
     of, 199  
     fibromyomata of, 199  
 Rudimentary cornua of the uterus, 26
- S.
- Salpingitis, acute catarrhal parenchymatous, 125  
     purulent catarrhal and interstitial, 125  
     chronic catarrhal parenchymatous, 124  
     interstitial, 126  
     diagnosis, 125  
     nodosa, 199  
     symptoms, 125  
     treatment, 125  
 Sarcoma of uterus, 222, 243  
     of vagina, 235  
     of vulva, 235

- Schröder's intraperitoneal method, 210  
 Sectio alta, 183  
 Senna infusion, 231  
 Sepsis, 117  
 Simon's operation, 116, 159  
   specula, 32, 147  
 Sims' operation, 37, 116, 164  
   position, 32  
 Singultus hystericus, 153  
 Sinus urogenitalis, 27  
 Skene's glands, 31  
 Stem-pessary in ante flexion, 37  
 Stenosis, congenital, of cervix, 36  
   hymenalis, 38  
   traumatic, 162  
     anatomy, 163  
     diagnosis, 163  
     etiology, 163  
     symptoms, 163  
     treatment, 163  
   vulvovaginalis, 38  
 Sterility, etiology, 46  
   examination of patient, 47  
   following gonorrhea, 96  
   in ante flexion, 77  
   in infantile ante flexion, 36  
   in uterine prolapse, 62  
   treatment, 47  
   with bilateral ovarian cyst, 200  
 Subinvolution as a cause of metritis, 93  
   as a cause of prolapse, 62  
 Suprapubic cystotomy, 183  
 Supravaginal amputation, 209  
 Suspensio uteri, 89

## T.

- Tamponade of pouch of Douglas, 138  
 Tapping, 228  
 Tenesmus, rectal, 53, 78  
   vesical, 146  
 Tertiary syphilides, 140  
 Torsion of uterus, pathologic, 91  
   physiologic, 91  
 Transmigratio seminis, 22  
 Traumatic effusions, 175

- Tube. See *Fallopian tube*.  
 Tubercular peritonitis, 133, 138  
   tumors of omentum, 226  
 Tuberculosis, genital, 136, 137  
   peritoneal, 139  
   vesical, 137, 139  
 Tumors, benign, 186  
   conditions simulating, 227  
   etiology of, 184  
   intraligamentous, 199  
   malignant, 234  
   of abdominal walls, 226  
   of bladder, 186, 187, 188, 235  
   of Fallopian tube, 199  
   of kidney, 223  
   of ligaments, 199  
   of omentum, 226  
   of ovary, 199  
   of parietal peritoneum, 226  
   of pelvic bones, 223  
   of pouch of Douglas, 221, 224  
   of rectum, 223  
   of tube, 199

## U.

- Ulcer, cervical, 120  
   vaginal, 120  
   vulvar, 120  
 Uleus durum, 139  
   gangrenosum, 139  
   molle, 139  
 Uremia, 142  
   in carcinoma, 238  
 Ureters, angulation of, 60, 86  
 Urethra, carcinoma of, 236  
   caruncle of, 186  
   condylomata of, 186  
   cystic myxo-adenomata, 187  
   fibromata of, 187  
   fibromyomata of, 187  
   polyps of, 187  
   tumors of, 187  
     treatment, 188  
 Urethritis gonorrhœica, 99  
 Urinary fistula, 165  
 Urina spastica, 143  
 Urine, retention of, 145  
 Urogenital septum, 27  
   sinus, 27

Uterine asthma, 41  
 cavity, size of, 59  
 Uterus, amputatio supravaginalis, 209  
   antepositio, 73  
   anteversions and antelexions, 76-79  
   benign tumors of, 189  
   bicornis, 30  
     septus, 32, 33  
   carcinoma of, 237  
   cavity of, 59  
   diadelphus (didelphys), 29  
   duplex, 29  
   fibromyomata of, 192  
   foetalis, 35  
   infantilis, 32, 35, 38  
   latero-positio, 73  
   ligaments of, 59  
   malignant tumors of, 237, 243  
     diagnosis, 238, 245  
     symptoms, 237  
     treatment, 239, 241, 245  
   membranaceus, 35, 36  
   mucous polyps of, 190  
     diagnosis, 190  
     symptoms, 190  
     treatment, 191  
   myxosarcoma of, 222  
   normal length of, 36, 59  
   relations of, 59  
   situation of, 57  
   width of, 59  
   pathologic positions, 73  
   retropositio, 73  
   retroversions and retroflexions, 79-91  
   sarcoma of, 222, 243  
   supports of, 59  
   total extirpation of, 209  
   tuberculosis of, 137  
   unicornis, 20

## V.

Vagina, atresia of, 22, 27, 29  
 cysts of, 187  
   treatment of, 187  
 duplex, 29  
 epitheliomata of, 235

Vagina, fibromata of, 187  
 fibromyomata of, 187  
 inversion of, 50, 52, 53  
 lacerations of, 160  
   symptoms, 161  
   treatment, 161  
 myxofibroma, 187  
 neuroses of, 143, 150  
 phlegmon of, 117  
 sarcoma of, 235  
 septa, 33  
 subseptae, 33  
 tuberculosis of, 137, 138  
 ulcers of, 120  
 Vaginismus, 38, 150  
   etiology, 151  
   treatment, 151  
 Vaginitis, acute, 110  
   gonorrheal, 94, 97  
 Vagino-fixation, 67, 89  
 Varicocele parovarialis, 151  
 Venereal diseases, 139  
 Ventrofixation, 67, 89  
 Vesical calculi, diagnosis, 181  
   etiology, 181  
   symptoms, 181  
   treatment, 183  
 irrigations, 147  
 paralysis, 145  
   diagnosis, 146  
   symptoms, 146  
   treatment, 148  
 spasm, 143  
   diagnosis, 144  
   symptoms, 143  
   treatment, 148  
   tuberculosis, 137, 139  
 Vesicofixation, 67  
 Vulva, condylomata of, 186  
 cysts of, 187  
 duplex, 29  
 elephantiasis of, 100  
 epithelioma of, 234  
 fibromata of, 186  
 fibromyomata of, 186  
 fissures of, 155  
 folliculitis of, 149, 150  
 furunculosis of, 149  
 hematoma of, 175  
 histology of, 98

Vulva, incontinence, 155, 158  
injuries of, 155  
lipomata of, 187  
lupus of, 137  
myxofibromata of, 186  
papillomata of, 186  
sarcoma of, 235  
tuberculosis of, 137, 138  
Vulvitis diabetica, 149, 150  
gonorrheal, 98

Vulvitis, papillary, 149  
pruriginosa, 149, 150

Y.

Yeast cultures in endometritis,  
110

Z.

Zestocausis, 115



# Medical and Surgical Works

PUBLISHED BY

W. B. SAUNDERS, 925 Walnut Street, Philadelphia, Pa.

|  | PAGE |  | PAGE    |
|--|------|--|---------|
| Abbott on Transmissible Diseases . . . .                                       | 18   | Kyle's Diseases of Nose and Throat . . .                           | 18      |
| American Pocket Medical Dictionary . .   | 35   | Lainé's Temperature Charts . . . . .                               | 32      |
| *American Text-Book of Applied Therapeutics . . . . .                          | 8    | Levy & Klemperer's Clinical Bacteriology . . . . .                 | 44      |
| *American Text-Book of Dis. of Children .                                      | 13   | Lockwood's Practice of Medicine . . . .                            | 41      |
| *An American Text-Book of Diseases of the Eye, Ear, Nose, and Throat . . . . . | 15   | Long's Syllabus of Gynecology . . . . .                            | 34      |
| *An American Text-Book of Genito-Urinary and Skin Diseases . . . . .           | 14   | Macdonald's Surgical Diagnosis and Treatment . . . . .             | 22      |
| *American Text-Book of Gynecology . . .  | 12   | McFarland's Pathogenic Bacteria . . . .                            | 30      |
| *American Text-Book of Legal Medicine .  | 44   | Mallory and Wright's Pathological Technique . . . . .              | 22      |
| *American Text-Book of Obstetrics . . .  | 9    | Martin's Surgery . . . . .   | 43      |
| *American Text-Book of Pathology . . . .                                       | 44   | Martin's Minor Surgery, Bandaging, and Venereal Diseases . . . . . | 43      |
| *American Text-Book of Physiology . . .  | 7    | Meigs' Feeding in Early Infancy . . . .                            | 30      |
| *American Text-Book of Practice . . . .  | 10   | Moore's Orthopedic Surgery . . . . .                               | 23      |
| *American Text-Book of Surgery . . . . .                                       | 11   | Morris' Materia Medica and Therapeutics .                          | 43      |
| Anders' Theory and Practice of Medicine .                                      | 21   | Morris' Practice of Medicine . . . . .                             | 43      |
| Ashton's Obstetrics . . . . .  | 43   | Morten's Nurses' Dictionary . . . . .                              | 38      |
| Atlas of Skin Diseases . . . . .   | 28   | Nancrede's Anatomy and Dissection . . .                            | 31      |
| Ball's Bacteriology . . . . .  | 43   | Nancrede's Anatomy . . . . .                                       | 43      |
| Bastin's Laboratory Exercises in Botany .                                      | 36   | Nancrede's Principles of Surgery . . . .                           | 19      |
| Beck's Surgical Asepsis . . . . .  | 41   | Norris' Syllabus of Obstetrical Lectures .                         | 37      |
| Boislinière's Obstetric Accidents . . . .                                      | 39   | Penrose's Diseases of Women . . . . .                              | 24      |
| Brockway's Physics . . . . .   | 43   | Powell's Diseases of Children . . . . .                            | 43      |
| Burr's Nervous Diseases . . . . .  | 41   | Pryor's Pelvic Inflammations . . . . .                             | 33      |
| Butler's Materia Medica and Therapeutics                                       | 24   | Pye's Bandaging and Surgical Dressing .                            | 23      |
| Cerna's Notes on the Newer Remedies . .  | 32   | Raymond's Physiology . . . . .                                     | 41      |
| Chapin's Compendium of Insanity . . . .  | 35   | Saundby's Renal and Urinary Diseases . .                           | 25      |
| Chapman's Medical Jurisprudence . . . .  | 41   | *Saunders' American Year-Book of Medicine and Surgery . . . . .    | 16      |
| Church and Peterson's Nervous and Mental Diseases . . . . .                    | 17   | Saunders' Medical Hand-Atlases . . . .                             | 3, 4, 5 |
| Clarkson's Histology . . . . .   | 33   | Saunders' Pocket Medical Formulary . .                             | 35      |
| Colten and Eshner's Diagnosis . . . . .  | 43   | Saunders' New Series of Manuals . . . .                            | 40, 41  |
| Corwin's Diagnosis of the Thorax . . . .                                       | 37   | Saunders' Series of Question Compendis .                           | 42, 43  |
| Cragin's Gynecology . . . . .  | 43   | Sayre's Practice of Pharmacy . . . . .                             | 43      |
| Crookshank's Text-Book of Bacteriology .                                       | 27   | Seiple's Pathology and Morbid Anatomy .                            | 43      |
| DaCosta's Manual of Surgery . . . . .  | 23   | Seiple's Legal Medicine and Toxicology .                           | 43      |
| De Schweinitz's Diseases of the Eye . . .                                      | 29   | Senn's Genito-Urinary Tuberculosis . . .                           | 24      |
| Dorland's Pocket Medical Dictionary . .  | 35   | Senn's Tumors . . . . .  | 25      |
| Dorland's Obstetrics . . . . .   | 41   | Senn's Syllabus of Lectures on Surgery .                           | 37      |
| Frothingham's Bacteriological Guide . .  | 30   | Shaw's Nervous Diseases and Insanity . .                           | 43      |
| Garrigues' Diseases of Women . . . . .   | 34   | Starr's Diet-Lists for Children . . . . .                          | 38      |
| Gleason's Diseases of the Ear . . . . .  | 43   | Stelwagon's Diseases of the Skin . . . .                           | 43      |
| *Gould and Pyle's Curiosities of Medicine                                      | 17   | Stengel's Pathology . . . . .                                      | 20      |
| Grafstrom's Massage . . . . .  | 28   | Stevens' Materia Medica and Therapeutics                           | 32      |
| Griffith's Care of the Baby . . . . .  | 38   | Stevens' Practice of Medicine . . . . .                            | 31      |
| Griffith's Infant's Weight Chart . . . .                                       | 39   | Stewart's Manual of Physiology . . . . .                           | 37      |
| Gross's Autobiography . . . . .  | 26   | Stewart and Lawrance's Medical Electricity . . . . .               | 43      |
| Hampton's Nursing . . . . .  | 39   | Stoney's Materia Medica for Nurses . .                             | 31      |
| Hare's Physiology . . . . .  | 43   | Stoney's Practical Points in Nursing . .                           | 27      |
| Hart's Diet in Sickness and in Health . .                                      | 36   | Sutton and Giles' Diseases of Women . .                            | 29, 41  |
| Haynes' Manual of Anatomy . . . . .  | 41   | Thomas's Diet-List and Sick-Room . . . .                           | 38      |
| Heisler's Embryology . . . . .   | 19   | Thornton's Dose-Book and Manual of Prescription-Writing . . . . .  | 41      |
| Hirst's Obstetrics . . . . .   | 20   | Van Valzah and Nisbet's Diseases of the Stomach . . . . .          | 21      |
| Hyde's Syphilis and Venereal Diseases . .                                      | 41   | Vecki's Sexual Impotence . . . . .                                 | 33      |
| International Text-Book of Surgery . . .                                       | 6    | Vierordt and Stuart's Medical Diagnosis .                          | 28      |
| Jackson's Diseases of the Eye . . . . .  | 19   | Warren's Surgical Pathology . . . . .                              | 25      |
| Jackson and Gleason's Diseases of the Eye, Nose, and Throat . . . . .          | 43   | Watson's Handbook for Nurses . . . . .                             | 26      |
| Keating's Pronouncing Dictionary . . . .                                       | 26   | Wolff's Chemistry . . . . .  | 43      |
| Keating's Life Insurance . . . . .   | 39   | Wolff's Examination of Urine . . . . .                             | 43      |
| Keen's Operation Blanks . . . . .  | 36   |  |         |
| Keen's Surgery of Typhoid Fever . . . .  | 22   |  |         |



## GENERAL INFORMATION.

---

### One Price.

One price absolutely without deviation. No discounts allowed, regardless of the number of books purchased at one time. Prices on all works have been fixed extremely low, with the view to selling them strictly net and for cash.

### Orders.

An order accompanied by remittance will receive prompt attention, books being sent to any address in the United States, by mail or express, all charges prepaid. We prefer to send books **by express** when possible.

### Cash or Credit.

To physicians of approved credit who furnish satisfactory references our books will be sent free of C. O. D. **One volume or two** on thirty days' time if credit is desired; larger purchases on monthly payment plan. See offer below.

### How to Send Money by Mail.

There are four ways by which money can be sent at our risk, namely: a post-office money order, an express money order, a bank-check (draft), and in a registered letter. Money sent in any other way is at the sender's risk. Silver should not be sent through the mail.

### Shipments.

All books, being packed in patent metal-edged boxes, necessarily reach our patrons by mail or express in excellent condition.

### Subscription Books.

Books in this catalogue marked with a star (\*) are for sale by subscription only, and may be secured by ordering them through any of our authorized travelling salesmen, or direct from the Philadelphia office: they are **not** for sale by booksellers. All other books in our catalogue can be procured of any bookseller at the advertised price, or directly from us.

### Miscellaneous Books.

We carry in stock only our own publications, but can supply the publications of other houses (except subscription books) on receipt of publisher's price.

### Latest Editions.

In every instance the latest revised edition is sent.

### Bindings.

In ordering, be careful to state the style of binding desired—Cloth, Sheep, or Half Morocco.

### Special Offer. Monthly Payment Plan.

To physicians of approved credit who furnish satisfactory references books will be sent express prepaid; terms, \$5.00 cash upon delivery of books, and monthly payments of \$5 00 thereafter until full amount is paid. Any of the publications of W. B. Saunders (100 titles to select from) may be had in this way at catalogue price, including the American Text-Book Series, the Medical Hand-Atlases, etc. All payments to be made by mail or otherwise, free of all expense to us.

# SAUNDERS' MEDICAL HAND-ATLASES.

---

THE series of books included under this title consists of authorized translations into English of the world-famous **Lehmann Medicinische Handatlanten**, which for **scientific accuracy, pictorial beauty, compactness, and cheapness** surpass any similar volumes ever published. Each volume contains from **50 to 100 colored plates**, executed by the most skilful German lithographers, besides numerous illustrations in the text. There is a full and appropriate **description**, and each book contains a condensed but adequate **outline of the subject** to which it is devoted.

In planning this series arrangements were made with representative publishers in the chief medical centers of the world for the publication of translations of the atlases into nine different languages, the lithographic plates for all being made in Germany, where work of this kind has been brought to the greatest perfection. The enormous expense of making the plates being shared by the various publishers, the cost to each one was reduced to practically one-tenth. Thus by reason of their **universal translation** and reproduction, affording international distribution, the publishers have been enabled to secure for these atlases the **best artistic and professional talent**, to produce them in the **most elegant style**, and yet to offer them at a **price heretofore unapproached in cheapness**. The great success of the undertaking is demonstrated by the fact that the volumes have already appeared in **thirteen different languages**—German, English, French, Italian, Russian, Spanish, Japanese, Dutch, Danish, Swedish, Roumanian, Bohemian, and Hungarian.

In view of the unprecedented success of these works, Mr. Saunders has contracted with the publisher of the original German edition for **one hundred thousand copies** of the atlases. In consideration of this enormous undertaking, the publisher has been enabled to prepare and furnish special additional colored plates, making the series even **handsomer and more complete** than was originally intended.

As an indication of the great practical value of the atlases and of the immense favor with which they have been received, it should be noted that the **Medical Department of the U. S. Army** has adopted the "Atlas of Operative Surgery," as its standard, and has ordered the book in large quantities for distribution to the various regiments and army posts.

The same careful and competent **editorial supervision** has been secured in the English edition as in the originals. The translations have been edited by the **leading American specialists** in the different subjects.

*(For List of Volumes in this Series, see next two pages.)*

# SAUNDERS' MEDICAL HAND-ATLASES.

## VOLUMES NOW READY.

### **Atlas and Epitome of Internal Medicine and Clinical Diagnosis.**

By DR. CHR. JAKOB, of Erlangen. Edited by AUGUSTUS A. ESHNER, M. D., Professor of Clinical Medicine, Philadelphia Polyclinic. With 68 colored plates, 64 text-illustrations, and 259 pages of text. Cloth, \$3.00 net.

"The charm of the book is its clearness, conciseness, and the accuracy and beauty of its illustrations. It deals with facts. It vividly illustrates those facts. It is a scientific work put together for ready reference."—*Brooklyn Medical Journal*.

### **Atlas of Legal Medicine.** By DR. E. R. VON HOFMANN, of Vienna. Edited by FREDERICK PETERSON, M. D., Chief of Clinic, Nervous Dept., College of Physicians and Surgeons, New York. With 120 colored figures on 56 plates, and 193 beautiful half-tone illustrations. Cloth, \$3.50 net.

"Hofmann's 'Atlas of Legal Medicine' is a unique work. This immense field finds in this book a pictorial presentation that far excels anything with which we are familiar in any other work."—*Philadelphia Medical Journal*.

### **Atlas and Epitome of Diseases of the Larynx.** By DR. L. GRUNWALD, of Munich. Edited by CHARLES P. GRAYSON, M. D., Physician-in-Charge, Throat and Nose Department, Hospital of the University of Pennsylvania. With 107 colored figures on 44 plates, 25 text-illustrations, and 103 pages of text. Cloth, \$2.50 net.

"Aided as it is by magnificently executed illustrations in color, it cannot fail of being of the greatest advantage to students, general practitioners, and expert laryngologists."—*St. Louis Medical and Surgical Journal*.

### **Atlas and Epitome of Operative Surgery.** By DR. O. ZUCKERKANDL, of Vienna. Edited by J. CHALMERS D'ACOSTA, M. D., Clinical Professor of Surgery, Jefferson Medical College, Philadelphia. With 24 colored plates, 217 text-illustrations, and 395 pages of text. Cloth, \$3.00 net.

"We know of no other work that combines such a wealth of beautiful illustrations with clearness and conciseness of language, that is so entirely abreast of the latest achievements, and so useful both for the beginner and for one who wishes to increase his knowledge of operative surgery."—*Münchener medicinische Wochenschrift*.

### **Atlas and Epitome of Syphilis and the Venereal Diseases.** By PROF. DR. FRANZ MRACEK, of Vienna. Edited by L. BOLTON BANGS, M. D., Professor of Genito-Urinary Surgery, University and Bellevue Hospital Medical College, New York. With 71 colored plates, 16 black-and-white illustrations, and 122 pages of text. Cloth, \$3.50 net.

"A glance through the book is almost like actual attendance upon a famous clinic."—*Journal of the American Medical Association*.

### **Atlas and Epitome of External Diseases of the Eye.** By DR. O. HAAB, of Zurich. Edited by G. E. DE SCHWEINITZ, M. D., Professor of Ophthalmology, Jefferson Medical College, Philadelphia. With 76 colored illustrations on 40 plates, and 228 pages of text. Cloth, \$3.00 net.

"It is always difficult to represent pathological appearances in colored plates, but this work seems to have overcome these difficulties, and the plates, with one or two exceptions, are absolutely satisfactory."—*Boston Medical and Surgical Journal*.

### **Atlas and Epitome of Skin Diseases.** By PROF. DR. FRANZ MRACEK, of Vienna. Edited by HENRY W. STELWAGON, M. D., Clinical Professor of Dermatology, Jefferson Medical College, Philadelphia. With 63 colored plates, 39 half-tone illustrations, and 200 pages of text. Cloth, \$3.50 net.

"The importance of personal inspection of cases in the study of cutaneous diseases is readily appreciated, and next to the living subjects are pictures which will show the appearance of the disease under consideration. Altogether the work will be found of very great value to the general practitioner."—*Journal of the American Medical Association*.

# SAUNDERS' MEDICAL HAND-ATLASES.

## VOLUMES IN PRESS FOR EARLY PUBLICATION.

- Atlas and Epitome of Diseases Caused by Accidents.** By DR. ED. GOLEBIEWSKI, of Berlin. Translated and edited with additions by PEARCE BAILEY, M.D., Attending Physician to the Department of Corrections and to the Almshouse and Incurable Hospitals, New York. With 40 colored plates, 143 text-illustrations, and 600 pages of text.
- Atlas and Epitome of Special Pathological Histology.** By DR. H. DÜRCK, of Munich. Edited by LUDVIG HEKTOEN, M.D., Professor of Pathology, Rush Medical College, Chicago. Two volumes, with about 120 colored plates, numerous text-illustrations, and copious text.
- Atlas and Epitome of General Pathological Histology.** With an Appendix on Patho-histological Technic. By DR. H. DÜRCK, of Munich. Edited by LUDVIG HEKTOEN, M.D., Professor of Pathology, Rush Medical College, Chicago. With 80 colored plates, numerous text-illustrations, and copious text.
- Atlas and Epitome of Gynecology.** By DR. O. SCHÄFFER, of the University of Heidelberg. With 90 colored plates, 65 text-illustrations, and 308 pages of text. Edited by RICHARD C. NORRIS, A. M., M. D., Gynecologist to the Philadelphia and the Methodist Episcopal Hospitals.

## IN PREPARATION.

- Atlas and Epitome of Orthopedic Surgery.** By DR. SCHULTESS and DR. LÜNING, of Zurich. About 100 colored illustrations.
- Atlas and Epitome of Operative Gynecology.** By DR. O. SCHÄFFER, of Heidelberg. With 40 colored plates and numerous illustrations in black and white from original paintings.
- Atlas and Epitome of Diseases of the Ear.** Edited by PROF. DR. POLITZER, of Vienna, and DR. G. BRÜHL, of Berlin. With 120 colored illustrations and about 200 pages of text.
- Atlas and Epitome of General Surgery.** Edited by DR. MARWEDEL, with the coöperation of PROF. DR. CZERNY. With about 200 colored illustrations.
- Atlas and Epitome of Psychiatry.** By DR. WILH. WEYGANDT, of Würzburg. With about 120 colored illustrations.
- Atlas and Epitome of Normal Histology.** By DR. JOHANNES SOBOTTA, of Würzburg. With 80 colored plates and numerous illustrations.
- Atlas and Epitome of Topographical Anatomy.** By PROF. DR. SCHULTZE, of Würzburg. About 100 colored illustrations and a very copious text.



\* **THE INTERNATIONAL TEXT-BOOK OF SURGERY.** In two volumes. By American and British authors. Edited by J. COLLINS WARREN, M.D., LL.D., Professor of Surgery, Harvard Medical School, Boston; Surgeon to the Massachusetts General Hospital; and A. PEARCE GOULD, M.S., F.R.C.S., Eng., Lecturer on Practical Surgery and Teacher of Operative Surgery, Middlesex Hospital Medical School; Surgeon to the Middlesex Hospital, London, England. Vol. I.—**General and Operative Surgery.**—Handsome octavo volume of 947 pages, with 458 beautiful illustrations, and 9 lithographic plates. Vol. II.—**Special or Regional Surgery.**—Handsome octavo volume of 1050 pages, with over 500 woodcuts and half-tones, and 8 lithographic plates. Prices per volume: Cloth, \$5.00 net; Half-Morocco, \$6.00 net.

### *Just Issued.*

In presenting a new work on surgery to the medical profession the publisher feels that he need offer no apology for making an addition to the list of excellent works already in existence. Modern surgery is still in the transition stage of its development. The art and science of surgery are advancing rapidly, and the number of workers is now so great and so widely spread through the whole of the civilized world that there is certainly room for another work of reference which shall be untrammelled by many of the traditions of the past, and shall at the same time present with due discrimination the results of modern progress. There is a real need among practitioners and advanced students for a work on surgery encyclopedic in scope, yet so condensed in style and arrangement that the matter usually diffused through four or five volumes shall be given in one-half the space and at a correspondingly moderate cost.

The ever-widening-field of surgery has been developed largely by special work, and this method of progress has made it practically impossible for one man to write authoritatively on the vast range of subjects embraced in a modern text-book of surgery. In order, therefore, to accomplish their object, the editors have sought the aid of men of wide experience and established reputation in the various departments of surgery.

### **CONTRIBUTORS:**

Dr. Robert W. Abbe.  
C. H. Golding Bird.  
E. H. Bradford.  
W. T. Bull.  
T. G. A. Burns.  
Herbert L. Burrell.  
R. C. Cabot.  
I. H. Cameron.  
James Cantlie.  
W. Watson Cheyne.  
William B. Clarke.  
William B. Coley.  
Edw. Treacher Collins.  
H. Holbrook Curtis.  
J. Chalmers Da Costa.  
N. P. Dandridge.  
John B. Deaver.  
J. W. Elliot.  
Harold Ernst.

Dr. Christian Fenger.  
W. H. Forwood.  
George R. Fowler.  
George W. Gay.  
A. Pearce Gould.  
J. Orne Green.  
John B. Hamilton.  
M. L. Harris.  
Fernand Henrotin.  
G. H. Makins.  
Rudolph Matas.  
Charles McBurney.  
A. J. McCosh.  
L. S. McMurtry.  
J. Ewing Mears.  
George H. Monks.  
John Murray.  
Robert W. Parker.

Dr. Rushton Parker.  
George A. Peters.  
Franz Pfaff.  
Lewis S. Pilcher.  
James J. Putnam.  
M. H. Richardson.  
A. W. Mayo Robson.  
W. L. Rodman.  
C. A. Siegfried.  
G. B. Smith.  
W. G. Spencer.  
J. Bland Sutton.  
L. McLane Tiffany.  
H. Tuholske.  
Weller Van Hook.  
James P. Warbasse.  
J. Collins Warren.  
De Forest Willard.

**\*AN AMERICAN TEXT-BOOK OF PHYSIOLOGY.** Edited by  
**WILLIAM H. HOWELL, Ph. D., M. D.,** Professor of Physiology in the  
 Johns Hopkins University, Baltimore, Md. One handsome octavo volume  
 of 1052 pages, fully illustrated. Prices: Cloth, \$6.00 net; Sheep or Half-  
 Morocco, \$7.00 net.

This work is the most notable attempt yet made in America to combine in one volume the entire subject of Human Physiology by well-known teachers who have given especial study to that part of the subject upon which they write. The completed work represents the present status of the science of Physiology, particularly from the standpoint of the student of medicine and of the medical practitioner.

The collaboration of several teachers in the preparation of an elementary text-book of physiology is unusual, the almost invariable rule heretofore having been for a single author to write the entire book. One of the advantages to be derived from this collaboration method is that the more limited literature necessary for consultation by each author has enabled him to base his elementary account upon a comprehensive knowledge of the subject assigned to him; another, and perhaps the most important, advantage is that the student gains the point of view of a number of teachers. In a measure he reaps the same benefit as would be obtained by following courses of instruction under different teachers. The different standpoints assumed, and the differences in emphasis laid upon the various lines of procedure, chemical, physical, and anatomical, should give the student a better insight into the methods of the science as it exists to-day. The work will also be found useful to many medical practitioners who may wish to keep in touch with the development of modern physiology.

#### CONTRIBUTORS:

**HENRY P. BOWDITCH, M. D.,**  
 Professor of Physiology, Harvard Medical School.

**JOHN G. CURTIS, M. D.,**  
 Professor of Physiology, Columbia University, N. Y. (College of Physicians and Surgeons).

**HENRY H. DONALDSON, Ph. D.,**  
 Head-Professor of Neurology, University of Chicago.

**W. H. HOWELL, Ph. D., M. D.,**  
 Professor of Physiology, Johns Hopkins University.

**FREDERIC S. LEE, Ph. D.,**  
 Adjunct Professor of Physiology, Columbia University, N. Y. (College of Physicians and Surgeons).

**WARREN P. LOMBARD, M. D.,**  
 Professor of Physiology, University of Michigan.

**GRAHAM LUSK, Ph. D.,**  
 Professor of Physiology, Yale Medical School.

**W. T. PORTER, M. D.,**  
 Assistant Professor of Physiology, Harvard Medical School.

**EDWARD T. REICHERT, M. D.,**  
 Professor of Physiology, University of Pennsylvania.

**HENRY SEWALL, Ph. D., M. D.,**  
 Professor of Physiology, Medical Department, University of Denver.

"We can commend it most heartily, not only to all students of physiology, but to every physician and pathologist, as a valuable and comprehensive work of reference, written by men who are of eminent authority in their own special subjects."—*London Lancet*.

"To the practitioner of medicine and to the advanced student this volume constitutes, we believe, the best exposition of the present status of the science of physiology in the English language."—*American Journal of the Medical Sciences*.



**\*AN AMERICAN TEXT-BOOK OF APPLIED THERAPEUTICS.** For the Use of Practitioners and Students. Edited by JAMES C. WILSON, M. D., Professor of the Practice of Medicine and of Clinical Medicine in the Jefferson Medical College. One handsome octavo volume of 1326 pages. Illustrated. Prices: Cloth, \$7.00 net; Sheep or Half-Morocco, \$8.00 net.

*The arrangement* of this volume has been based, so far as possible, upon modern pathologic doctrines, beginning with the intoxications, and following with infections, diseases due to internal parasites, diseases of undetermined origin, and finally the disorders of the several bodily systems—digestive, respiratory, circulatory, renal, nervous, and cutaneous. It was thought proper to include also a consideration of the disorders of pregnancy.

*The articles*, with two exceptions, are the contributions of American writers. Written from the standpoint of the practitioner, the aim of the work is to facilitate the application of knowledge to the prevention, the cure, and the alleviation of disease. The endeavor throughout has been to conform to the title of the book—Applied Therapeutics—to indicate the course of treatment to be pursued at the bedside, rather than to name a list of drugs that have been used at one time or another.

*The list of contributors* comprises the names of many who have acquired distinction as practitioners and teachers of practice, of clinical medicine, and of the specialties.

#### CONTRIBUTORS:

Dr. I. E. Atkinson, Baltimore, Md.  
Sanger Brown, Chicago, Ill.  
John B. Chapin, Philadelphia, Pa.  
William C. Dabney, Charlottesville, Va.  
John Chalmers DaCosta, Philada., Pa.  
I. N. Danforth, Chicago, Ill.  
John L. Dawson, Jr., Charleston, S. C.  
F. X. Dercum, Philadelphia, Pa.  
George Dock, Ann Arbor, Mich.  
Robert T. Edes, Jamaica Plain, Mass.  
Augustus A. Eshner, Philadelphia, Pa.  
J. T. Eskridge, Denver, Col.  
F. Forchheimer, Cincinnati, O.  
Carl Frese, Philadelphia, Pa.  
Edwin E. Graham, Philadelphia, Pa.  
John Guit  ras, Philadelphia, Pa.  
Frederick P. Henry, Philadelphia, Pa.  
Guy Hinsdale, Philadelphia, Pa.  
Orville Horwitz, Philadelphia, Pa.  
W. W. Johnston, Washington, D. C.  
Ernest Laplace, Philadelphia, Pa.  
A. Laveran, Paris, France.

Dr. James Hendrie Lloyd, Philadelphia, Pa.  
John Noland Mackenzie, Baltimore, Md.  
J. W. McLaughlin, Austin, Texas.  
A. Lawrence Mason, Boston, Mass.  
Charles K. Mills, Philadelphia, Pa.  
John K. Mitchell, Philadelphia, Pa.  
W. P. Northrup, New York City.  
William Osler, Baltimore, Md.  
Frederick A. Packard, Philadelphia, Pa.  
Theophilus Parvin, Philadelphia, Pa.  
Beaven Rake, London, England.  
E. O. Shakespeare, Philadelphia, Pa.  
Wharton Sinkler, Philadelphia, Pa.  
Louis Starr, Philadelphia, Pa.  
Henry W. Stelwagon, Philadelphia, Pa.  
James Stewart, Montreal, Canada.  
Charles G. Stockton, Buffalo, N. Y.  
James Tyson, Philadelphia, Pa.  
Victor C. Vaughan, Ann Arbor, Mich.  
James T. Whittaker, Cincinnati, O.  
J. C. Wilson, Philadelphia, Pa.

“As a work either for study or reference it will be of great value to the practitioner, as it is virtually an exposition of such clinical therapeutics as experience has taught to be of the most value. Taking it all in all, no recent publication on therapeutics can be compared with this one in practical value to the working physician.”—*Chicago Clinical Review*.

“The whole field of medicine has been well covered. The work is thoroughly practical, and while it is intended for practitioners and students, it is a better book for the general practitioner than for the student. The young practitioner especially will find it extremely suggestive and helpful.”—*The Indian Lancet*.

\* **AN AMERICAN TEXT-BOOK OF OBSTETRICS.** Edited by RICHARD C. NORRIS, M. D.; Art Editor, ROBERT L. DICKINSON, M. D. One handsome octavo volume of over 1000 pages, with nearly 900 colored and half-tone illustrations. Prices: Cloth, \$7.00 net; Sheep or Half Morocco, \$8.00 net.

The advent of each successive volume of the *series* of the AMERICAN TEXT-BOOKS has been signalized by the most flattering comment from both the Press and the Profession. The high consideration received by these text-books, and their attainment to an authoritative position in current medical literature, have been matters of deep *international* interest, which finds its fullest expression in the demand for these publications from all parts of the civilized world.

In the preparation of the "AMERICAN TEXT-BOOK OF OBSTETRICS" the editor has called to his aid proficient collaborators whose professional prominence entitles them to recognition, and whose disquisitions exemplify **Practical Obstetrics**. While these writers were each assigned special themes for discussion, the correlation of the subject-matter is, nevertheless, such as ensures logical connection in treatment, the deductions of which thoroughly represent the latest advances in the science, and which elucidate *the best modern methods of procedure*.

The more conspicuous feature of the treatise is its wealth of illustrative matter. The production of the illustrations had been in progress for several years, under the personal supervision of Robert L. Dickinson, M. D., to whose artistic judgment and professional experience is due the **most sumptuously illustrated work of the period**. By means of the photographic art, combined with the skill of the artist and draughtsman, conventional illustration is superseded by rational methods of delineation.

Furthermore, the volume is a revelation as to the possibilities that may be reached in mechanical execution, through the unsparing hand of its publisher.

#### CONTRIBUTORS:

Dr. James C. Cameron.  
Edward P. Davis.  
Robert L. Dickinson.  
Charles Warrington Earle.  
James H. Etheridge.  
Henry J. Garrigues.  
Barton Cooke Hirst.  
Charles Jewett.

Dr. Howard A. Kelly.  
Richard C. Norris.  
Chauncey D. Palmer.  
Theophilus Parvin.  
George A. Piersol.  
Edward Reynolds.  
Henry Schwarz.

"At first glance we are overwhelmed by the magnitude of this work in several respects, viz.: First, by the size of the volume, then by the array of eminent teachers in this department who have taken part in its production, then by the profuseness and character of the illustrations, and last, but not least, the conciseness and clearness with which the text is rendered. This is an entirely new composition, embodying the highest knowledge of the art as it stands to-day by authors who occupy the front rank in their specialty, and there are many of them. We cannot turn over these pages without being struck by the superb illustrations which adorn so many of them. We are confident that this most practical work will find instant appreciation by practitioners as well as students."—*New York Medical Times*.

Permit me to say that your American Text-Book of Obstetrics is the most magnificent medical work that I have ever seen. I congratulate you and thank you for this superb work, which alone is sufficient to place you first in the ranks of medical publishers.

With profound respect I am sincerely yours,

ALEX. J. C. SKENE.

**\*AN AMERICAN TEXT-BOOK OF THE THEORY AND PRACTICE OF MEDICINE.** By American Teachers. Edited by WILLIAM PEPPER, M. D., LL.D., Provost and Professor of the Theory and Practice of Medicine and of Clinical Medicine in the University of Pennsylvania. Complete in two handsome royal-octavo volumes of about 1000 pages each, with illustrations to elucidate the text wherever necessary. Price per Volume: Cloth, \$5.00 net; Sheep or Half-Morocco, \$6.00 net.

### VOLUME I. CONTAINS:

Hygiene.—Fever (Ephemeral, Simple Continued, Typhus, Typhoid, Epidemic Cerebro-spinal Meningitis, and Relapsing).—Scarlatina, Measles, Rötheln, Variola, Varioloid, Vaccinia, Varicella, Mumps, Whooping-cough, Anthrax, Hydrophobia, Trichinosis, Actino-

mycosis, Glanders, and Tetanus.—Tuberculosis, Scrofula, Syphilis, Diphtheria, Erysipelas, Malaria, Cholera, and Yellow Fever.—Nervous, Muscular, and Mental Diseases etc.

### VOLUME II. CONTAINS:

Urine (Chemistry and Microscopy).—Kidney and Lungs.—Air-passages (Larynx and Bronchi) and Pleura.—Pharynx, Oesophagus, Stomach and Intestines (including Intestinal Parasites), Heart, Aorta, Arteries and Veins.

—Peritoneum, Liver, and Pancreas.—Diathetic Diseases (Rheumatism, Rheumatoid Arthritis, Gout, Lithæmia, and Diabetes).—Blood and Spleen.—Inflammation, Embolism, Thrombosis, Fever, and Bacteriology.

The articles are not written as though addressed to students in lectures, but are exhaustive descriptions of diseases, with the newest facts as regards Causation, Symptomatology, Diagnosis, Prognosis, and Treatment, including a large number of approved formulæ. The recent advances made in the study of the bacterial origin of various diseases are fully described, as well as the bearing of the knowledge so gained upon prevention and cure. The subjects of Bacteriology as a whole and of Immunity are fully considered in a separate section.

Methods of diagnosis are given the most minute and careful attention, thus enabling the reader to learn the very latest methods of investigation without consulting works specially devoted to the subject.

### CONTRIBUTORS:

Dr. J. S. Billings, Philadelphia.  
Francis Delafield, New York.  
Reginald H. Fitz, Boston.  
James W. Holland, Philadelphia.  
Henry M. Lyman, Chicago.  
William Osler, Baltimore.

Dr. William Pepper, Philadelphia.  
W. Gilman Thompson, New York.  
W. H. Welch, Baltimore.  
James T. Whittaker, Cincinnati.  
James C. Wilson, Philadelphia.  
Horatio C. Wood, Philadelphia.

"We reviewed the first volume of this work, and said: 'It is undoubtedly one of the best text-books on the practice of medicine which we possess.' A consideration of the second and last volume leads us to modify that verdict and to say that the completed work is, in our opinion, THE BEST of its kind it has ever been our fortune to see. It is complete, thorough, accurate, and clear. It is well written, well arranged, well printed, well illustrated, and well bound. It is a model of what the modern text-book should be."—*New York Medical Journal*.

"A library upon modern medical art. The work must promote the wider diffusion of sound knowledge."—*American Lancet*.

"A trusty counsellor for the practitioner or senior student, on which he may implicitly rely."—*Edinburgh Medical Journal*.

\* **AN AMERICAN TEXT-BOOK OF SURGERY.** Edited by WILLIAM W. KEEN, M. D., LL.D., and J. WILLIAM WHITE, M. D., PH. D. Forming one handsome royal octavo volume of 1230 pages (10×7 inches), with 496 wood-cuts in text, and 37 colored and half-tone plates, many of them engraved from original photographs and drawings furnished by the authors. Price: Cloth, \$7.00 net; Sheep or Half Morocco, \$8.00 net.

### THIRD EDITION. THOROUGHLY REVISED.

In the present edition, among the new topics introduced are a full consideration of serum-therapy; leucocytosis; post-operative insanity; the use of dry heat at high temperatures; Krönlein's method of locating the cerebral fissures; Hoffa's and Lorenz's operations of congenital dislocations of the hip; Allis's researches on dislocations of the hip-joint; lumbar puncture; the forcible reposition of the spine in Pott's disease; the treatment of exophthalmic goiter; the surgery of typhoid fever; gastrectomy and other operations on the stomach; new methods of operating upon the intestines; the use of Kelly's rectal specula; the surgery of the ureter; Schleich's infiltration-method and the use of eucaïn for local anesthesia; Krause's method of skin-grafting; the newer methods of disinfecting the hands; the use of gloves, etc. The sections on Appendicitis, on Fractures, and on Gynecological Operations have been revised and enlarged. A considerable number of new illustrations have been added, and enhance the value of the work.

The text of the entire book has been submitted to all the authors for their mutual criticism and revision—an idea in book-making that is entirely new and original. The book as a whole, therefore, expresses on all the important surgical topics of the day the consensus of opinion of the eminent surgeons who have joined in its preparation.

One of the most attractive features of the book is its illustrations. Very many of them are original and faithful reproductions of photographs taken directly from patients or from specimens.

### CONTRIBUTORS:

Dr. Phineas S. Conner, Cincinnati.  
 Frederic S. Dennis, New York.  
 William W. Keen, Philadelphia.  
 Charles B. Nancrede, Ann Arbor, Mich.  
 Roswell Park, Buffalo, New York.  
 Lewis S. Pilcher, New York.

Dr. Nicholas Senn, Chicago.  
 Francis J. Shepherd, Montreal, Canada.  
 Lewis A. Stimson, New York.  
 J. Collins Warren, Boston.  
 J. William White, Philadelphia.

"If this text-book is a fair reflex of the present position of American surgery, we must admit it is of a very high order of merit, and that English surgeons will have to look very carefully to their laurels if they are to preserve a position in the van of surgical practice."—*London Lancet*.

Personally, I should not mind it being called **THE TEXT-BOOK** (instead of **A TEXT-BOOK**), for I know of no single volume which contains so readable and complete an account of the science and art of Surgery as this does."—EDMUND OWEN, F. R. C. S., *Member of the Board of Examiners of the Royal College of Surgeons, England*.



\* **AN AMERICAN TEXT-BOOK OF GYNECOLOGY, MEDICAL AND SURGICAL**, for the use of Students and Practitioners. Edited by J. M. BALDY, M. D. Forming a handsome royal-octavo volume of 718 pages, with 341 illustrations in the text and 38 colored and half-tone plates. Prices: Cloth, \$6.00 net; Sheep or Half-Morocco, \$7.00 net.

**SECOND EDITION, THOROUGHLY REVISED.**

In this volume all anatomical descriptions, excepting those essential to a clear understanding of the text, have been omitted, the illustrations being largely depended upon to elucidate the anatomy of the parts. This work, which is thoroughly practical in its teachings, is intended, as its title implies, to be a working text-book for physicians and students. A clear line of treatment has been laid down in every case, and although no attempt has been made to discuss mooted points, still the most important of these have been noted and explained. The operations recommended are fully illustrated, so that the reader, having a picture of the procedure described in the text under his eye, cannot fail to grasp the idea. All extraneous matter and discussions have been carefully excluded, the attempt being made to allow no unnecessary details to cumber the text. The subject-matter is brought up to date at every point, and the work is as nearly as possible the combined opinions of the ten specialists who figure as the authors.

In the revised edition much new material has been added, and some of the old eliminated or modified. More than forty of the old illustrations have been replaced by new ones, which add very materially to the elucidation of the text, as they picture methods, not specimens. The chapters on technique and after-treatment have been considerably enlarged, and the portions devoted to plastic work have been so greatly improved as to be practically new. Hysterectomy has been rewritten, and all the descriptions of operative procedures have been carefully revised and fully illustrated.

**CONTRIBUTORS:**

Dr. Henry T. Byford.  
John M. Baldy.  
Edwin Cragin.  
J. H. Etheridge.  
William Goodell.

Dr. Howard A. Kelly.  
Florian Krug.  
E. E. Montgomery.  
William R. Pryor.  
George M. Tuttle.

"The most notable contribution to gynecological literature since 1887, . . . and the most complete exponent of gynecology which we have. No subject seems to have been neglected, . . . and the gynecologist and surgeon, and the general practitioner who has any desire to practise diseases of women, will find it of practical value. In the matter of illustrations and plates the book surpasses anything we have seen."—*Boston Medical and Surgical Journal*.

"A thoroughly modern text-book, and gives reliable and well-tempered advice and instruction."—*Edinburgh Medical Journal*.

"The harmony of its conclusions and the homogeneity of its style give it an individuality which suggests a single rather than a multiple authorship."—*Annals of Surgery*.

"It must command attention and respect as a worthy representation of our advanced clinical teaching."—*American Journal of Medical Sciences*.

**\*AN AMERICAN TEXT-BOOK OF THE DISEASES OF CHILDREN.** By American Teachers. Edited by LOUIS STARR, M. D., assisted by THOMPSON S. WESTCOTT, M. D. In one handsome royal-8vo volume of 1244 pages, profusely illustrated with wood-cuts, half-tone and colored plates. Net Prices: Cloth, \$7.00; Sheep or Half-Morocco, \$8.00.

### SECOND EDITION, REVISED AND ENLARGED.

The plan of this work embraces a series of original articles written by some sixty well-known pædiatrists, representing collectively the teachings of the most prominent medical schools and colleges of America. The work is intended to be a PRACTICAL book, suitable for constant and handy reference by the practitioner and the advanced student.

Especial attention has been given to the latest accepted teachings upon the etiology, symptoms, pathology, diagnosis, and treatment of the disorders of children, with the introduction of many special formulæ and therapeutic procedures.

In this new edition the whole subject matter has been carefully revised, new articles added, some original papers emended, and a number entirely rewritten. The new articles include "Modified Milk and Percentage Milk-Mixtures," "Lithemia," and a section on "Orthopedics." Those rewritten are "Typhoid Fever," "Rubella," "Chicken-pox," "Tuberculous Meningitis," "Hydrocephalus," and "Scurvy;" while extensive revision has been made in "Infant Feeding," "Measles," "Diphtheria," and "Cretinism." The volume has thus been much increased in size by the introduction of fresh material.

### CONTRIBUTORS:

Dr. S. S. Adams, Washington.  
John Ashhurst, Jr., Philadelphia.  
A. D. Blackader, Montreal, Canada.  
David Bovaird, New York.  
Dillon Brown, New York.  
Edward M. Buckingham, Boston.  
Charles W. Burr, Philadelphia.  
W. E. Casselberry, Chicago.  
Henry Dwight Chapin, New York.  
W. S. Christopher, Chicago.  
Archibald Church, Chicago.  
Floyd M. Crandall, New York.  
Andrew F. Currier, New York.  
Roland G. Curtin, Philadelphia.  
J. M. DaCosta, Philadelphia.  
I. N. Danforth, Chicago.  
Edward P. Davis, Philadelphia.  
John B. Deaver, Philadelphia.  
G. E. de Schweinitz, Philadelphia.  
John Dorning, New York.  
Charles Warrington Earle, Chicago.  
Wm. A. Edwards, San Diego, Cal.  
F. Forchheimer, Cincinnati.  
J. Henry Fruitnight, New York.  
J. P. Crozer Griffith, Philadelphia.  
W. A. Hardaway, St. Louis.  
M. P. Hatfield, Chicago.  
Barton Cooke Hirst, Philadelphia.  
H. Illoway, Cincinnati.  
Henry Jackson, Boston.  
Charles G. Jennings, Detroit.  
Henry Koplik, New York.

Dr. Thomas S. Latimer, Baltimore.  
Albert R. Leeds, Hoboken, N. J.  
J. Hendrie Lloyd, Philadelphia.  
George Roe Lockwood, New York.  
Henry M. Lyman, Chicago.  
Francis T. Miles, Baltimore.  
Charles K. Mills, Philadelphia.  
James E. Moore, Minneapolis.  
F. Gordon Morrill, Boston.  
John H. Musser, Philadelphia.  
Thomas R. Neilson, Philadelphia.  
W. P. Northrup, New York.  
William Osler, Baltimore.  
Frederick A. Packard, Philadelphia.  
William Pepper, Philadelphia.  
Frederick Peterson, New York.  
W. T. Plant, Syracuse, New York.  
William M. Powell, Atlantic City.  
B. K. Rachford, Cincinnati.  
B. Alexander Randall, Philadelphia.  
Edward O. Shakespeare, Philadelphia.  
F. C. Shattuck, Boston.  
J. Lewis Smith, New York.  
Louis Starr, Philadelphia.  
M. Allen Starr, New York.  
Charles W. Townsend, Boston.  
James Tyson, Philadelphia.  
W. S. Thayer, Baltimore.  
Victor C. Vaughan, Ann Arbor, Mich.  
Thompson S. Westcott, Philadelphia.  
Henry R. Wharton, Philadelphia.  
J. William White, Philadelphia.  
J. C. Wilson, Philadelphia.



\* **AN AMERICAN TEXT-BOOK OF GENITO-URINARY AND SKIN DISEASES.** By 47 Eminent Specialists and Teachers. Edited by L. BOLTON BANGS, M. D., Professor of Genito-Urinary Surgery, University and Bellevue Hospital Medical College, New York; and W. A. HARDAWAY, M. D., Professor of Diseases of the Skin, Missouri Medical College. Imperial octavo volume of 1229 pages, with 300 engravings and 20 full-page colored plates. Cloth, \$7.00 net; Sheep or Half Morocco, \$8.00 net.

This addition to the series of "American Text-Books," it is confidently believed, will meet the requirements of both students and practitioners, giving, as it does, a comprehensive and detailed presentation of the Diseases of the Genito-Urinary Organs, of the Venereal Diseases, and of the Affections of the Skin.

Having secured the collaboration of well-known authorities in the branches represented in the undertaking, the editors have not restricted the contributors in regard to the particular views set forth, but have offered every facility for the free expression of their individual opinions. The work will therefore be found to be original, yet homogeneous and fully representative of the several departments of medical science with which it is concerned.

#### CONTRIBUTORS:

Dr. Chas. W. Allen, New York.  
I. E. Atkinson, Baltimore.  
L. Bolton Bangs, New York.  
P. R. Bolton, New York.  
Lewis C. Boshier, Richmond, Va.  
John T. Bowen, Boston.  
J. Abbott Cantrell, Philadelphia.  
William T. Corlett, Cleveland, Ohio.  
B. Farquhar Curtis, New York.  
Condict W. Cutler, New York.  
Isadore Dyer, New Orleans.  
Christian Fenger, Chicago.  
John A. Fordyce, New York.  
Eugene Fuller, New York.  
R. H. Greene, New York.  
Joseph Grindon, St. Louis.  
Graeme M. Hammond, New York.  
W. A. Hardaway, St. Louis.  
M. B. Hartzell, Philadelphia.  
Louis Heitzmann, New York.  
James S. Howe, Boston.  
George T. Jackson, New York.  
Abraham Jacobi, New York.  
James C. Johnston, New York.

Dr. Hermann G. Klotz, New York.  
J. H. Linsley, Burlington, Vt.  
G. F. Lydston, Chicago.  
Hartwell N. Lyon, St. Louis.  
Edward Martin, Philadelphia.  
D. G. Montgomery, San Francisco.  
James Pedersen, New York.  
S. Pollitzer, New York.  
Thomas R. Pooley, New York.  
A. R. Robinson, New York.  
A. E. Regensburger, San Francisco.  
Francis J. Shepherd, Montreal, Can.  
S. C. Stanton, Chicago, Ill.  
Emmanuel J. Stout, Philadelphia.  
Alonzo E. Taylor, Philadelphia.  
Robert W. Taylor, New York.  
Paul Thorndike, Boston.  
H. Tuholske, St. Louis.  
Arthur Van Harlingen, Philadelphia.  
Francis S. Watson, Boston.  
J. William White, Philadelphia.  
J. McF. Winfield, Brooklyn.  
Alfred C. Wood, Philadelphia.

"This voluminous work is thoroughly up to date, and the chapters on genito-urinary diseases are especially valuable. The illustrations are fine and are mostly original. The section on dermatology is concise and in every way admirable."—*Journal of the American Medical Association*.

"This volume is one of the best yet issued of the publisher's series of 'American Text-Books.' The list of contributors represents an extraordinary array of talent and extended experience. The book will easily take the place in comprehensiveness and value of the half dozen or more costly works on these subjects which have hitherto been necessary to a well-equipped library."—*New York Polyclinic*.

\* **AN AMERICAN TEXT-BOOK OF DISEASES OF THE EYE, EAR, NOSE, AND THROAT.** Edited by GEORGE E. DE SCHWEINITZ, A. M., M. D., Professor of Ophthalmology, Jefferson Medical College; and B. ALEXANDER RANDALL, A. M., M. D., Clinical Professor of Diseases of the Ear, University of Pennsylvania. One handsome imperial octavo volume of 1251 pages; 766 illustrations, 59 of them colored. Prices: Cloth, \$7.00 net; Sheep or Half-Morocco, \$8.00 net.

### *Just Issued.*

The present work is the only book ever published embracing diseases of the intimately related organs of the eye, ear, nose, and throat. Its special claim to favor is based on encyclopedic, authoritative, and practical treatment of the subjects.

Each section of the book has been entrusted to an author who is specially identified with the subject on which he writes, and who therefore presents his case in the manner of an expert. Uniformity is secured and overlapping prevented by careful editing and by a system of cross-references which forms a special feature of the volume, enabling the reader to come into touch with all that is said on any subject in different portions of the book.

Particular emphasis is laid on the most approved methods of treatment, so that the book shall be one to which the student and practitioner can refer for information in practical work. Anatomical and physiological problems, also, are fully discussed for the benefit of those who desire to investigate the more abstruse problems of the subject.

### **CONTRIBUTORS:**

Dr. Henry A. Alderton, Brooklyn.  
Harrison Allen, Philadelphia.  
Frank Allport, Chicago.  
Morris J. Asch, New York.  
S. C. Ayres, Cincinnati.  
R. O. Beard, Minneapolis.  
Clarence J. Blake, Boston.  
Arthur A. Bliss, Philadelphia.  
Albert P. Brubaker, Philadelphia.  
J. H. Bryan, Washington, D. C.  
Albert H. Buck, New York.  
F. Buller, Montreal, Can.  
Swan M. Burnett, Washington, D. C.  
Flemming Carrow, Ann Arbor, Mich.  
W. E. Casselberry, Chicago.  
Colman W. Cutler, New York.  
Edward B. Dench, New York.  
William S. Dennett, New York.  
George E. de Schweinitz, Philadelphia.  
Alexander Duane, New York.  
John W. Farlow, Boston, Mass.  
Walter J. Freeman, Philadelphia.  
H. Gifford, Omaha, Neb.  
W. C. Glasgow, St. Louis.  
J. Orne Green, Boston.  
Ward A. Holden, New York.  
Christian R. Holmes, Cincinnati.  
William E. Hopkins, San Francisco.  
F. C. Hotz, Chicago.  
Lucien Howe, Buffalo, N. Y.

Dr. Alvin A. Hubbell, Buffalo, N. Y.  
Edward Jackson, Philadelphia.  
J. Ellis Jennings, St. Louis.  
Herman Knapp, New York.  
Chas. W. Kollock, Charleston, S. C.  
G. A. Leland, Boston.  
J. A. Lippincott, Pittsburg, Pa.  
G. Hudson Makuen, Philadelphia.  
John H. McCollom, Boston.  
H. G. Miller, Providence, R. I.  
B. L. Milliken, Cleveland, Ohio.  
Robert C. Myles, New York.  
James E. Newcomb, New York.  
R. J. Phillips, Philadelphia.  
George A. Piersol, Philadelphia.  
W. P. Porcher, Charleston, S. C.  
B. Alex. Randall, Philadelphia.  
Robert L. Randolph, Baltimore.  
John O. Roe, Rochester, N. Y.  
Charles E. de M. Sajous, Philadelphia.  
J. E. Sheppard, Brooklyn, N. Y.  
E. L. Shurly, Detroit, Mich.  
William M. Sweet, Philadelphia.  
Samuel Theobald, Baltimore, Md.  
A. G. Thomson, Philadelphia.  
Clarence A. Veasey, Philadelphia.  
John E. Weeks, New York.  
Casey A. Wood, Chicago, Ill.  
Jonathan Wright, Brooklyn.  
H. V. Würdemann, Milwaukee, Wis.

\* **AN AMERICAN YEAR-BOOK OF MEDICINE AND SURGERY.** A Yearly Digest of Scientific Progress and Authoritative Opinion in all branches of Medicine and Surgery, drawn from journals, monographs, and text-books of the leading American and Foreign authors and investigators. Collected and arranged, with critical editorial comments, by eminent American specialists and teachers, under the general editorial charge of GEORGE M. GOULD, M. D. Volumes for 1896, '97, '98, and '99 each a handsome imperial octavo volume of about 1200 pages. Prices: Cloth, \$6.50 net; Half-Morocco, \$7.50 net. Year-Book for 1900 in two octavo volumes of about 600 pages each. Prices per volume: Cloth, \$3.00 net; Half-Morocco, \$3.75 net.

### In Two Volumes. No Increase in Price.

In response to a widespread demand from the medical profession, the publisher of the "American Year-Book of Medicine and Surgery" has decided to issue that well-known work in two volumes, Vol. I. treating of **General Medicine**, Vol. II. of **General Surgery**. Each volume is complete in itself, and the work is sold either separately or in sets.

This division is made in such a way as to appeal to physicians from a class standpoint, one volume being distinctly medical, and the other distinctly surgical. This arrangement has a two-fold advantage. To the physician who uses the entire book, it offers an increased amount of matter in the most convenient form for easy consultation, and without any increase in price; while the man who wants either the medical or the surgical section alone secures the complete consideration of his branch without the necessity of purchasing matter for which he has no use.

### CONTRIBUTORS:

#### VOL. I.

Dr. Samuel W. Abbott, Boston.  
Archibald Church, Chicago.  
Louis A. Duhring, Philadelphia.  
D. L. Edsall, Philadelphia.  
Alfred Hand, Jr., Philadelphia.  
M. B. Hartzell, Philadelphia.  
Reid Hunt, Baltimore.  
Wyatt Johnston, Montreal.  
Walter Jones, Baltimore.  
David Riesman, Philadelphia.  
Louis Starr, Philadelphia.  
Alfred Stengel, Philadelphia.  
A. A. Stevens, Philadelphia.  
G. N. Stewart, Cleveland.  
Reynold W. Wilcox, New York City.

#### VOL. II.

Dr. J. Montgomery Baldy, Philadelphia.  
Charles H. Burnett, Philadelphia.  
J. Chalmers DaCosta, Philadelphia.  
W. A. N. Dorland, Philadelphia.  
Virgil P. Gibney, New York City.  
C. H. Hamann, Cleveland.  
Howard F. Hansell, Philadelphia.  
Barton Cooke Hirst, Philadelphia.  
E. Fletcher Ingals, Chicago.  
W. W. Keen, Philadelphia.  
Henry G. Ohls, Chicago.  
Wendell Reber, Philadelphia.  
J. Hilton Waterman, New York City.

"It is difficult to know which to admire most—the research and industry of the distinguished band of experts whom Dr. Gould has enlisted in the service of the Year-Book, or the wealth and abundance of the contributions to every department of science that have been deemed worthy of analysis. . . . It is much more than a mere compilation of abstracts, for, as each section is entrusted to experienced and able contributors, the reader has the advantage of certain critical commentaries and expositions . . . proceeding from writers fully qualified to perform these tasks. . . . It is emphatically a book which should find a place in every medical library, and is in several respects more useful than the famous 'Jahrbucher' of Germany."—*London Lancet*.

\* **ANOMALIES AND CURIOSITIES OF MEDICINE.** By GEORGE M. GOULD, M.D., and WALTER L. PYLE, M.D. An encyclopedic collection of rare and extraordinary cases and of the most striking instances of abnormality in all branches of Medicine and Surgery, derived from an exhaustive research of medical literature from its origin to the present day, abstracted, classified, annotated, and indexed. Handsome imperial octavo volume of 968 pages, with 295 engravings in the text, and 12 full-page plates. Cloth, \$3.00 net; Half-Morocco, \$4.00 net.

### POPULAR EDITION REDUCED FROM \$6.00 to \$3.00.

In view of the great success of this magnificent work, the publisher has decided to issue a "Popular Edition" at a price so low that it may be procured by every student and practitioner of medicine. Notwithstanding the great reduction in price, there will be no depreciation in the excellence of typography, paper, and binding that characterized the earlier editions.

Several years of exhaustive research have been spent by the authors in the great medical libraries of the United States and Europe in collecting the material for this work. Medical literature of all ages and all languages has been carefully searched, as a glance at the Bibliographic Index will show. The facts, which will be of extreme value to the author and lecturer, have been arranged and annotated, and full reference footnotes given.

"One of the most valuable contributions ever made to medical literature. It is, so far as we know, absolutely unique, and every page is as fascinating as a novel. Not alone for the medical profession has this volume value: it will serve as a book of reference for all who are interested in general scientific, sociologic, or medico-legal topics."—*Brooklyn Medical Journal*.

**NERVOUS AND MENTAL DISEASES.** By ARCHIBALD CHURCH, M.D., Professor of Clinical Neurology, Mental Diseases, and Medical Jurisprudence, Northwestern University Medical School; and FREDERICK PETERSON, M.D., Clinical Professor of Mental Diseases, Woman's Medical College, New York. Handsome octavo volume of 843 pages, with over 300 illustrations. Prices: Cloth, \$5.00 net; Half-Morocco, \$6.00 net.

### *Second Edition.*

This book is intended to furnish students and practitioners with a practical, working knowledge of nervous and mental diseases. Written by men of wide experience and authority, it presents the many recent additions to the subject. The book is not filled with an extended dissertation on anatomy and pathology, but, treating these points in connection with special conditions, it lays particular stress on methods of examination, diagnosis, and treatment. In this respect the work is unusually complete and valuable, laying down the definite courses of procedure which the authors have found to be most generally satisfactory.

"The work is an epitome of what is to-day known of nervous diseases prepared for the student and practitioner in the light of the author's experience . . . We believe that no work presents the difficult subject of insanity in such a reasonable and readable way."—*Chicago Medical Recorder*.



**DISEASES OF THE NOSE AND THROAT.** By D. BRADEN KYLE, M. D., Clinical Professor of Laryngology and Rhinology, Jefferson Medical College, Philadelphia; Consulting Laryngologist, Rhinologist, and Otologist, St. Agnes' Hospital. Octavo volume of 646 pages, with over 150 illustrations and 6 lithographic plates. Cloth, \$4.00 net; Half-Morocco, \$5.00 net.

*Just Issued.*

This book presents the subject of Diseases of the Nose and Throat in as concise a manner as is consistent with clearness, keeping in mind the needs of the student and general practitioner as well as those of the specialist. The arrangement and classification are based on modern pathology, and the pathological views advanced are supported by drawings of microscopical sections made in the author's own laboratory. These and the other illustrations are particularly fine, being chiefly original. With the practical purpose of the book in mind, extended consideration has been given to details of treatment, each disease being considered in full, and definite courses being laid down to meet special conditions and symptoms.

"It is a thorough, full, and systematic treatise, so classified and arranged as greatly to facilitate the teaching of laryngology and rhinology to classes, and must prove most convenient and satisfactory as a reference book, both for students and practitioners."—*International Medical Magazine*.

**THE HYGIENE OF TRANSMISSIBLE DISEASES: their Causation, Modes of Dissemination, and Methods of Prevention.** By A. C. ABBOTT, M. D., Professor of Hygiene in the University of Pennsylvania; Director of the Laboratory of Hygiene. Octavo volume of 311 pages, with charts and maps, and numerous illustrations. Cloth, \$2.00 net.

*Just Issued.*

It is not the purpose of this work to present the subject of Hygiene in the comprehensive sense ordinarily implied by the word, but rather to deal directly with but a section, certainly not the least important, of the subject—viz., that embracing a knowledge of the preventable specific diseases. The book aims to furnish information concerning the detailed management of transmissible diseases. Incidentally there are discussed those numerous and varied factors that have not only a direct bearing upon the incidence and suppression of such diseases, but are of general sanitary importance as well.

"The work is admirable in conception and no less so in execution. It is a practical work, simply and lucidly written, and it should prove a most helpful aid in that department of medicine which is becoming daily of increasing importance and application—namely, prophylaxis."—*Philadelphia Medical Journal*.

"It is scientific, but not too technical; it is as complete as our present-day knowledge of hygiene and sanitation allows, and it is in harmony with the efforts of the profession, which are tending more and more to methods of prophylaxis. For the student and for the practitioner it is well nigh indispensable."—*Medical News*, New York.

- A TEXT-BOOK OF EMBRYOLOGY.** By JOHN C. HEISLER, M. D., Professor of Anatomy in the Medico-Chirurgical College, Philadelphia. Octavo volume of 405 pages, with 190 illustrations, 26 in colors. Cloth, \$2.50 net.

*Just Issued.*

The facts of embryology having acquired in recent years such great interest in connection with the teaching and with the proper comprehension of human anatomy, it is of first importance to the student of medicine that a concise and yet sufficiently full text-book upon the subject be available. It was with the aim of presenting such a book that this volume was written, the author, in his experience as a teacher of anatomy, having been impressed with the fact that students were seriously handicapped in their study of the subject of embryology by the lack of a text-book full enough to be intelligible, and yet without that minuteness of detail which characterizes the larger treatises, and which so often serves only to confuse and discourage the beginner.

"In short, the book is written to fill a want which has distinctly existed and which it definitely meets; commendation greater than this it is not possible to give to anything."—*Medical News*, New York.

- A MANUAL OF DISEASES OF THE EYE.** By EDWARD JACKSON, A. M., M. D., sometime Professor of Diseases of the Eye in the Philadelphia Polyclinic and College for Graduates in Medicine. 12mo, 604 pages, with 178 illustrations from drawings by the author. Cloth, \$2.50 net.

*Just Issued.*

This book is intended to meet the needs of the general practitioner of medicine and the beginner in ophthalmology. More attention is given to the conditions that must be met and dealt with early in ophthalmic practice than to the rarer diseases and more difficult operations that may come later.

It is designed to furnish efficient aid in the actual work of dealing with disease, and therefore gives the place of first importance to the recognition and management of the conditions that present themselves in actual clinical work.

- LECTURES ON THE PRINCIPLES OF SURGERY.** By CHARLES B. NANCREDE, M. D., LL.D., Professor of Surgery and of Clinical Surgery, University of Michigan, Ann Arbor. Handsome octavo, 398 pages, illustrated. Cloth, \$2.50 net.

*Just Issued.*

The present book is based on the lectures delivered by Dr. Nancrede to his undergraduate classes, and is intended as a text-book for students and a practical help for teachers. By the careful elimination of unnecessary details of pathology, bacteriology, etc., which are amply provided for in other courses of study, space is gained for a more extended consideration of the Principles of Surgery in themselves, and of the application of these principles to methods of practice.



**A TEXT-BOOK OF PATHOLOGY.** By ALFRED STENGEL, M. D., Professor of Clinical Medicine in the University of Pennsylvania; Physician to the Philadelphia Hospital; Physician to the Children's Hospital, Philadelphia. Handsome octavo volume of 848 pages, with 362 illustrations, many of which are in colors. Prices: Cloth, \$4.00 net; Half-Morocco, \$5.00 net.

*Second Edition.*

In this work the practical application of pathological facts to clinical medicine is considered more fully than is customary in works on pathology. While the subject of pathology is treated in the broadest way consistent with the size of the book, an effort has been made to present the subject from the point of view of the clinician. The general relations of bacteriology to pathology are discussed at considerable length, as the importance of these branches deserves. It will be found that the recent knowledge is fully considered, as well as older and more widely-known facts.

"I consider the work abreast of modern pathology, and useful to both students and practitioners. It presents in a concise and well-considered form the essential facts of general and special pathological anatomy, with more than usual emphasis upon pathological physiology."—WILLIAM H. WELCH, *Professor of Pathology, Johns Hopkins University, Baltimore, Md.*

"I regard it as the most serviceable text-book for students on this subject yet written by an American author."—L. HEKTOEN, *Professor of Pathology, Rush Medical College, Chicago, Ill.*

**A TEXT-BOOK OF OBSTETRICS.** By BARTON COOKE HIRST, M.D., Professor of Obstetrics in the University of Pennsylvania. Handsome octavo volume of 846 pages, with 618 illustrations and seven colored plates. Prices: Cloth, \$5.00 net; Half-Morocco, \$6.00 net.

*Second Edition.*

This work, which has been in course of preparation for several years, is intended as an ideal text-book for the student no less than an advanced treatise for the obstetrician and for general practitioners. It represents the very latest teaching in the practice of obstetrics by a man of extended experience and recognized authority. The book emphasizes especially, as a work on obstetrics should, the practical side of the subject, and to this end presents an unusually large collection of illustrations. A great number of these are new and original, and the whole collection will form a complete atlas of obstetrical practice. An extremely valuable feature of the book is the large number of references to cases, authorities, sources, etc., forming, as it does, a valuable bibliography of the most recent and authoritative literature on the subject of obstetrics. As already stated, this work records the wide practical experience of the author, which fact, combined with the brilliant presentation of the subject, will doubtless render this one of the most notable books on obstetrics that has yet appeared.

"The illustrations are numerous and are works of art, many of them appearing for the first time. The arrangement of the subject-matter, the foot-notes, and index are beyond criticism. The author's style, though condensed, is singularly clear, so that it is never necessary to re-read a sentence in order to grasp its meaning. As a true model of what a modern text-book in obstetrics should be, we feel justified in affirming that Dr. Hirst's book is without a rival."—*New York Medical Record.*

**A TEXT-BOOK OF THE PRACTICE OF MEDICINE.** By JAMES M. ANDERS, M.D., PH.D., LL.D., Professor of the Practice of Medicine and of Clinical Medicine, Medico-Chirurgical College, Philadelphia. In one handsome octavo volume of 1292 pages, fully illustrated. Cloth, \$5.50 net; Sheep or Half-Morocco, \$6.50 net.

### THIRD EDITION, THOROUGHLY REVISED.

The present edition is the result of a careful and thorough revision. A few new subjects have been introduced: Glandular Fever, Ether-pneumonia, Splenic Anemia, Meralgia Paresthetica, and Periodic Paralysis. The affections that have been substantially rewritten are: Plague, Malta Fever, Diseases of the Thymus Gland, Liver Cirrhoses, and Progressive Spinal Muscular Atrophy. The following articles have been extensively revised: Typhoid Fever, Yellow Fever, Lobar Pneumonia, Dengue, Tuberculosis, Diabetes Mellitus, Gout, Arthritis Deformans, Autumnal Catarrh, Diseases of the Circulatory System, more particularly Hypertrophy and Dilatation of the Heart, Arteriosclerosis and Thoracic Aneurysm, Pancreatic Hemorrhage, Jaundice, Acute Peritonitis, Acute Yellow Atrophy, Hematoma of Dura Mater, and Scleroses of the Brain. The preliminary chapter on Nervous Diseases is new, and deals with the subject of localization and the various methods of investigating nervous affections.

"It is an excellent book—concise, comprehensive, thorough, and up to date. It is a credit to you; but, more than that, it is a credit to the profession of Philadelphia—to us."  
—JAMES C. WILSON, *Professor of the Practice of Medicine and Clinical Medicine, Jefferson Medical College, Philadelphia.*

"The book can be unreservedly recommended to students and practitioners as a safe, full compendium of the knowledge of internal medicine of the present day... It is a work thoroughly modern in every sense."—*Medical News, New York.*

**DISEASES OF THE STOMACH.** By WILLIAM W. VAN VALZAH, M.D., Professor of General Medicine and Diseases of the Digestive System and the Blood, New York Polyclinic; and J. DOUGLAS NISBET, M.D., Adjunct Professor of General Medicine and Diseases of the Digestive System and the Blood, New York Polyclinic. Octavo volume of 674 pages, illustrated. Cloth, \$3.50 net.

An eminently practical book, intended as a guide to the student, an aid to the physician, and a contribution to scientific medicine. It aims to give a complete description of the modern methods of diagnosis and treatment of diseases of the stomach, and to reconstruct the pathology of the stomach in keeping with the revelations of scientific research. The book is clear, practical, and complete, and contains the results of the authors' investigations and of their extensive experience as specialists. Particular attention is given to the important subject of dietetic treatment. The diet-lists are very complete, and are so arranged that selections can readily be made to suit individual cases.

"This is the most satisfactory work on the subject in the English language."—*Chicago Medical Recorder.*

"The article on diet and general medication is one of the most valuable in the book, and should be read by every practising physician."—*New York Medical Journal.*

**SURGICAL DIAGNOSIS AND TREATMENT.** By J. W. MACDONALD, M. D., Edin., F. R. C. S., Edin., Professor of the Practice of Surgery and of Clinical Surgery in Hamline University; Visiting Surgeon to St. Barnabas' Hospital, Minneapolis, etc. Handsome octavo volume of 800 pages, profusely illustrated. Cloth, \$5.00 net; Half-Morocco, \$6.00 net.

This work aims in a comprehensive manner to furnish a guide in matters of surgical diagnosis. It sets forth in a systematic way the necessities of examinations and the proper methods of making them. The various portions of the body are then taken up in order and the diseases and injuries thereof succinctly considered and the treatment briefly indicated. Practically all the modern and approved operations are described with thoroughness and clearness. The work concludes with a chapter on the use of the Röntgen rays in surgery.

"The work is brimful of just the kind of practical information that is useful alike to students and practitioners. It is a pleasure to commend the book because of its intrinsic value to the medical practitioner."—*Cincinnati Lancet-Clinic*.

**PATHOLOGICAL TECHNIQUE.** A Practical Manual for Laboratory Work in Pathology, Bacteriology, and Morbid Anatomy, with chapters on Post-Mortem Technique and the Performance of Autopsies. By FRANK B. MALLORY, A. M., M. D., Assistant Professor of Pathology, Harvard University Medical School, Boston; and JAMES H. WRIGHT, A. M., M. D., Instructor in Pathology, Harvard University Medical School, Boston. Octavo volume of 396 pages, handsomely illustrated. Cloth, \$2.50 net.

This book is designed especially for practical use in pathological laboratories, both as a guide to beginners and as a source of reference for the advanced. The book will also meet the wants of practitioners who have opportunity to do general pathological work. Besides the methods of post-mortem examinations and of bacteriological and histological investigations connected with autopsies, the special methods employed in clinical bacteriology and pathology have been fully discussed.

"One of the most complete works on the subject, and one which should be in the library of every physician who hopes to keep pace with the great advances made in pathology."—*Journal of American Medical Association*.

**THE SURGICAL COMPLICATIONS AND SEQUELS OF TYPHOID FEVER.** By WM. W. KEEN, M. D., LL.D., Professor of the Principles of Surgery and of Clinical Surgery, Jefferson Medical College, Philadelphia. Octavo volume of 386 pages, illustrated. Cloth, \$3.00 net.

This monograph is the only one in any language covering the entire subject of the Surgical Complications and Sequels of Typhoid Fever. The work will prove to be of importance and interest not only to the general surgeon and physician, but also to many specialists—laryngologists, ophthalmologists, gynecologists, pathologists, and bacteriologists—as the subject has an important bearing upon each one of their spheres. The author's conclusions are based on reports of over 1700 cases, including practically all those recorded in the last fifty years. Reports of cases have been brought down to date, many having been added while the work was in press.

"This is probably the first and only work in the English language that gives the reader a clear view of what typhoid fever really is, and what it does and can do to the human organism. This book should be in the possession of every medical man in America."—*American Medico-Surgical Bulletin*.

**MODERN SURGERY, GENERAL AND OPERATIVE.** By JOHN CHALMERS DACOSTA, M.D., Clinical Professor of Surgery, Jefferson Medical College, Philadelphia; Surgeon to the Philadelphia Hospital, etc. Handsome octavo volume of 911 pages, profusely illustrated. Cloth, \$4.00 net; Half-Morocco, \$5.00 net.

*Second Edition, Rewritten and Greatly Enlarged.*

The remarkable success attending DaCosta's Manual of Surgery, and the general favor with which it has been received, have led the author in this revision to produce a complete treatise on modern surgery along the same lines that made the former edition so successful. The book has been entirely rewritten and very much enlarged. The old edition has long been a favorite not only with students and teachers, but also with practising physicians and surgeons, and it is believed that the present work will find an even wider field of usefulness.

"We know of no small work on surgery in the English language which so well fulfils the requirements of the modern student."—*Medico-Chirurgical Journal*, Bristol, England.

"The author has presented concisely and accurately the principles of modern surgery. The book is a valuable one which can be recommended to students and is of great value to the general practitioner."—*American Journal of the Medical Sciences*.

**A MANUAL OF ORTHOPEDIC SURGERY.** By JAMES E. MOORE, M.D., Professor of Orthopedics and Adjunct Professor of Clinical Surgery, University of Minnesota, College of Medicine and Surgery. Octavo volume of 356 pages, with 177 beautiful illustrations from photographs made specially for this work. Cloth, \$2.50 net.

A practical book based upon the author's experience, in which special stress is laid upon early diagnosis and treatment such as can be carried out by the general practitioner. The teachings of the author are in accordance with his belief that true conservatism is to be found in the middle course between the surgeon who operates too frequently and the orthopedist who seldom operates.

"A very demonstrative work, every illustration of which conveys a lesson. The work is a most excellent and commendable one, which we can certainly endorse with pleasure."—*St. Louis Medical and Surgical Journal*.

**ELEMENTARY BANDAGING AND SURGICAL DRESSING.**

With Directions concerning the Immediate Treatment of Cases of Emergency. For the use of Dressers and Nurses. By WALTER PYE, F.R.C.S., late Surgeon to St. Mary's Hospital, London. Small 12mo, with over 80 illustrations. Cloth, flexible covers, 75 cents net.

This little book is chiefly a condensation of those portions of Pye's "Surgical Handicraft" which deal with bandaging, splinting, etc., and of those which treat of the management in the first instance of cases of emergency. The directions given are thoroughly practical, and the book will prove extremely useful to students, surgical nurses, and dressers.

"The author writes well, the diagrams are clear, and the book itself is small and portable, although the paper and type are good."—*British Medical Journal*.



**A TEXT-BOOK OF MATERIA MEDICA, THERAPEUTICS AND PHARMACOLOGY.** By GEORGE F. BUTLER, PH.G., M.D., Professor of Materia Medica and of Clinical Medicine in the College of Physicians and Surgeons, Chicago; Professor of Materia Medica and Therapeutics, Northwestern University, Woman's Medical School, etc. Octavo, 874 pages, illustrated. Cloth, \$4.00 net; Sheep, \$5.00 net.

*Third Edition, Thoroughly Revised.*

A clear, concise, and practical text-book, adapted for permanent reference no less than for the requirements of the class-room.

The recent important additions made to our knowledge of the physiological action of drugs are fully discussed in the present edition. The book has been thoroughly revised and many additions have been made.

"Taken as a whole, the book may fairly be considered as one of the most satisfactory of any single-volume works on materia medica in the market."—*Journal of the American Medical Association.*

**TUBERCULOSIS OF THE GENITO-URINARY ORGANS, MALE AND FEMALE.** By NICHOLAS SENN, M.D., PH.D., LL.D., Professor of the Practice of Surgery and of Clinical Surgery, Rush Medical College, Chicago. Handsome octavo volume of 320 pages, illustrated. Cloth, \$3.00 net.

Tuberculosis of the male and female genito-urinary organs is such a frequent, distressing, and fatal affection that a special treatise on the subject appears to fill a gap in medical literature. In the present work the bacteriology of the subject has received due attention, the modern resources employed in the differential diagnosis between tubercular and other inflammatory affections are fully described, and the medical and surgical therapeutics are discussed in detail.

"An important book upon an important subject, and written by a man of mature judgment and wide experience. The author has given us an instructive book upon one of the most important subjects of the day."—*Clinical Reporter.*

"A work which adds another to the many obligations the profession owes the talented author."—*Chicago Medical Recorder.*

**A TEXT-BOOK OF DISEASES OF WOMEN.** By CHARLES B. PENROSE, M.D., PH.D., Professor of Gynecology in the University of Pennsylvania; Surgeon to the Gynecean Hospital, Philadelphia. Octavo volume of 531 pages, with 217 illustrations, nearly all from drawings made for this work. Cloth, \$3.75 net.

*Third Edition, Revised.*

In this work, which has been written for both the student of gynecology and the general practitioner, the author presents the best teaching of modern gynecology untrammelled by antiquated theories or methods of treatment. In most instances but one plan of treatment is recommended, to avoid confusing the student or the physician who consults the book for practical guidance.

"I shall value very highly the copy of Penrose's 'Diseases of Women' received. I have already recommended it to my class as THE BEST book."—HOWARD A. KELLY, *Professor of Gynecology and Obstetrics, Johns Hopkins University, Baltimore, Md.*

"The book is to be commended without reserve, not only to the student but to the general practitioner who wishes to have the latest and best modes of treatment explained with absolute clearness."—*Therapeutic Gazette.*

**SURGICAL PATHOLOGY AND THERAPEUTICS.** By JOHN COLLINS WARREN, M. D., LL.D., Professor of Surgery, Medical Department Harvard University. Handsome octavo, 832 pages, with 136 relief and lithographic illustrations, 33 of which are printed in colors.

***Second Edition,***

with an Appendix devoted to the Scientific Aids to Surgical Diagnosis, and a series of articles on Regional Bacteriology. Cloth, \$5.00 net; Half-Morocco, \$6.00 net.

**Without Exception, the Illustrations are the Best ever Seen in a Work of this Kind.**

"A most striking and very excellent feature of this book is its illustrations. Without exception, from the point of accuracy and artistic merit, they are the best ever seen in a work of this kind. \* \* \* Many of those representing microscopic pictures are so perfect in their coloring and detail as almost to give the beholder the impression that he is looking down the barrel of a microscope at a well-mounted section."—*Annals of Surgery*, Philadelphia.

"It is the handsomest specimen of book-making \* \* \* that has ever been issued from the American medical press."—*American Journal of the Medical Sciences*, Philadelphia.

**PATHOLOGY AND SURGICAL TREATMENT OF TUMORS.**

By N. SENN, M. D., Ph. D., LL. D., Professor of Practice of Surgery and of Clinical Surgery, Rush Medical College; Professor of Surgery, Chicago Polyclinic; Attending Surgeon to Presbyterian Hospital; Surgeon-in-Chief, St. Joseph's Hospital, Chicago. One volume of 710 pages, with 515 engravings, including full-page colored plates. New and enlarged Edition in Preparation.

Books specially devoted to this subject are few, and in our text-books and systems of surgery this part of surgical pathology is usually condensed to a degree incompatible with its scientific and clinical importance. The author spent many years in collecting the material for this work, and has taken great pains to present it in a manner that should prove useful as a text-book for the student, a work of reference for the practitioner, and a reliable guide for the surgeon.

"The most exhaustive of any recent book in English on this subject. It is well illustrated, and will doubtless remain as the principal monograph on the subject in our language for some years. The book is handsomely illustrated and printed, . . . and the author has given a notable and lasting contribution to surgery."—*Journal of the American Medical Association*, Chicago.

**LECTURES ON RENAL AND URINARY DISEASES.** By

ROBERT SAUNDBY, M. D., Edin., Fellow of the Royal College of Physicians, London, and of the Royal Medico-Chirurgical Society; Physician to the General Hospital. Octavo volume of 434 pages, with numerous illustrations and 4 colored plates. Cloth, \$2.50 net.

"The volume makes a favorable impression at once. The style is clear and succinct. We cannot find any part of the subject in which the views expressed are not carefully thought out and fortified by evidence drawn from the most recent sources. The book may be cordially recommended."—*British Medical Journal*.



**A HANDBOOK FOR NURSES.** By J. K. WATSON, M.D., Edin., Assistant House-Surgeon, Sheffield Royal Hospital. American Edition, under the supervision of A. A. STEVENS, A.M., M.D., Professor of Pathology, Woman's Medical College, Philadelphia. 12mo, 413 pages, 73 illustrations. Cloth, \$1.50 net.

This work aims to supply in one volume that information which so many nurses at the present time are trying to extract from various medical works, and to present that information in a suitable form. Nurses must necessarily acquire a certain amount of medical knowledge, and the author of this book has aimed judiciously to cater to this need with the object of directing the nurses' pursuit of medical information in proper and legitimate channels. The book represents an entirely new departure in nursing literature, inasmuch as it contains useful information on medical and surgical matters hitherto only to be obtained from expensive works written expressly for medical men.

**A NEW PRONOUNCING DICTIONARY OF MEDICINE,** with Phonetic Pronunciation, Accentuation, Etymology, etc. By JOHN M. KEATING, M.D., LL.D., Fellow of the College of Physicians of Philadelphia; Editor "Cyclopædia of the Diseases of Children," etc.; and HENRY HAMILTON, with the Collaboration of J. CHALMERS DACOSTA, M.D., and FREDERICK A. PACKARD, M.D. One very attractive volume of over 800 pages. Second Revised Edition. Prices: Cloth, \$5.00 net; Sheep or Half-Morocco, \$6.00 net; with Denison's Patent Ready-Reference Index; without patent index, Cloth, \$4.00 net; Sheep or Half-Morocco, \$5.00 net.

#### PROFESSIONAL OPINIONS.

"I am much pleased with Keating's Dictionary, and shall take pleasure in recommending it to my classes."

HENRY M. LYMAN, M.D.,

*Professor of Principles and Practice of Medicine, Rush Medical College, Chicago, Ill.*

"I am convinced that it will be a very valuable adjunct to my study-table, convenient in size and sufficiently full for ordinary use."

C. A. LINDSLEY, M.D.,

*Professor of Theory and Practice of Medicine, Medical Dept. Yale University;  
Secretary Connecticut State Board of Health, New Haven, Conn.*

**AUTOBIOGRAPHY OF SAMUEL D. GROSS, M.D.,** Emeritus Professor of Surgery in the Jefferson Medical College of Philadelphia, with Reminiscences of His Times and Contemporaries. Edited by his sons, SAMUEL W. GROSS, M.D., LL.D., and A. HALLER GROSS, A.M., of the Philadelphia Bar. Preceded by a Memoir of Dr. Gross, by the late Austin Flint, M.D., LL.D. In two handsome volumes, each containing over 400 pages, demy 8vo, extra cloth, gilt tops, with fine Frontispiece engraved on steel. Price per Volume, \$2.50 net.

**PRACTICAL POINTS IN NURSING.** For Nurses in Private Practice. By EMILY A. M. STONEY, Graduate of the Training-School for Nurses, Lawrence, Mass.; Superintendent of the Training-School for Nurses, Carney Hospital, South Boston, Mass. 456 pages, handsomely illustrated with 73 engravings in the text, and 9 colored and half-tone plates. Cloth. Price, \$1.75 net.

**SECOND EDITION, THOROUGHLY REVISED.**

In this volume the author explains, in popular language and in the shortest possible form, the entire range of *private* nursing as distinguished from *hospital* nursing, and the nurse is instructed how best to meet the various emergencies of medical and surgical cases when distant from medical or surgical aid or when thrown on her own resources.

An especially valuable feature of the work will be found in the directions to the nurse how to *improvise* everything ordinarily needed in the sick-room, where the embarrassment of the nurse, owing to the want of proper appliances, is frequently extreme.

The work has been logically divided into the following sections :

- I. The Nurse : her responsibilities, qualifications, equipment, etc.
- II. The Sick-Room : its selection, preparation, and management.
- III. The Patient : duties of the nurse in medical, surgical, obstetric, and gynecologic cases.
- IV. Nursing in Accidents and Emergencies.
- V. Nursing in Special Medical Cases.
- VI. Nursing of the New-born and Sick Children.
- VII. Physiology and Descriptive Anatomy.

The APPENDIX contains much information in compact form that will be found of great value to the nurse, including Rules for Feeding the Sick; Recipes for Invalid Foods and Beverages; Tables of Weights and Measures; Table for Computing the Date of Labor; List of Abbreviations; Dose-List; and a full and complete Glossary of Medical Terms and Nursing Treatment.

"This is a well-written, eminently practical volume, which covers the entire range of private nursing as distinguished from hospital nursing, and instructs the nurse how best to meet the various emergencies which may arise and how to prepare everything ordinarily needed in the illness of her patient."—*American Journal of Obstetrics and Diseases of Women and Children*, Aug., 1896.

**A TEXT-BOOK OF BACTERIOLOGY**, including the Etiology and Prevention of Infective Diseases and an account of Yeasts and Moulds, Hæmatozoa, and Psorosperms. By EDGAR M. CROOKSHANK, M. B., Professor of Comparative Pathology and Bacteriology, King's College, London. A handsome octavo volume of 700 pages, with 273 engravings in the text, and 22 original and colored plates. Price, \$6.50 net.

This book, though nominally a Fourth Edition of Professor Crookshank's "MANUAL OF BACTERIOLOGY," is practically a new work, the old one having been reconstructed, greatly enlarged, revised throughout, and largely rewritten, forming a text-book for the Bacteriological Laboratory, for Medical Officers of Health, and for Veterinary Inspectors.

**MEDICAL DIAGNOSIS.** By Dr. OSWALD VIERORDT, Professor of Medicine at the University of Heidelberg. Translated, with additions, from the Fifth Enlarged German Edition, with the author's permission, by FRANCIS H. STUART, A. M., M. D. In one handsome royal-octavo volume of 600 pages. 194 fine wood-cuts in the text, many of them in colors. Prices: Cloth, \$4.00 net; Sheep or Half-Morocco, \$5.00 net.

**FOURTH AMERICAN EDITION, FROM THE FIFTH REVISED AND ENLARGED GERMAN EDITION.**

In this work, as in no other hitherto published, are given full and accurate explanations of the phenomena observed at the bedside. It is distinctly a clinical work by a master teacher, characterized by thoroughness, fulness, and accuracy. It is a mine of information upon the points that are so often passed over without explanation. Especial attention has been given to the germ-theory as a factor in the origin of disease.

The present edition of this highly successful work has been translated from the fifth German edition. Many alterations have been made throughout the book, but especially in the sections on Gastric Digestion and the Nervous System.

It will be found that all the qualities which served to make the earlier editions so acceptable have been developed with the evolution of the work to its present form.

**THE PICTORIAL ATLAS OF SKIN DISEASES AND SYPHILITIC AFFECTIONS.** (American Edition.) Translation from the French. Edited by J. J. PRINGLE, M. B., F. R. C. P., Assistant Physician to, and Physician to the department for Diseases of the Skin at, the Middlesex Hospital, London. Photo-lithochromes from the famous models of dermatological and syphilitic cases in the Museum of the Saint-Louis Hospital, Paris, with explanatory wood-cuts and letter-press. In 12 Parts, at \$3.00 per Part.

"Of all the atlases of skin diseases which have been published in recent years, the present one promises to be of greatest interest and value, especially from the standpoint of the general practitioner."—*American Medico-Surgical Bulletin*, Feb. 22, 1896.

"The introduction of explanatory wood-cuts in the text is a novel and most important feature which greatly furthers the easier understanding of the excellent plates, than which nothing, we venture to say, has been seen better in point of correctness, beauty, and general merit."—*New York Medical Journal*, Feb. 15, 1896.

"An interesting feature of the Atlas is the descriptive text, which is written for each picture by the physician who treated the case or at whose instigation the models have been made. We predict for this truly beautiful work a large circulation in all parts of the medical world where the names *St. Louis* and *Baretta* have preceded it."—*Medical Record*, N. Y., Feb. 1, 1896.

**A TEXT-BOOK OF MECHANO-THERAPY (MASSAGE AND MEDICAL GYMNASTICS).** By AXEL V. GRAFSTROM, B. Sc., M. D., late Lieutenant in the Royal Swedish Army; late House Physician, City Hospital, Blackwell's Island, New York. 12mo, 139 pages, illustrated. Cloth, \$1.00 net.

**DISEASES OF THE EYE. A Hand-Book of Ophthalmic Practice.** By G. E. DE SCHWEINITZ, M. D., Professor of Ophthalmology in the Jefferson Medical College, Philadelphia, etc. A handsome royal-octavo volume of 696 pages, with 255 fine illustrations, many of which are original, and 2 chromo-lithographic plates. Prices: Cloth, \$4.00 net; Sheep or Half-Morocco, \$5.00 net.

### THIRD EDITION, THOROUGHLY REVISED.

In the third edition of this text-book, destined, it is hoped, to meet the favorable reception which has been accorded to its predecessors, the work has been revised thoroughly, and much new matter has been introduced. Particular attention has been given to the important relations which micro-organisms bear to many ocular diseases. A number of special paragraphs on new subjects have been introduced, and certain articles, including a portion of the chapter on Operations, have been largely rewritten, or at least materially changed. A number of new illustrations have been added. The Appendix contains a full description of the method of determining the corneal astigmatism with the ophthalmometer of Javal and Schiötz, and the rotation of the eyes with the tropometer of Stevens.

"A work that will meet the requirements not only of the specialist, but of the general practitioner in a rare degree. I am satisfied that unusual success awaits it."

WILLIAM PEPPER, M. D.

*Provost and Professor of Theory and Practice of Medicine and Clinical Medicine in the University of Pennsylvania.*

"A clearly written, comprehensive manual. . . . One which we can commend to students as a reliable text-book, written with an evident knowledge of the wants of those entering upon the study of this special branch of medical science."—*British Medical Journal*.

"It is hardly too much to say that for the student and practitioner beginning the study of Ophthalmology, it is the best single volume at present published."—*Medical News*.

"It is a very useful, satisfactory, and safe guide for the student and the practitioner, and one of the best works of this scope in the English language."—*Annals of Ophthalmology*.

**DISEASES OF WOMEN.** By J. BLAND SUTTON, F. R. C. S., Assistant Surgeon to Middlesex Hospital, and Surgeon to Chelsea Hospital, London; and ARTHUR E. GILES, M. D., B. Sc., Lond., F. R. C. S., Edin., Assistant Surgeon to Chelsea Hospital, London. 436 pages, handsomely illustrated. Cloth, \$2.50 net.

The authors have placed in the hands of the physician and student a concise yet comprehensive guide to the study of gynecology in its most modern development. It has been their aim to relate facts and describe methods belonging to the science and art of gynecology in a way that will prove useful to students for examination purposes, and which will also enable the general physician to practice this important department of surgery with advantage to his patients and with satisfaction to himself.

"The book is very well prepared, and is certain to be well received by the medical public."—*British Medical Journal*.

"The text has been carefully prepared. Nothing essential has been omitted, and its teachings are those recommended by the leading authorities of the day."—*Journal of the American Medical Association*.



**TEXT-BOOK UPON THE PATHOGENIC BACTERIA.** Specially written for Students of Medicine. By JOSEPH MCFARLAND, M. D., Professor of Pathology and Bacteriology in the Medico-Chirurgical College of Philadelphia, etc. 497 pages, finely illustrated. Price, Cloth, \$2.50 net.

**SECOND EDITION, REVISED AND GREATLY ENLARGED.**

The work is intended to be a text-book for the medical student and for the practitioner who has had no recent laboratory training in this department of medical science. The instructions given as to needed apparatus, cultures, stainings, microscopic examinations, etc. are ample for the student's needs, and will afford to the physician much information that will interest and profit him relative to a subject which modern science shows to go far in explaining the etiology of many diseased conditions.

In this second edition the work has been brought up to date in all departments of the subject, and numerous additions have been made to the technique in the endeavor to make the book fulfil the double purpose of a systematic work upon bacteria and a laboratory guide.

"It is excellently adapted for the medical students and practitioners for whom it is avowedly written. . . . The descriptions given are accurate and readable, and the book should prove useful to those for whom it is written.—*London Lancet*, Aug. 29, 1896.

"The author has succeeded admirably in presenting the essential details of bacteriological technics, together with a judiciously chosen summary of our present knowledge of pathogenic bacteria. . . . The work, we think, should have a wide circulation among English-speaking students of medicine."—*N. Y. Medical Journal*, April 4, 1896.

"The book will be found of considerable use by medical men who have not had a special bacteriological training, and who desire to understand this important branch of medical science."—*Edinburgh Medical Journal*, July, 1896.

**LABORATORY GUIDE FOR THE BACTERIOLOGIST.** By

LANGDON FROTHINGHAM, M. D. V., Assistant in Bacteriology and Veterinary Science, Sheffield Scientific School, Yale University. Illustrated. Price, Cloth, 75 cents.

The technical methods involved in bacteria-culture, methods of staining, and microscopical study are fully described and arranged as simply and concisely as possible. The book is especially intended for use in laboratory work.

"It is a convenient and useful little work, and will more than repay the outlay necessary for its purchase in the saving of time which would otherwise be consumed in looking up the various points of technique so clearly and concisely laid down in its pages."—*American Med. Surg. Bulletin*.

**FEEDING IN EARLY INFANCY.** By ARTHUR V. MEIGS, M. D.

Bound in limp cloth, flush edges. Price, 25 cents net.

**SYNOPSIS:** Analyses of Milk—Importance of the Subject of Feeding in Early Infancy—Proportion of Casein and Sugar in Human Milk—Time to Begin Artificial Feeding of Infants—Amount of Food to be Administered at Each Feeding—Intervals between Feedings—Increase in Amount of Food at Different Periods of Infant Development—Unsuitableness of Condensed Milk as a Substitute for Mother's Milk—Objections to Sterilization or "Pasteurization" of Milk—Advances made in the Method of Artificial Feeding of Infants.



**MATERIA MEDICA FOR NURSES.** By EMILY A. M. STONEY, Graduate of the Training-school for Nurses, Lawrence, Mass.; late Superintendent of the Training-school for Nurses, Carney Hospital, South Boston, Mass. Handsome octavo, 300 pages. Cloth, \$1.50 net.

The present book differs from other similar works in several features, all of which are introduced to render it more practical and generally useful. The general plan of contents follows the lines laid down in training-schools for nurses, but the book contains much useful matter not usually included in works of this character, such as Poison-emergencies, Ready Dose-list, Weights and Measures, etc., as well as a Glossary, defining all the terms in *Materia Medica*, and describing all the latest drugs and remedies, which have been generally neglected by other books of the kind.

**ESSENTIALS OF ANATOMY AND MANUAL OF PRACTICAL DISSECTION**, containing "Hints on Dissection." By CHARLES B. NANCREDÉ, M. D., Professor of Surgery and Clinical Surgery in the University of Michigan, Ann Arbor; Corresponding Member of the Royal Academy of Medicine, Rome, Italy; late Surgeon Jefferson Medical College, etc. Fourth and revised edition. Post 8vo, over 500 pages, with handsome full-page lithographic plates in colors, and over 200 illustrations. Price: Extra Cloth or Oilcloth for the dissection-room, \$2.00 net.

Neither pains nor expense has been spared to make this work the most exhaustive yet concise Student's Manual of Anatomy and Dissection ever published, either in America or in Europe.

The colored plates are designed to aid the student in dissecting the muscles, arteries, veins, and nerves. The wood-cuts have all been specially drawn and engraved, and an Appendix added containing 60 illustrations representing the structure of the entire human skeleton, the whole being based on the eleventh edition of Gray's *Anatomy*.

**A MANUAL OF PRACTICE OF MEDICINE.** By A. A. STEVENS, A. M., M. D., Instructor in Physical Diagnosis in the University of Pennsylvania, and Professor of Pathology in the Woman's Medical College of Pennsylvania. Specially intended for students preparing for graduation and hospital examinations. Post 8vo, 519 pages. Numerous illustrations and selected formulæ. Price, bound in flexible leather, \$2.00 net.

#### FIFTH EDITION, REVISED AND ENLARGED.

Contributions to the science of medicine have poured in so rapidly during the last quarter of a century that it is well-nigh impossible for the student, with the limited time at his disposal, to master elaborate treatises or to cull from them that knowledge which is absolutely essential. From an extended experience in teaching, the author has been enabled, by classification, to group allied symptoms, and by the judicious elimination of theories and redundant explanations to bring within a comparatively small compass a complete outline of the practice of medicine.

**MANUAL OF MATERIA MEDICA AND THERAPEUTICS.**

By A. A. STEVENS, A. M., M. D., Instructor of Physical Diagnosis in the University of Pennsylvania, and Professor of Pathology in the Woman's Medical College of Pennsylvania. 445 pages. Price, bound in flexible leather, \$2.25.

**SECOND EDITION, REVISED.**

This wholly new volume, which is based on the last edition of the *Pharmacopœia*, comprehends the following sections: Physiological Action of Drugs; Drugs; Remedial Measures other than Drugs; Applied Therapeutics; Incompatibility in Prescriptions; Table of Doses; Index of Drugs; and Index of Diseases; the treatment being elucidated by more than two hundred formulæ.

"The author is to be congratulated upon having presented the medical student with as accurate a manual of therapeutics as it is possible to prepare."—*Therapeutic Gazette*.

"Far superior to most of its class; in fact, it is very good. Moreover, the book is reliable and accurate."—*New York Medical Journal*.

"The author has faithfully presented modern therapeutics in a comprehensive work, . . . and it will be found a reliable guide."—*University Medical Magazine*.

**NOTES ON THE NEWER REMEDIES: their Therapeutic Applications and Modes of Administration.** By DAVID CERNA, M. D., PH. D., Demonstrator of and Lecturer on Experimental Therapeutics in the University of Pennsylvania. Post-octavo, 253 pages. Price, \$1.25.

**SECOND EDITION, RE-WRITTEN AND GREATLY ENLARGED.**

The work takes up in alphabetical order all the newer remedies, giving their physical properties, solubility, therapeutic applications, administration, and chemical formula.

It thus forms a very valuable addition to the various works on therapeutics now in existence.

Chemists are so multiplying compounds, that, if each compound is to be thoroughly studied, investigations must be carried far enough to determine the practical importance of the new agents.

"Especially valuable because of its completeness, its accuracy, its systematic consideration of the properties and therapy of many remedies of which doctors generally know but little, expressed in a brief yet terse manner."—*Chicago Clinical Review*.

**TEMPERATURE CHART.** Prepared by D. T. LAINÉ, M. D. Size 8 × 13½ inches. Price, per pad of 25 charts, 50 cents.

A conveniently arranged chart for recording Temperature, with columns for daily amounts of Urinary and Fecal Excretions, Food, Remarks, etc. On the back of each chart is given in full the method of Brand in the treatment of Typhoid Fever.

**A TEXT-BOOK OF HISTOLOGY, DESCRIPTIVE AND PRACTICAL.** For the Use of Students. By ARTHUR CLARKSON, M. B., C. M., Edin., formerly Demonstrator of Physiology in the Owen's College, Manchester; late Demonstrator of Physiology in the Yorkshire College, Leeds. Large 8vo, 554 pages, with 22 engravings in the text, and 174 beautifully colored original illustrations. Price, strongly bound in Cloth, \$4.00 net.

The purpose of the writer in this work has been to furnish the student of Histology, in one volume, with both the descriptive and the practical part of the science. The first two chapters are devoted to the consideration of the general methods of Histology; subsequently, in each chapter, the structure of the tissue or organ is first systematically described, the student is then taken tutorially over the specimens illustrating it, and, finally, an appendix affords a short note of the methods of preparation.

"The work must be considered a valuable addition to the list of available text-books, and is to be highly recommended."—*New York Medical Journal*.

"One of the best works for students we have ever noticed. We predict that the book will attain a well-deserved popularity among our students."—*Chicago Medical Recorder*.

**THE PATHOLOGY AND TREATMENT OF SEXUAL IMPOTENCE.** By VICTOR G. VECKI, M. D. From the second German edition, revised and rewritten. Demi-octavo, about 300 pages. Cloth, \$2.00 net.

The subject of impotence has but seldom been treated in this country in the truly scientific spirit that it deserves, and this volume will come to many as a revelation of the possibilities of therapeusis in this important field. Dr. Vecki's work has long been favorably known, and the German book has received the highest consideration. This edition is more than a mere translation, for, although based on the German edition, it has been entirely rewritten by the author in English.

"The work can be recommended as a scholarly treatise on its subject, and it can be read with advantage by many practitioners."—*Journal of the American Medical Association*.

**THE TREATMENT OF PELVIC INFLAMMATIONS THROUGH THE VAGINA.** By W. R. PRYOR, M.D., Professor of Gynecology in the New York Polyclinic. 12mo, 248 pages, handsomely illustrated. Cloth, \$2.00 net.

In this book the author directs the attention of the general practitioner to a surgical treatment of the pelvic diseases of women. There exists the utmost confusion in the profession regarding the most successful methods of treating pelvic inflammations; and inasmuch as inflammatory lesions constitute the majority of all pelvic diseases, the subject is an important one. It has been the endeavor of the author to put down every little detail, no matter how insignificant, which might be of service.

**DISEASES OF WOMEN.** By HENRY J. GARRIGUES, A.M., M.D., Professor of Gynecology in the New York School of Clinical Medicine; Gynecologist to St. Mark's Hospital and to the German Dispensary, New York City. In one handsome octavo volume of 728 pages, illustrated by 335 engravings and colored plates. Prices: Cloth, \$4.00 net; Sheep or Half-Morocco, \$5.00 net.

A PRACTICAL work on gynecology for the use of students and practitioners, written in a terse and concise manner. The importance of a thorough knowledge of the anatomy of the female pelvic organs has been fully recognized by the author, and considerable space has been devoted to the subject. The chapters on Operations and on Treatment are thoroughly modern, and are based upon the large hospital and private practice of the author. The text is elucidated by a large number of illustrations and colored plates, many of them being original, and forming a complete atlas for studying *embryology* and the *anatomy* of the *female genitalia*, besides exemplifying, whenever needed, morbid conditions, instruments, apparatus, and operations.

### *Second Edition, Thoroughly Revised.*

The first edition of this work met with a most appreciative reception by the medical press and profession both in this country and abroad, and was adopted as a text-book or recommended as a book of reference by nearly *one hundred* colleges in the United States and Canada. The author has availed himself of the opportunity afforded by this revision to embody the latest approved advances in the treatment employed in this important branch of Medicine. He has also more extensively expressed his own opinion on the comparative value of the different methods of treatment employed.

"One of the best text-books for students and practitioners which has been published in the English language; it is condensed, clear, and comprehensive. The profound learning and great clinical experience of the distinguished author find expression in this book in a most attractive and instructive form. Young practitioners, to whom experienced consultants may not be available, will find in this book invaluable counsel and help."

THAD. A. REAMY, M.D., LL.D.,

*Professor of Clinical Gynecology, Medical College of Ohio; Gynecologist to the Good Samaritan and Cincinnati Hospitals.*

**A SYLLABUS OF GYNECOLOGY**, arranged in conformity with "An American Text-Book of Gynecology." By J. W. LONG, M.D., Professor of Diseases of Women and Children, Medical College of Virginia, etc. Price, Cloth (interleaved), \$1.00 net.

Based upon the teaching and methods laid down in the larger work, this will not only be useful as a supplementary volume, but to those who do not already possess the text-book it will also have an independent value as an aid to the practitioner in gynecological work, and to the student as a guide in the lecture-room, as the subject is presented in a manner at once systematic, clear, succinct, and practical.



**THE AMERICAN POCKET MEDICAL DICTIONARY.** Edited by W. A. NEWMAN DORLAND, M. D., Assistant Obstetrician to the Hospital of the University of Pennsylvania; Fellow of the American Academy of Medicine. Containing the pronunciation and definition of all the principal words used in medicine and the kindred sciences, with 64 extensive tables. Handsomely bound in flexible leather, limp, with gold edges and patent thumb index. Price, \$1.00 net; with thumb index, \$1.25 net.

#### SECOND EDITION, REVISED.

This is the ideal pocket lexicon. It is an absolutely new book, and not a revision of any old work. It is complete, defining all the terms of modern medicine and forming an unusually complete vocabulary. It gives the pronunciation of all the terms. It makes a special feature of the newer words neglected by other dictionaries. It contains a wealth of anatomical tables of special value to students. It forms a handy volume, indispensable to every medical man.

**SAUNDERS' POCKET MEDICAL FORMULARY.** By WILLIAM M. POWELL, M. D., Attending Physician to the Mercer House for Invalid Women at Atlantic City. Containing 1800 Formulæ, selected from several hundred of the best-known authorities. Forming a handsome and convenient pocket companion of nearly 300 printed pages, with blank leaves for Additions; with an Appendix containing Posological Table, Formulæ and Doses for Hypodermatic Medication, Poisons and their Antidotes, Diameters of the Female Pelvis and Fœtal Head, Obstetrical Table, Diet List for Various Diseases, Materials and Drugs used in Antiseptic Surgery, Treatment of Asphyxia from Drowning, Surgical Remembrancer, Tables of Incompatibles, Eruptive Fevers, Weights and Measures, etc. Handsomely bound in morocco, with side index, wallet, and flap. Price, \$1.75 net.

#### FIFTH EDITION, THOROUGHLY REVISED.

"This little book, that can be conveniently carried in the pocket, contains an immense amount of material. It is very useful, and as the name of the author of each prescription is given, is unusually reliable."—*New York Medical Record*.

**A COMPENDIUM OF INSANITY.** By JOHN B. CHAPIN, M.D., LL.D., Physician-in-Chief, Pennsylvania Hospital for the Insane; late Physician-Superintendent of the Willard State Hospital, New York; Honorary Member of the Medico-Psychological Society of Great Britain, of the Society of Mental Medicine of Belgium. 12mo, 234 pages, illust. Cloth, \$1.25 net.

The author has given, in a condensed and concise form, a compendium of Diseases of the Mind, for the convenient use and aid of physicians and students. It contains a clear, concise statement of the clinical aspects of the various abnormal mental conditions, with directions as to the most approved methods of managing and treating the insane.

"The practical parts of Dr. Chapin's book are what constitute its distinctive merit. We desire especially, however, to call attention to the fact that in the subject of the therapeutics of insanity the work is exceedingly valuable. The author has made a distinct addition to the literature of his specialty."—*Philadelphia Medical Journal*.



**AN OPERATION BLANK**, with Lists of Instruments, etc. required in Various Operations. Prepared by W. W. KEEN, M. D., LL.D., Professor of Principles of Surgery in the Jefferson Medical College, Philadelphia. Price per Pad, containing Blanks for fifty operations, 50 cents net.

**SECOND EDITION, REVISED FORM.**

A convenient blank, suitable for all operations, giving complete instructions regarding necessary preparation of patient, etc., with a full list of dressings and medicines to be employed.

On the back of each blank is a list of instruments used—viz. general instruments, etc., required for all operations; and special instruments for surgery of the brain and spine, mouth and throat, abdomen, rectum, male and female genito-urinary organs, the bones, etc.

The whole forming a neat pad, arranged for hanging on the wall of a surgeon's office or in the hospital operating-room.

"Will serve a useful purpose for the surgeon in reminding him of the details of preparation for the patient and the room as well as for the instruments, dressings, and antiseptics needed."—*New York Medical Record*

"Covers about all that can be needed in any operation."—*American Lancet*.

"The plan is a capital one."—*Boston Medical and Surgical Journal*.

**LABORATORY EXERCISES IN BOTANY.** By EDSON S. BASTIN, M. A., Professor of Materia Medica and Botany in the Philadelphia College of Pharmacy. Octavo volume of 536 pages, 87 full-page plates. Price, Cloth, \$2.50.

This work is intended for the beginner and the advanced student, and it fully covers the structure of flowering plants, roots, ordinary stems, rhizomes, tubers, bulbs, leaves, flowers, fruits, and seeds. Particular attention is given to the gross and microscopical structure of plants, and to those used in medicine. Illustrations have freely been used to elucidate the text, and a complete index to facilitate reference has been added.

"There is no work like it in the pharmaceutical or botanical literature of this country, and we predict for it a wide circulation."—*American Journal of Pharmacy*.

**DIET IN SICKNESS AND IN HEALTH.** By MRS. ERNEST HART, formerly Student of the Faculty of Medicine of Paris and of the London School of Medicine for Women; with an INTRODUCTION by Sir Henry Thompson, F. R. C. S., M. D., London. 220 pages; illustrated. Price, Cloth, \$1.50.

Useful to those who have to nurse, feed, and prescribe for the sick. In each case the accepted causation of the disease and the reasons for the special diet prescribed are briefly described. Medical men will find the dietaries and recipes practically useful, and likely to save them trouble in directing the dietetic treatment of patients.

**A MANUAL OF PHYSIOLOGY, with Practical Exercises. For Students and Practitioners.** By G. N. STEWART, M. A., M. D., D. Sc., lately Examiner in Physiology, University of Aberdeen, and of the New Museums, Cambridge University; Professor of Physiology in the Western Reserve University, Cleveland, Ohio. Handsome octavo volume of 848 pages, with 300 illustrations in the text, and 5 colored plates. Price, Cloth, \$3.75 net.

**THIRD EDITION, REVISED.**

"It will make its way by sheer force of merit, and *amply deserves to do so. It is one of the very best English text-books on the subject.*"—*London Lancet.*

"Of the many text-books of physiology published, we do not know of one that so nearly comes up to the ideal as does Professor Stewart's volume."—*British Medical Journal.*

**ESSENTIALS OF PHYSICAL DIAGNOSIS OF THE THORAX.**

By ARTHUR M. CORWIN, A. M., M. D., Demonstrator of Physical Diagnosis in the Rush Medical College, Chicago; Attending Physician to the Central Free Dispensary, Department of Rhinology, Laryngology, and Diseases of the Chest. 219 pages. Illustrated. Cloth, flexible covers. Price, \$1.25 net.

**THIRD EDITION, THOROUGHLY REVISED AND ENLARGED.**

**SYLLABUS OF OBSTETRICAL LECTURES** in the Medical Department, University of Pennsylvania. By RICHARD C. NORRIS, A. M., M. D., Lecturer on Clinical and Operative Obstetrics, University of Pennsylvania. Third edition, thoroughly revised and enlarged. Crown 8vo. Price, Cloth, interleaved for notes, \$2.00 net.

"This work is so far superior to others on the same subject that we take pleasure in calling attention briefly to its excellent features. It covers the subject thoroughly, and will prove invaluable both to the student and the practitioner. The author has introduced a number of valuable hints which would only occur to one who was himself an experienced teacher of obstetrics. The subject-matter is clear, forcible, and modern. We are especially pleased with the portion devoted to the practical duties of the accoucheur, care of the child, etc. The paragraphs on antiseptics are admirable; there is no doubtful tone in the directions given. No details are regarded as unimportant; no minor matters omitted. We venture to say that even the old practitioner will find useful hints in this direction which he cannot afford to despise."—*New York Medical Record.*

**A SYLLABUS OF LECTURES ON THE PRACTICE OF SURGERY,** arranged in conformity with "An American Text-Book of Surgery." By N. SENN, M. D., PH. D., Professor of Surgery in Rush Medical College, Chicago, and in the Chicago Polyclinic. Price, \$2.00.

This work by so eminent an author, himself one of the contributors to "An American Text-Book of Surgery," will prove of exceptional value to the advanced student who has adopted that work as his text-book. It is not only the syllabus of an unrivalled course of surgical practice, but it is also an epitome of or supplement to the larger work.

"The author has evidently spared no pains in making his Syllabus thoroughly comprehensive, and has added new matter and alluded to the most recent authors and operations. Full references are also given to all requisite details of surgical anatomy and pathology."—*British Medical Journal*, London.

**THE CARE OF THE BABY.** By J. P. CROZER GRIFFITH, M. D., Clinical Professor of Diseases of Children, University of Pennsylvania; Physician to the Children's Hospital, Philadelphia, etc. 404 pages, with 67 illustrations in the text, and 5 plates. 12mo. Price, \$1.50.

**SECOND EDITION, REVISED.**

A reliable guide not only for mothers, but also for medical students and practitioners whose opportunities for observing children have been limited.

"The whole book is characterized by rare good sense, and is evidently written by a master hand. It can be read with benefit not only by mothers, but by medical students and by any practitioners who have not had large opportunities for observing children."—*American Journal of Obstetrics*.

**THE NURSE'S DICTIONARY of Medical Terms and Nursing Treatment**, containing Definitions of the Principal Medical and Nursing Terms, Abbreviations, and Physiological Names, and Descriptions of the Instruments, Drugs, Diseases, Accidents, Treatments, Operations, Foods, Appliances, etc. encountered in the ward or the sick-room. By HONNOR MORTEN, author of "How to Become a Nurse," "Sketches of Hospital Life," etc. 16mo, 140 pages. Price, Cloth, \$1.00.

This little volume is intended for use merely as a small reference-book which can be consulted at the bedside or in the ward. It gives sufficient explanation to the nurse to enable her to comprehend a case until she has leisure to look up larger and fuller works on the subject.

**DIET LISTS AND SICK-ROOM DIETARY.** By JEROME B. THOMAS, M. D., Visiting Physician to the Home for Friendless Women and Children and to the Newsboys' Home; Assistant Visiting Physician to the Kings County Hospital; Assistant Bacteriologist, Brooklyn Health Department. Price, Cloth, \$1.50 (Send for specimen List.)

One hundred and sixty detachable (perforated) diet lists for Albuminuria, Anæmia and Debility, Constipation, Diabetes, Diarrhœa, Dyspepsia, Fevers, Gout or Uric-Acid Diathesis, Obesity, and Tuberculosis. Also forty detachable sheets of Sick-Room Dietary, containing full instructions for preparation of easily-digested foods necessary for invalids. Each list is *numbered only*, the disease for which it is to be used in no case being mentioned, an index key being reserved for the physician's private use.

**DIETS FOR INFANTS AND CHILDREN IN HEALTH AND IN DISEASE.** By LOUIS STARR, M. D., Editor of "An American Text-Book of the Diseases of Children." 230 blanks (pocket-book size), perforated and neatly bound in flexible morocco. Price, \$1.25 net.

The first series of blanks are prepared for the first seven months of infant life; each blank indicates the ingredients, but not the *quantities*, of the food, the latter directions being left for the physician. After the seventh month, modifications being less necessary, the diet lists are printed in full. *Formula* to the preparation of diluents and foods are appended.

**HOW TO EXAMINE FOR LIFE INSURANCE.** By JOHN M. KEATING, M. D., Fellow of the College of Physicians and Surgeons of Philadelphia; Vice-President of the American Pædiatric Society; Ex-President of the Association of Life Insurance Medical Directors. Royal 8vo, 211 pages, with two large half-tone illustrations, and a plate prepared by Dr. McClellan from special dissections; also, numerous cuts to elucidate the text. Third edition. Price, Cloth, \$2.00 net.

"This is by far the most useful book which has yet appeared on insurance examination, a subject of growing interest and importance. Not the least valuable portion of the volume is Part II., which consists of instructions issued to their examining physicians by twenty-four representative companies of this country. As the proofs of these instructions were corrected by the directors of the companies, they form the latest instructions obtainable. If for these alone, the book should be at the right hand of every physician interested in this special branch of medical science."—*The Medical News*, Philadelphia.

**NURSING: ITS PRINCIPLES AND PRACTICE.** By ISABEL ADAMS HAMPTON, Graduate of the New York Training School for Nurses attached to Bellevue Hospital; Superintendent of Nurses and Principal of the Training School for Nurses, Johns Hopkins Hospital, Baltimore, Md.; late Superintendent of Nurses, Illinois Training School for Nurses, Chicago, Ill. In one very handsome 12mo volume of 512 pages, illustrated. Price, Cloth, \$2.00 net.

**SECOND EDITION, REVISED AND ENLARGED.**

This original work on the important subject of nursing is at once comprehensive and systematic. It is written in a clear, accurate, and readable style, suitable alike to the student and the lay reader. Such a work has long been a desideratum with those entrusted with the management of hospitals and the instruction of nurses in training-schools. It is also of especial value to the graduated nurse who desires to acquire a practical working knowledge of the care of the sick and the hygiene of the sick-room.


**OBSTETRIC ACCIDENTS, EMERGENCIES, AND OPERATIONS.** By L. CH. BOISLINIERE, M. D., late Emeritus Professor of Obstetrics in the St. Louis Medical College. 381 pages, handsomely illustrated. Price, \$2.00 net.

"For the use of the practitioner who, when away from home, has not the opportunity of consulting a library or of calling a friend in consultation. He then, being thrown upon his own resources, will find this book of benefit in guiding and assisting him in emergencies."

**INFANT'S WEIGHT CHART.** Designed by J. P. CROZER GRIFFITH, M. D., Clinical Professor of Diseases of Children in the University of Pennsylvania. 25 charts in each pad. Price per pad, 50 cents net.

A convenient blank for keeping a record of the child's weight during the first two years of life. Printed on each chart is a curve representing the average weight of a healthy infant, so that any deviation from the normal can readily be detected.





# SAUNDERS' NEW SERIES OF MANUALS

---

for Students  
and  
Practitioners.

THAT there exists a need for thoroughly reliable hand-books on the leading branches of Medicine and Surgery is a fact amply demonstrated by the favor with which the SAUNDERS NEW SERIES OF MANUALS have been received by medical students and practitioners and by the Medical Press. These manuals are not merely condensations from present literature, but are ably written by well-known authors and practitioners, most of them being teachers in representative American colleges. Each volume is concisely and authoritatively written and exhaustive in detail, without being encumbered with the introduction of "cases," which so largely expand the ordinary text-book. These manuals will therefore form an admirable collection of advanced lectures, useful alike to the medical student and the practitioner: to the latter, too busy to search through page after page of elaborate treatises for what he wants to know, they will prove of inestimable value; to the former they will afford safe guides to the essential points of study.

The SAUNDERS NEW SERIES OF MANUALS are conceded to be superior to any similar books now on the market. No other manuals afford so much information in such a concise and available form. A liberal expenditure has enabled the publisher to render the mechanical portion of the work worthy of the high literary standard attained by these books.

Any of these Manuals will be mailed on receipt of price (see next page for List).



# SAUNDERS' NEW SERIES OF MANUALS.

## VOLUMES PUBLISHED.

**PHYSIOLOGY.** By JOSEPH HOWARD RAYMOND, A. M., M. D., Professor of Physiology and Hygiene and Lecturer on Gynecology in the Long Island College Hospital, etc. Price, \$1.25 net.

**SURGERY, General and Operative.** By JOHN CHALMERS DACOSTA, M. D., Professor of Clinical Surgery, Jefferson Medical College, Philadelphia. Second edition, revised and greatly enlarged. Octavo, 911 pages, 386 illustrations. Cloth, \$4.00 net; Half-Morocco, \$5.00 net.

**DOSE-BOOK AND MANUAL OF PRESCRIPTION-WRITING.** By E. Q. THORNTON, M. D., Demonstrator of Therapeutics, Jefferson Medical College, Philadelphia. Price, \$1.25 net.

**MEDICAL JURISPRUDENCE.** By HENRY C. CHAPMAN, M. D., Professor of Institutes of Medicine and Medical Jurisprudence in the Jefferson Medical College of Philadelphia, etc. Price, \$1.50 net.

**SURGICAL ASEPSIS.** By CARL BECK, M. D., Surgeon to St. Mark's Hospital and to the German Poliklinik; Instructor in Surgery, New York Post-Graduate Medical School, etc. Price, \$1.25 net.

**MANUAL OF ANATOMY.** By IRVING S. HAYNES, M. D., Adjunct Professor of Anatomy and Demonstrator of Anatomy, Medical Department of the New York University, etc. Price, \$2.50 net.

**SYPHILIS AND THE VENEREAL DISEASES.** By JAMES NEVINS HYDE, M. D., Professor of Skin and Venereal Diseases, and FRANK H. MONTGOMERY, M. D., Lecturer on Dermatology and Genito-urinary Diseases in Rush Medical College, Chicago. Price, \$2.50 net.

**PRACTICE OF MEDICINE.** By GEORGE ROE LOCKWOOD, M. D., Professor of Practice in the Woman's Medical College of the New York Infirmary, etc. Price, \$2.50 net.

**OBSTETRICS.** By W. A. NEWMAN DORLAND, M. D., Assistant Demonstrator of Obstetrics, University of Pennsylvania; Chief of Gynecological Dispensary, Pennsylvania Hospital. Price, \$2.50 net.

**DISEASES OF WOMEN.** By J. BLAND SUTTON, F. R. C. S., Assistant Surgeon to the Middlesex Hospital, and Surgeon to the Chelsea Hospital for Women, London; and ARTHUR E. GILES, M. D., B. Sc. Lond., F. R. C. S. Edin., Assistant Surgeon to the Chelsea Hospital for Women, London. 436 pages, handsomely illustrated. Price, \$2.50 net.

## IN PREPARATION.

**NERVOUS DISEASES.** By CHARLES W. BURR, M. D., Clinical Professor of Nervous Diseases, Medico-Chirurgical College, Philadelphia, etc.

\*\*\* There will be published in the same series, at short intervals, carefully prepared works on various subjects, by prominent specialists.

# SAUNDERS' QUESTION COMPENDS.

Arranged in Question and Answer Form.

---

THE LATEST, MOST COMPLETE, and BEST ILLUSTRATED  
SERIES OF COMPENDS EVER ISSUED.

---

Now the Standard Authorities in Medical Literature

WITH

Students and Practitioners in every City of the United  
States and Canada.

---

## THE REASON WHY.

They are the advance guard of "Student's Helps"—that DO HELP; they are the leaders in their special line, *well and authoritatively written by able men, who, as teachers in the large colleges, know exactly what is wanted by a student preparing for his examinations.* The judgment exercised in the selection of authors is fully demonstrated by their professional elevation. Chosen from the ranks of Demonstrators, Quiz-masters, and Assistants, most of them have become Professors and Lecturers in their respective colleges.

Each book is of convenient size (5 × 7 inches), containing on an average 250 pages, profusely illustrated, and elegantly printed in clear, readable type, on fine paper.

The entire series, numbering twenty-four subjects, has been kept thoroughly revised and enlarged when necessary, many of them being in their fourth and fifth editions.

## TO SUM UP.

Although there are numerous other Quizzes, Manuals, Aids, etc. in the market, none of them approach the "Blue Series of Question Compendis;" and the claim is made for the following points of excellence:

1. Professional distinction and reputation of authors.
2. Conciseness, clearness, and soundness of treatment.
3. Size of type and quality of paper and binding.

\*.\* Any of these Compendis will be mailed on receipt of price (see next page for List).

# SAUNDERS' QUESTION-COMPEND SERIES.

Price, Cloth, \$1.00 per copy, except when otherwise noted.

1. **ESSENTIALS OF PHYSIOLOGY.** 4th edition. Illustrated. Revised and enlarged. By H. A. HARE, M. D. (Price, \$1.00 net.)
2. **ESSENTIALS OF SURGERY.** 7th edition, with a chapter on Appendicitis. 90 illustrations. By EDWARD MARTIN, M. D. (Price, \$1.00 net.)
3. **ESSENTIALS OF ANATOMY.** 6th edition, thoroughly revised. 151 illustrations. By CHARLES B. NANCREDÉ, M. D. (Price, \$1.00 net.)
4. **ESSENTIALS OF MEDICAL CHEMISTRY, ORGANIC AND INORGANIC.** 5th edition, revised, with an Appendix. By LAWRENCE WOLFF, M. D. (\$1.00 net.)
5. **ESSENTIALS OF OBSTETRICS.** 4th edition, revised and enlarged. 75 illustrations. By W. EASTERLY ASHTON, M. D.
6. **ESSENTIALS OF PATHOLOGY AND MORBID ANATOMY.** 7th thousand. 46 illustrations. By C. E. ARMAND SEMPLE, M. D.
7. **ESSENTIALS OF MATERIA MEDICA, THERAPEUTICS, AND PRESCRIPTION-WRITING.** 5th edition. By HENRY MORRIS, M. D.
- 8, 9. **ESSENTIALS OF PRACTICE OF MEDICINE.** By HENRY MORRIS, M. D. An Appendix on URINE EXAMINATION. Illustrated. By LAWRENCE WOLFF, M. D. 3d edition, enlarged by some 300 Essential Formulæ, selected from eminent authorities, by WM. M. POWELL, M. D. (Double number, price \$2.00.)
10. **ESSENTIALS OF GYNÆCOLOGY.** 4th edition, revised. With 62 illustrations. By EDWIN B. CRAGIN, M. D.
11. **ESSENTIALS OF DISEASES OF THE SKIN.** 4th edition, revised and enlarged. 71 letter-press cuts and 15 half-tone illustrations. By HENRY W. STELWAGON, M. D. (Price, \$1.00 net.)
12. **ESSENTIALS OF MINOR SURGERY, BANDAGING, AND VENEREAL DISEASES.** 2d edition, revised and enlarged. 78 illustrations. By EDWARD MARTIN, M. D.
13. **ESSENTIALS OF LEGAL MEDICINE, TOXICOLOGY, AND HYGIENE.** 130 illustrations. By C. E. ARMAND SEMPLE, M. D.
14. **ESSENTIALS OF DISEASES OF THE EYE, NOSE, AND THROAT.** 124 illustrations. 2d edition, revised. By EDWARD JACKSON, M. D., and E. BALDWIN GLEASON, M. D.
15. **ESSENTIALS OF DISEASES OF CHILDREN.** 2d edition. By WILLIAM M. POWELL, M. D.
16. **ESSENTIALS OF EXAMINATION OF URINE.** Colored "VOGEL SCALE," and numerous illustrations. By LAWRENCE WOLFF, M. D. (Price, 75 cents.)
17. **ESSENTIALS OF DIAGNOSIS.** 2d edition, thoroughly revised. 60 illustrations. By S. SOLIS-COHEN, M. D., and A. A. ESHNER, M. D. (Price, \$1.00 net.)
18. **ESSENTIALS OF PRACTICE OF PHARMACY.** 2d edition, revised. By L. E. SAYRE.
20. **ESSENTIALS OF BACTERIOLOGY.** 3d edition. 82 illustrations. By M. V. BALL, M. D.
21. **ESSENTIALS OF NERVOUS DISEASES AND INSANITY.** 48 illustrations. 3d edition, revised. By JOHN C. SHAW, M. D.
22. **ESSENTIALS OF MEDICAL PHYSICS.** 155 illustrations. 2d edition, revised. By FRED J. BROCKWAY, M. D. (Price, \$1.00 net.)
23. **ESSENTIALS OF MEDICAL ELECTRICITY.** 65 illustrations. By DAVID D. STEWART, M. D., and EDWARD S. LAWRENCE, M. D.
24. **ESSENTIALS OF DISEASES OF THE EAR.** 114 illustrations. 2d edition, revised and enlarged. By E. BALDWIN GLEASON, M. D.

## Some of the Books in Preparation for Publication during 1900.

### **AMERICAN Text-Book of Pa- thology.**

Edited by LUDVIG HEKTOEN, M.D., Professor of Pathology, Rush Medical College, Chicago; and DAVID RIESMAN, M.D., Demonstrator of Pathological Histology, University of Pennsylvania.

### **AMERICAN Text-Book of Legal Medicine and Toxicology.**

Edited by FREDERICK PETERSON, M.D., Chief of Clinic, Nervous Department, College of Physicians and Surgeons, New York City; and WALTER S. HAINES, M.D., Professor of Chemistry, Pharmacy, and Toxicology, Rush Medical College, Chicago.

### **BECK—Fractures.**

By CARL BECK, M.D., Professor of Surgery in the N. Y. School of Clinical Medicine.

### **BÖHM, DAVIDOFF, and HU- BER—A Text-Book of Human Histology.**

Including Microscopic Technic. By DR. A. A. BOHM and DR. M. VON DAVIDOFF, of the Anatomical Institute of Munich, and G. C. HUBER, M.D., Junior Professor of Anatomy and Histology, University of Michigan, Ann Arbor.

### **EICHHORST—A Text-Book of the Practice of Medicine.**

By DR. HERMAN EICHHORST, Professor of Special Pathology and Therapeutics and Director of the Medical Clinic, University of Zurich. Translated and edited by AUGUSTUS A. ESHNER, M.D., Professor of Clinical Medicine in the Philadelphia Polyclinic.

### **FRIEDRICH — Rhinology, La- ryngology, and Otology in their Relations to General Medicine.**

By DR. E. P. FRIEDRICH, of the University of Leipsig.

### **LEVY AND KLEMPERER — The Elements of Clinical Bac- teriology.**

By DR. ERNST LEVY, Professor in the University of Strassburg, and DR. FELIX KLEMPERER, Privat-Dozent in the University of Strassburg. Translated and edited by AUGUSTUS A. ESHNER, M.D., Professor of Clinical Medicine in the Philadelphia Polyclinic. *Just Ready.* Cloth, \$2 50 net.

### **McFARLAND—A Text-Book of Pathology.**

By JOSEPH McFARLAND, M.D., Professor of Pathology and Bacteriology, Medico-Chirurgical College, Philadelphia.

### **OGDEN — Clinical Examination of the Urine.**

By J. BERGEN OGDEN, M.D., Assistant in Chemistry, Harvard Medical School.

### **PYLE—A Manual of Personal Hygiene.**

Edited by WALTER L. PYLE, M.D., Assistant Surgeon to Wills' Eye Hospital, Philad.

### **SCUDDER—The Treatment o Fractures.**

By CHARLES L. SCUDDER, M.D., Assistant in Clinical and Operative Surgery, Harvard University.

### **SENN—Practical Surgery.**

By NICHOLAS SENN, M.D., PH.D., LL.D. Professor of the Practice of Surgery and Clinical Surgery, Rush Medical College, Chicago. Octavo volume of about 800 pages profusely illustrated.

### **The Pathology and Treatment of Tumors.**

By NICHOLAS SENN, M.D., PH.D., LL.D., Professor of the Practice of Surgery and of Clinical Surgery, Rush Medical College, Chicago. A New and Thoroughly Revised Edition in preparation.

### **STENGEL AND WHITE — The Blood in its Clinical and Patho- logical Relations.**


By ALFRED STENGEL, M.D., Professor Clinical Medicine, University of Pennsylvania; and C. Y. WHITE, M.D., Instructor in Clinical Medicine, University of Pennsylvania.

### **STEVENS—The Physical Dia- gnosis of Diseases of the Ches**


By A. A. STEVENS, A.M., M.D., Lecturer on Terminology, and Instructor in Physical Diagnosis, University of Pennsylvania.

### **STONEV — Surgical Technique for Nurses.**

By EMILY A. M. STONEV, late Superintendent of the Training Schools for Nurses, Carney Hospital, South Boston, Mass.




















LIBRARY OF CONGRESS



0 021 062 803 4